MEDIZINISCHE UNIVERSITÄT INNSBRUCK

Anatomische Variationen des N. laryngeus recurrens

Marko Konschake

Disclosure

MEDIZINISCHE UNIVERSITÄT INNSBRUCK

X	No, nothing to disclose
	Yes, please specify:

Company Name	*Honoraria/ Expenses*	*Consulting/ Advisory Board*	*Funded Research*	*Royalties/ Patent*	*Stock Options*	*Ownership/ Equity Position*	*Employee*	*Other (please specify)*
Example: company XYZ	x		x		x			

© http://www.jugendfotofestival.de/pics/ich/18_senn_michelle_hals_ueber_kopf.jpg

MEDIZINISCHE UNIVERSITÄT INNSBRUCK

„3“ Halsfaszien:

- Lamina superficialis
- Lamina praetrachealis
- Lamina paraevertebralis

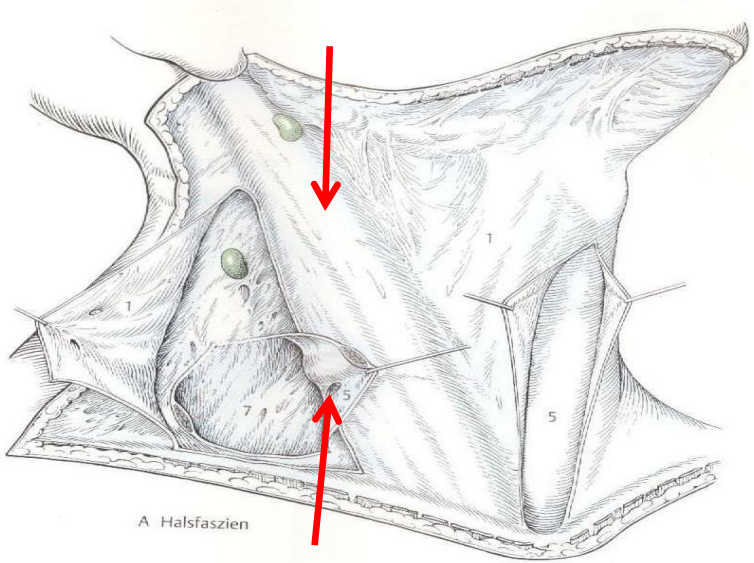

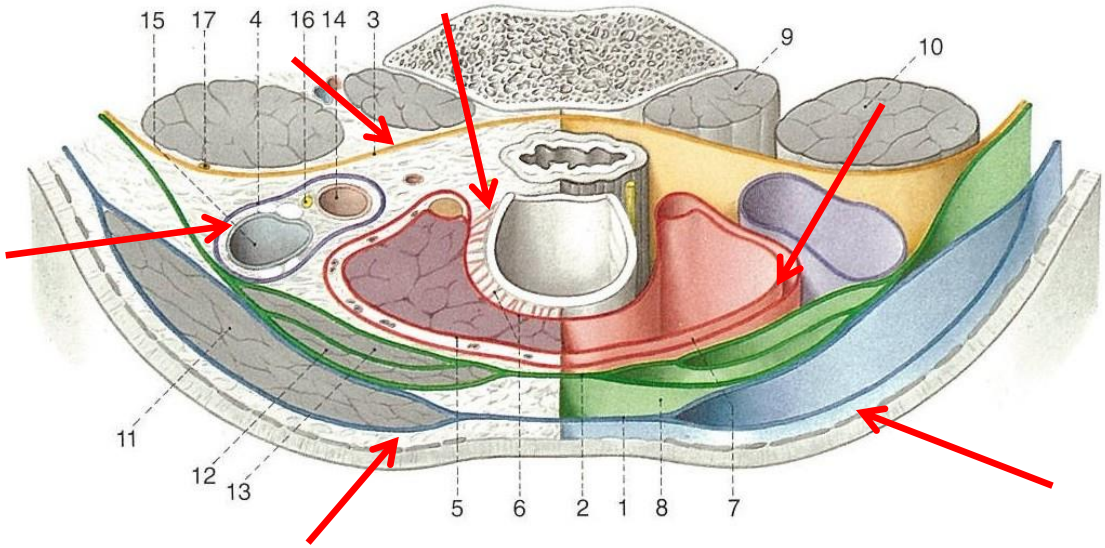

„Schichtengliederung“
und „Spatium viscerale colli“ !!

MEDIZINISCHE UNIVERSITÄT
INNSBRUCK

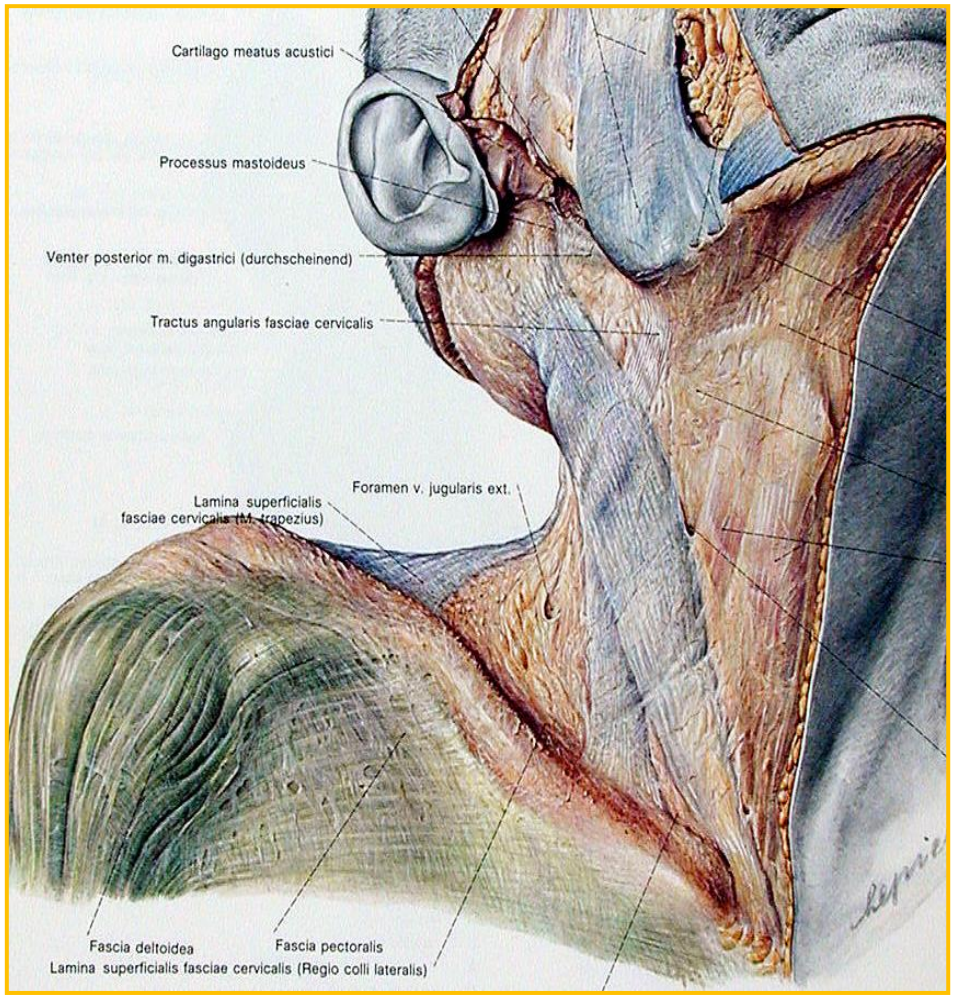

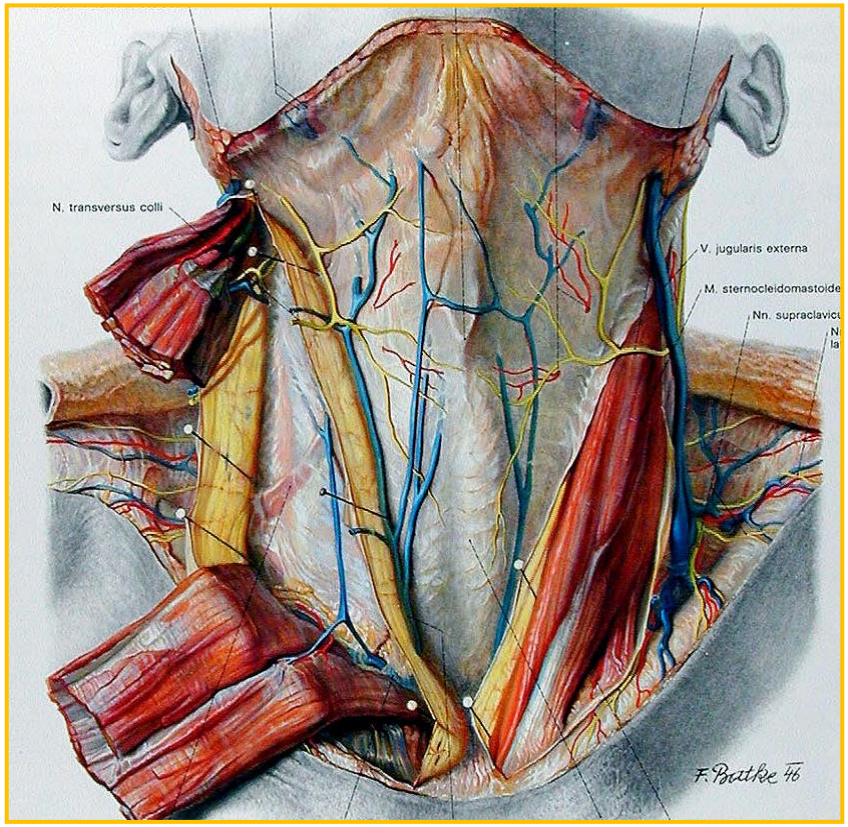

Regio mediana cervicalis I

MEDIZINISCHE UNIVERSITÄT INNSBRUCK

Spatium interfasziale

„Arcus venosus jugularis“
→ „Arcus venosus subhyoideus“

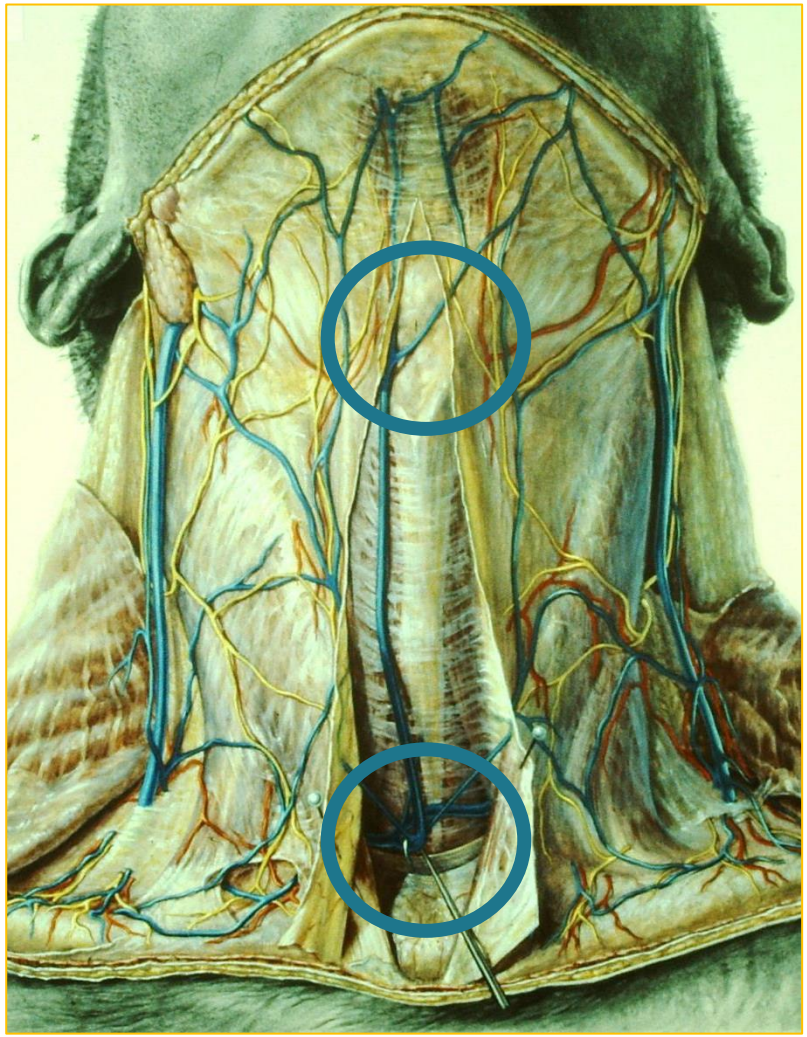

Regio mediana cervicalis II

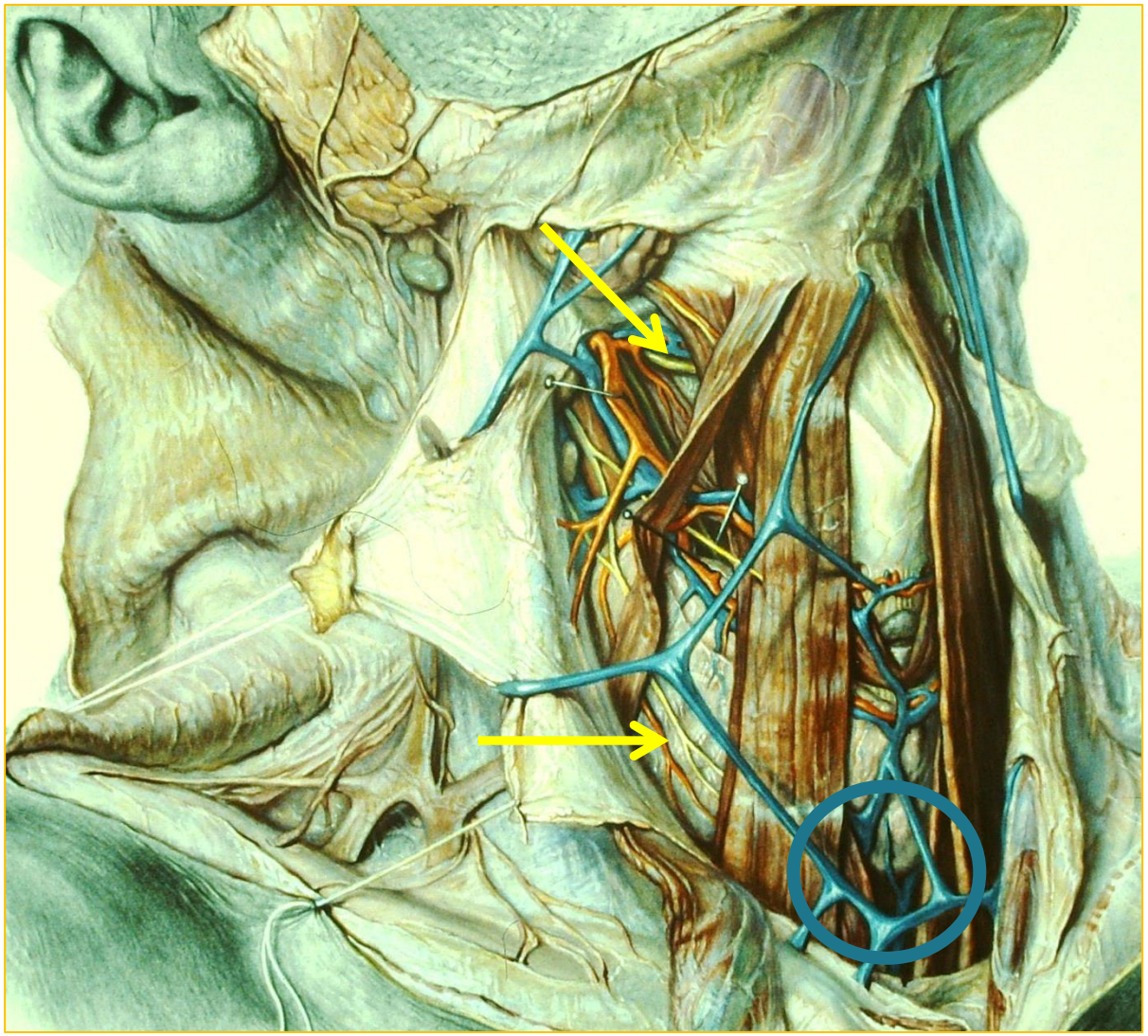

MEDIZINISCHE UNIVERSITÄT INNSBRUCK

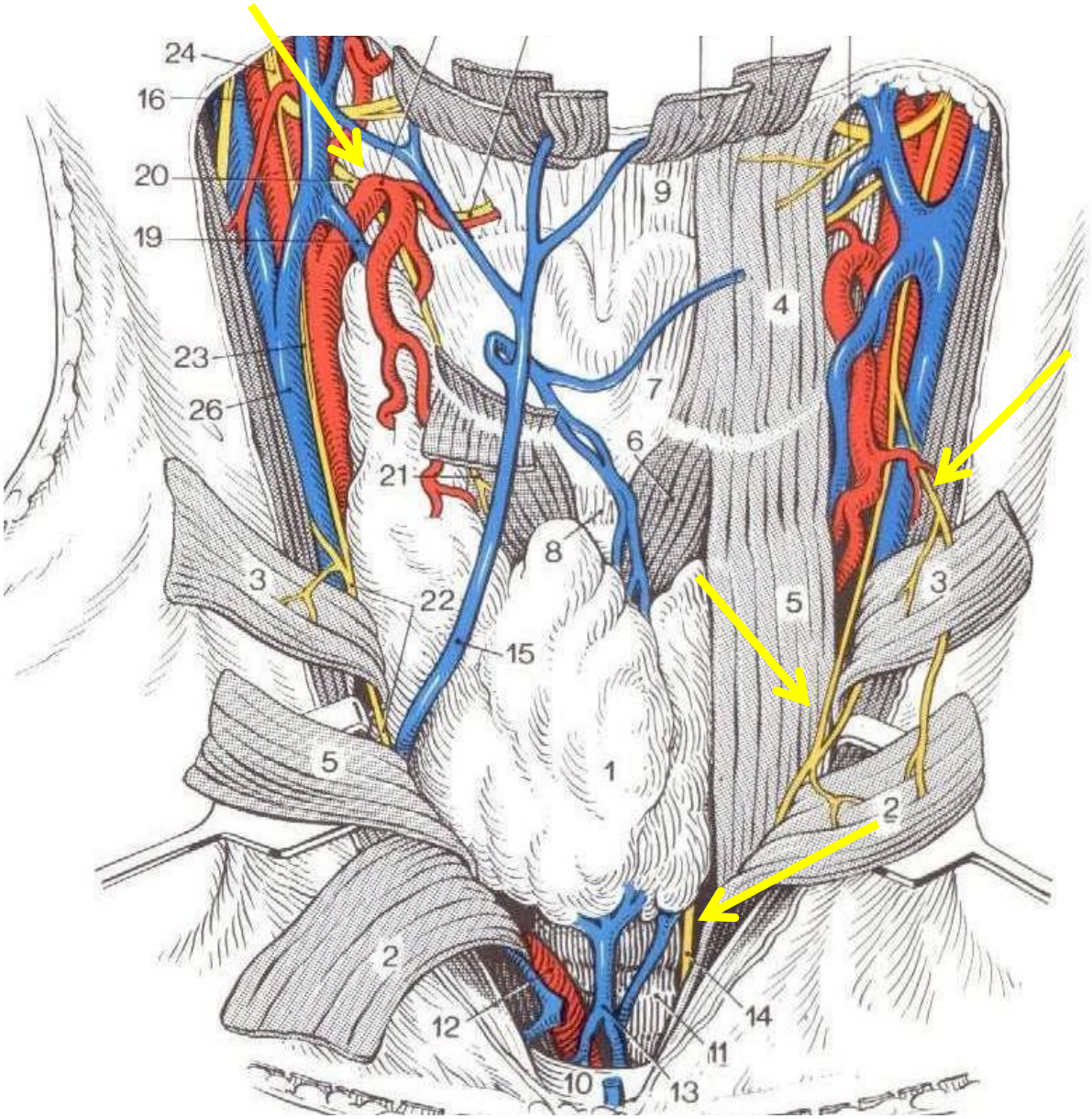

MEDIZINISCHE UNIVERSITÄT INNSBRUCK

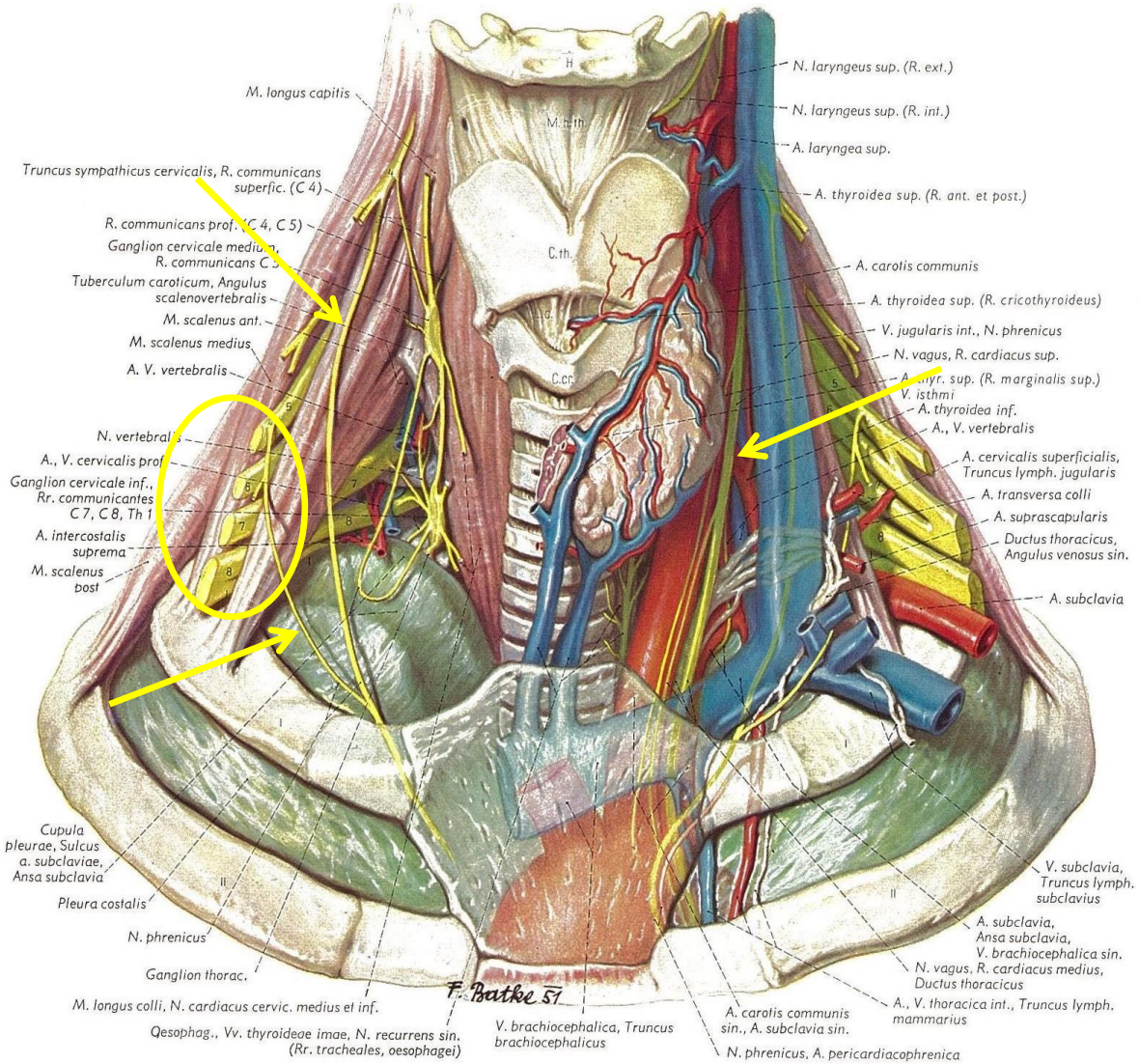

C.cr = Cartilago cricoidea
C.th = Cartilago thyroidea
L.c = Lig. conicum

M.h.th = Membrana thyrohyoidea
I.,II. = 1. und 2. Rippe

4–8 = R ventr. des 4. bis 8. Halsnerven
I = R ventr. des 1. Brustnerven

MEDIZINISCHE UNIVERSITÄT INNSBRUCK



MEDIZINISCHE UNIVERSITÄT INNSBRUCK

Lagevarianten des N. vagus

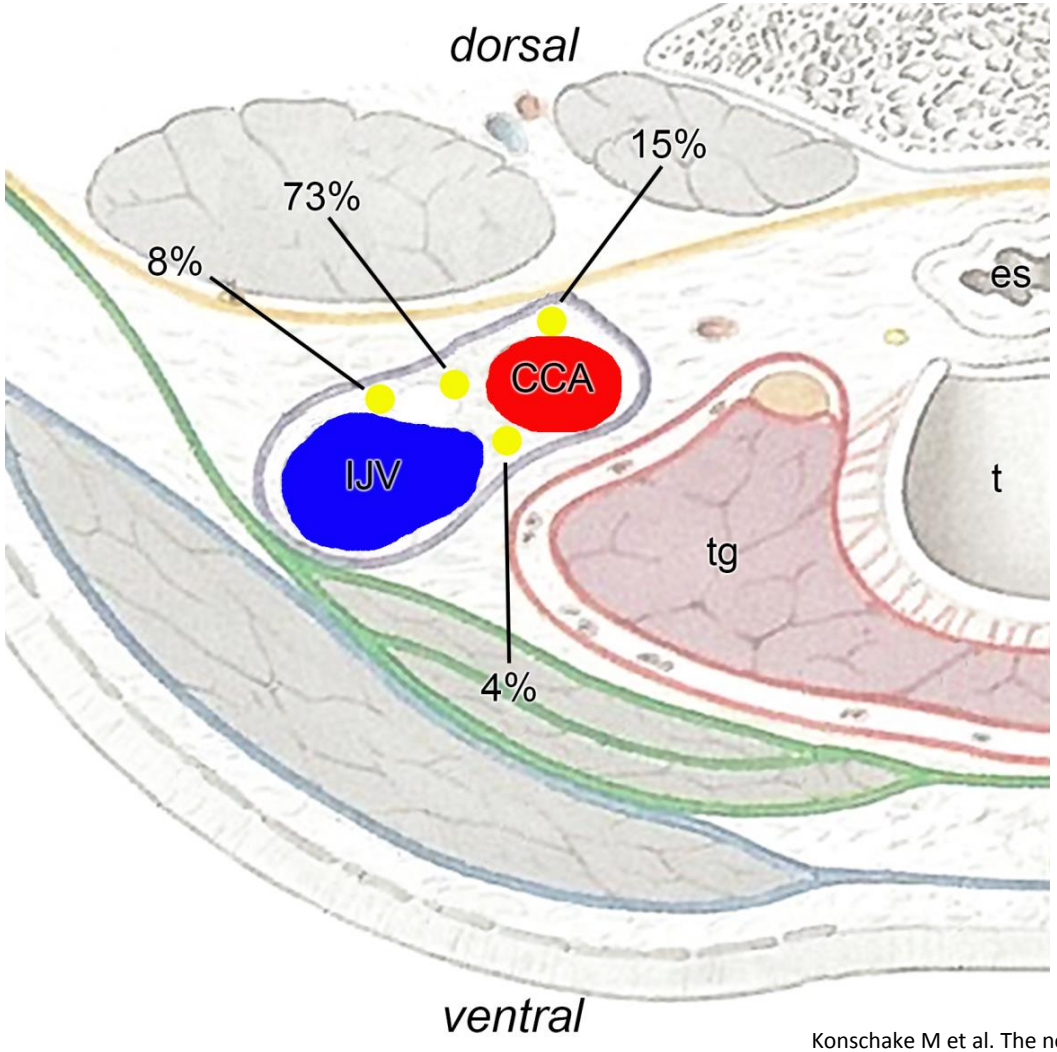

Konschake M et al. The nonrecurrent laryngeal nerve: A clinical anatomic mapping with regard to intraoperative neuromonitoring. Surgery 2016.

Äste des N. vagus

- N. laryngeus superior

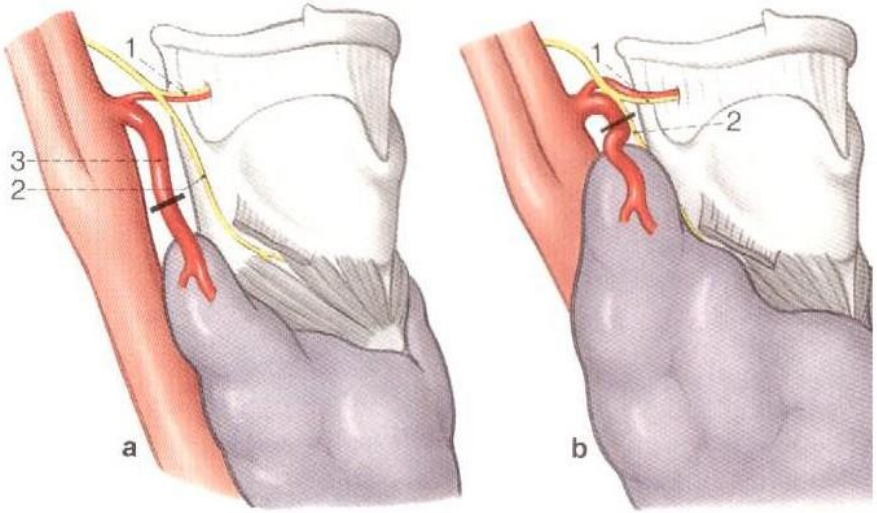

1 Ramus externus ***(„The neglected nerve“)***
2 Ramus internus
3 A. thyroidea sup.

- N. laryngeus „recurrens“/inferior

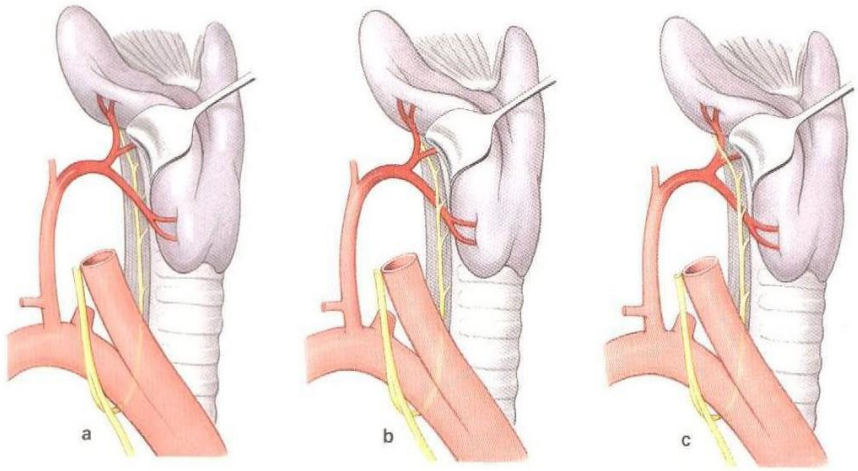

Abb. **11a–c** Verlaufsvarianten des N. laryngeus recurrens.

a Der Nerv liegt dorsal von den Arterienästen.
b Der Nerv durchsetzt die Arterienäste.
c Der Nerv liegt ventral von den Arterienästen.

N. laryngeus recurrens dexter

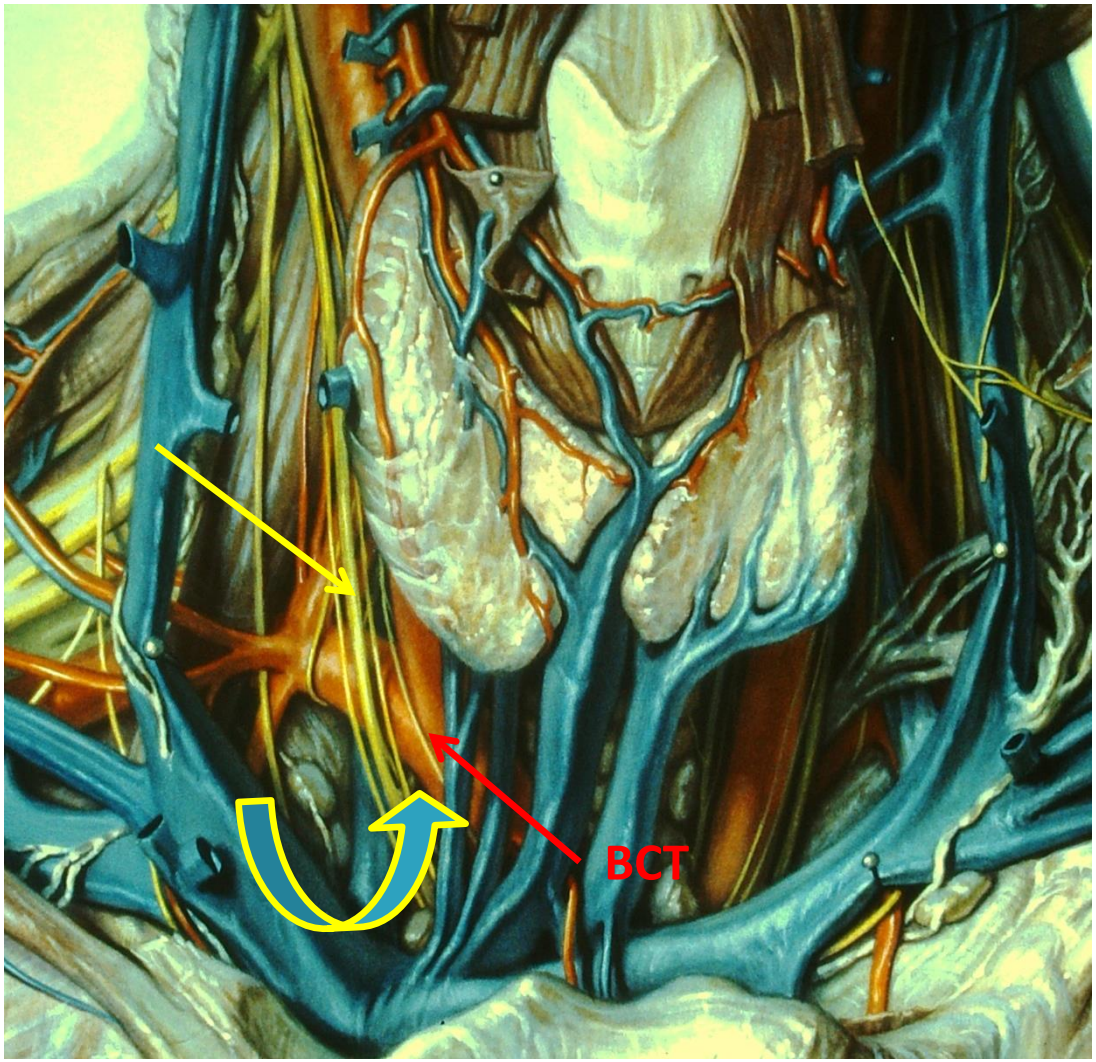

N. laryngeus recurrens sinister

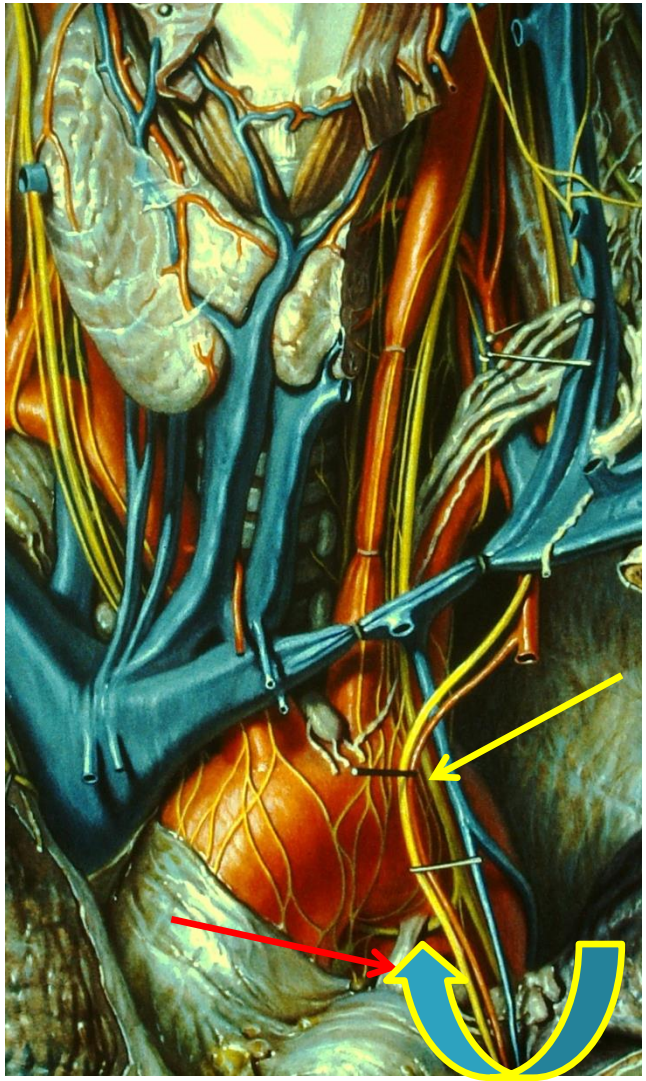

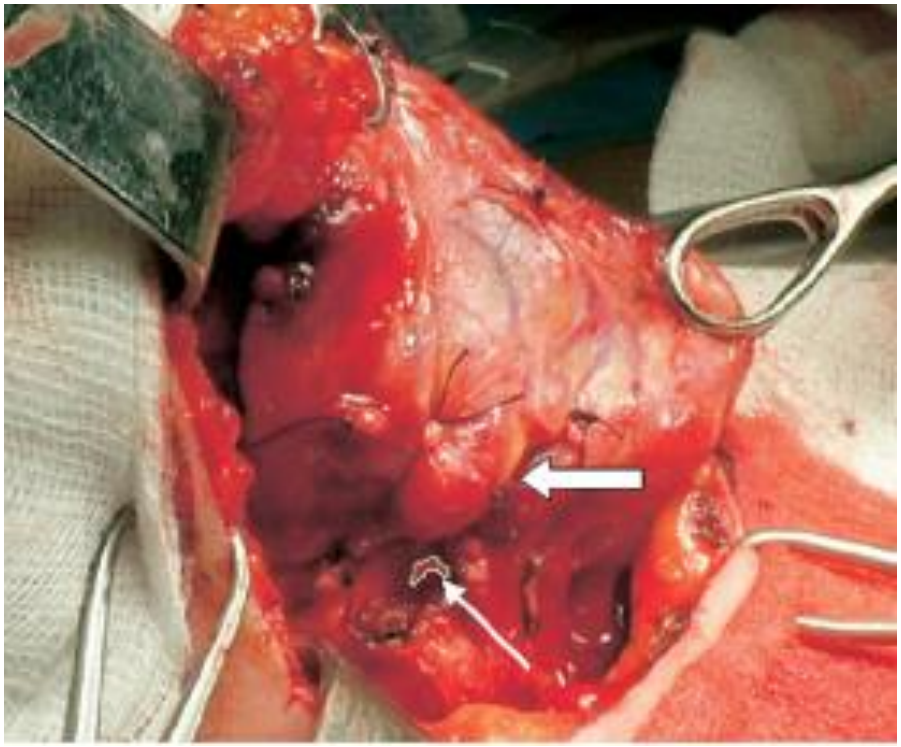

MEDIZINISCHE UNIVERSITÄT INNSBRUCK

63-80% der Patienten

Grad 1	<0,5cm
Grad 2	0,5-1cm
Grad 3	>1cm

Das **Tuberculum Zuckerkandl** ist ein Wegweiser zum **Nervus laryngeus recurrens !**

in **93%** der Fälle **medial** vom Tuberculum und in nur **7%** der Fälle **lateral !**

Konschake M et al. The nonrecurrent laryngeal nerve: A clinical anatomic mapping with regard to intraoperative neuromonitoring. Surgery 2016.

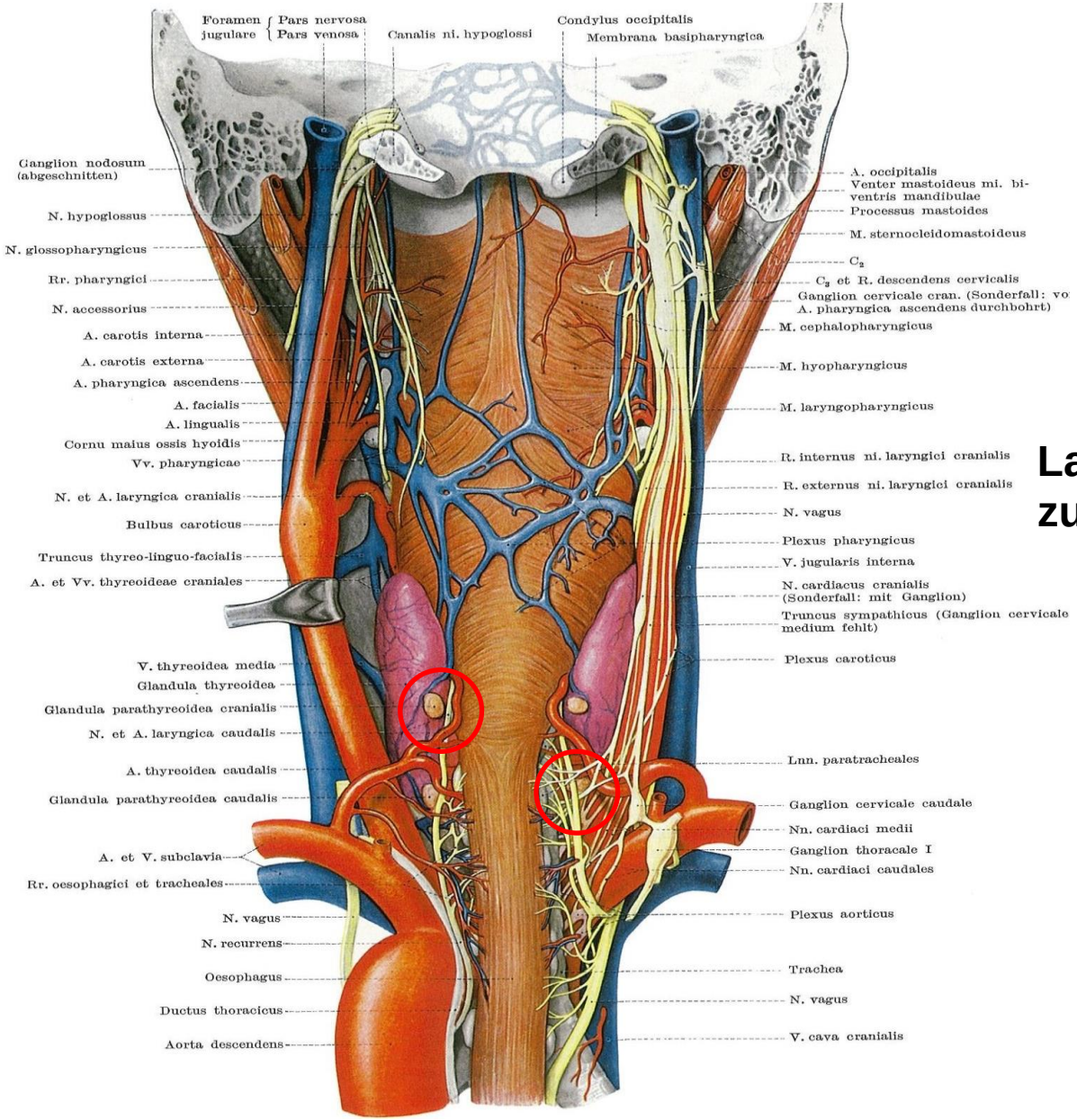

MEDIZINISCHE UNIVERSITÄT INNSBRUCK

Lage der Epithelkörperchen zum RLN !

Entwicklung - Epithelkörperchen

MEDIZINISCHE UNIVERSITÄT INNSBRUCK

„Descensus“ der Neben-Schilddrüsen !

„Streuungsbreite“ - Epithelkörperchen

MEDIZINISCHE UNIVERSITÄT INNSBRUCK

a) Bei normal großen Schilddrüsen.

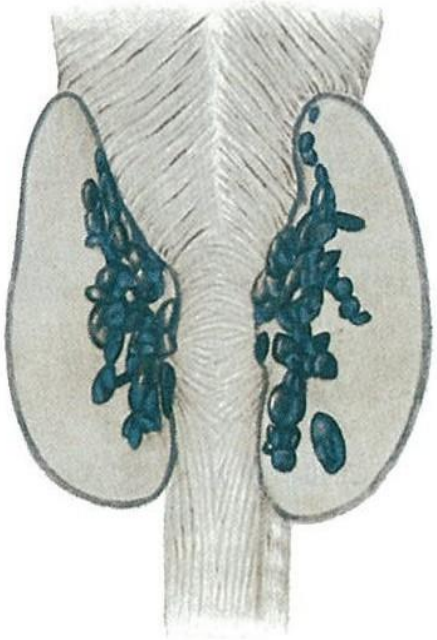

b) Bei kropfig vergrößerten Schilddrüsen.

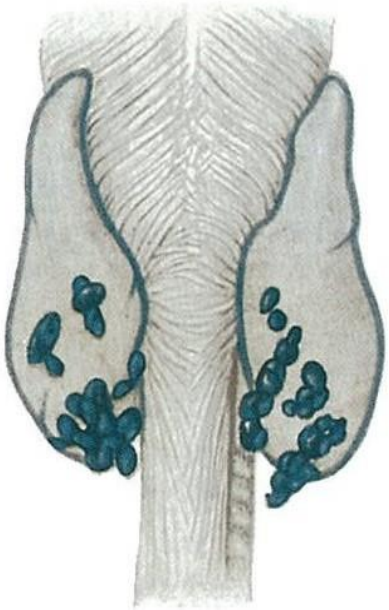

a) Bei normal großen Schilddrüsen.

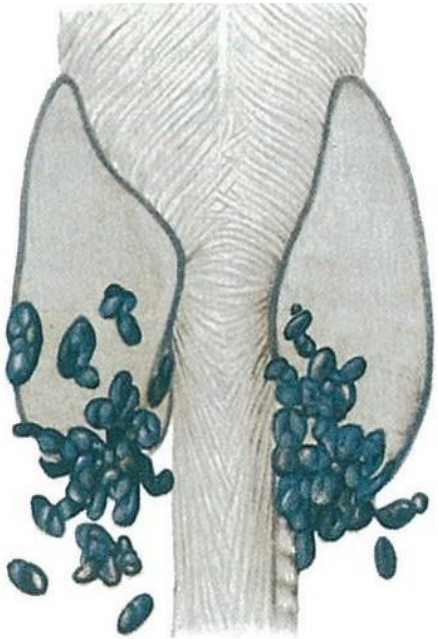

b) Bei kropfig vergrößerten Schilddrüsen.

N. laryngeus inferior non recurrens – deszendierend

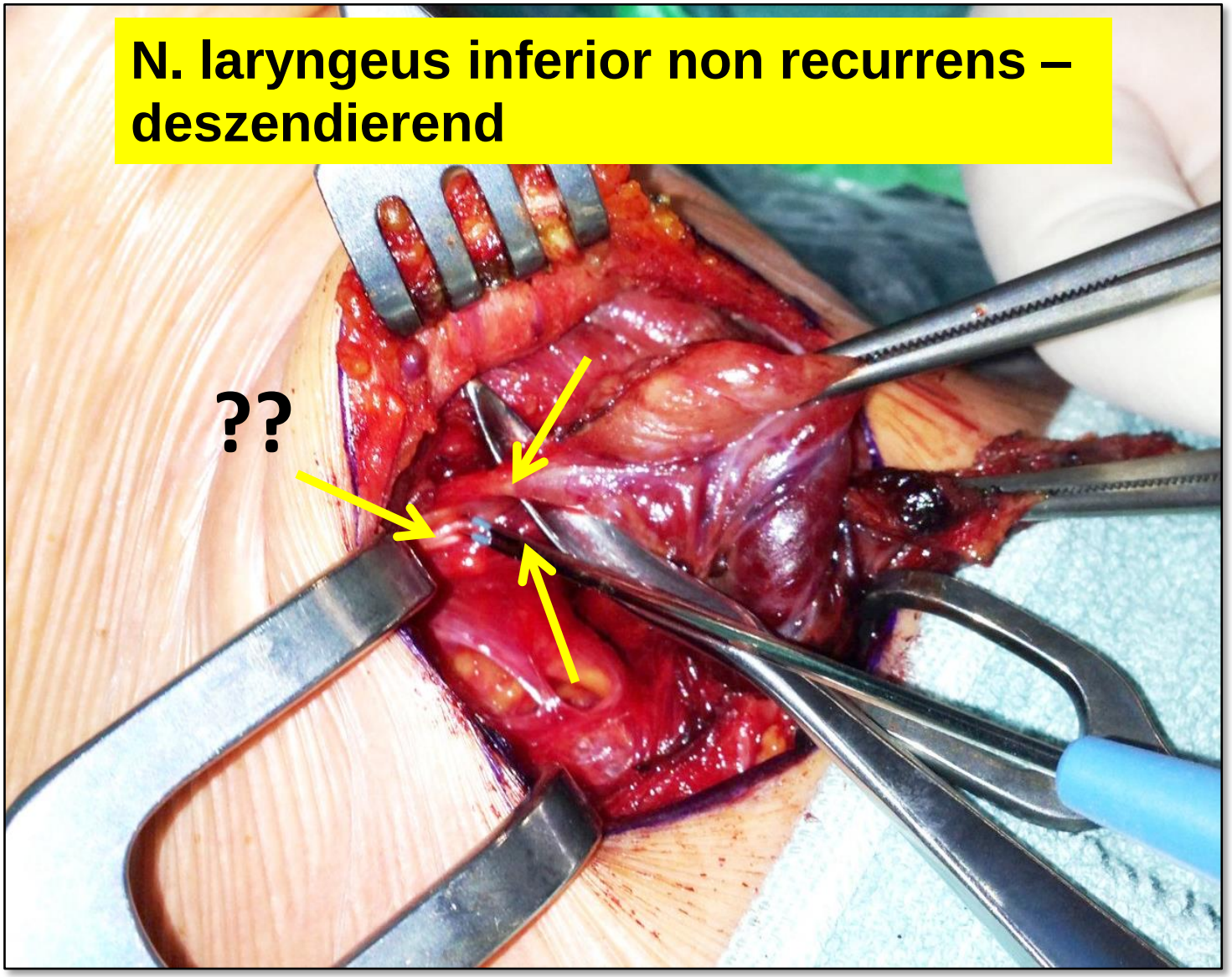

MEDIZINISCHE UNIVERSITÄT INNSBRUCK

Konschake M et al. The nonrecurrent laryngeal nerve: A clinical anatomic mapping with regard to intraoperative neuromonitoring. Surgery 2016.

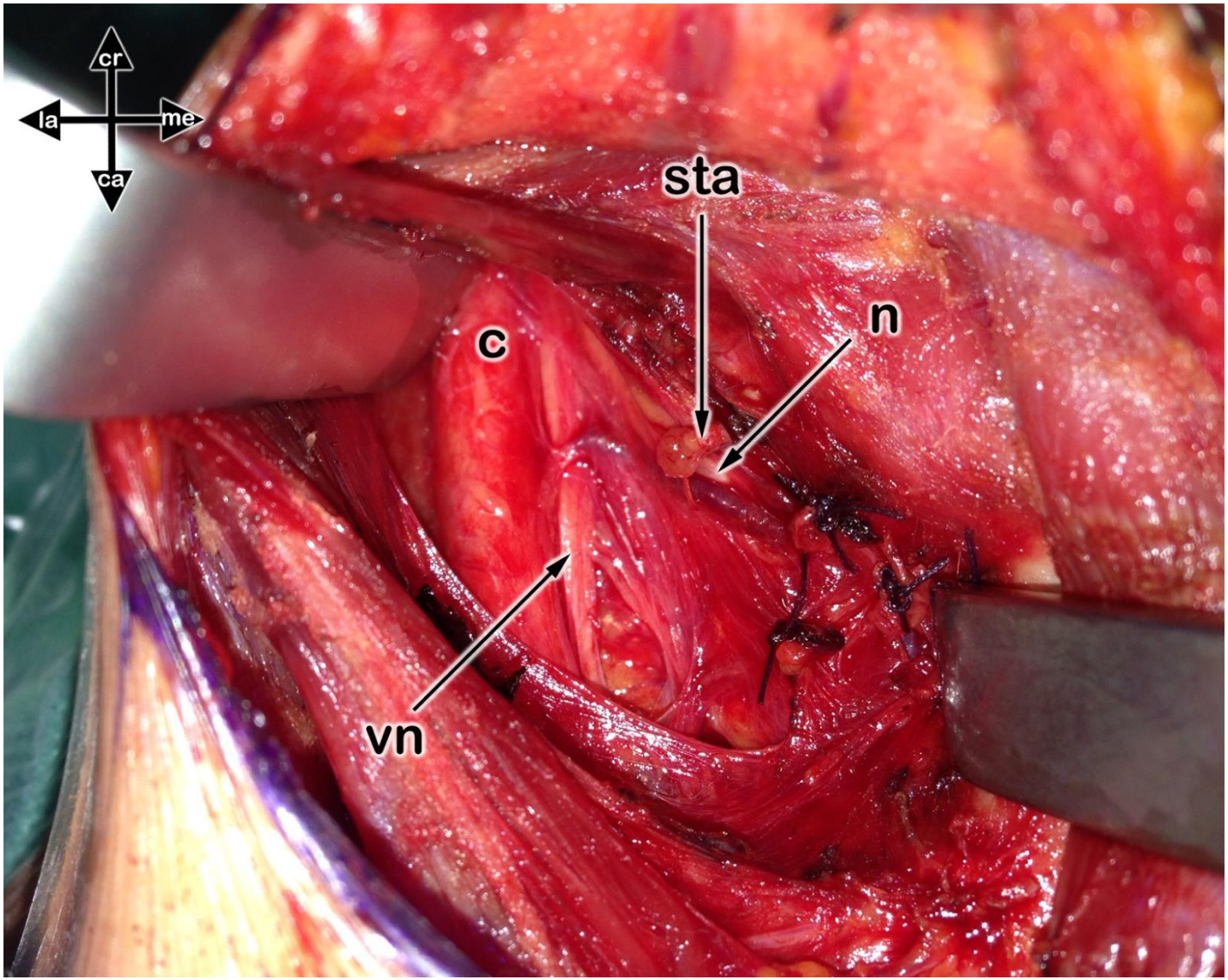

MEDIZINISCHE UNIVERSITÄT INNSBRUCK

Konschake M et al. The nonrecurrent laryngeal nerve: A clinical anatomic mapping with regard to intraoperative neuromonitoring. Surgery 2016.

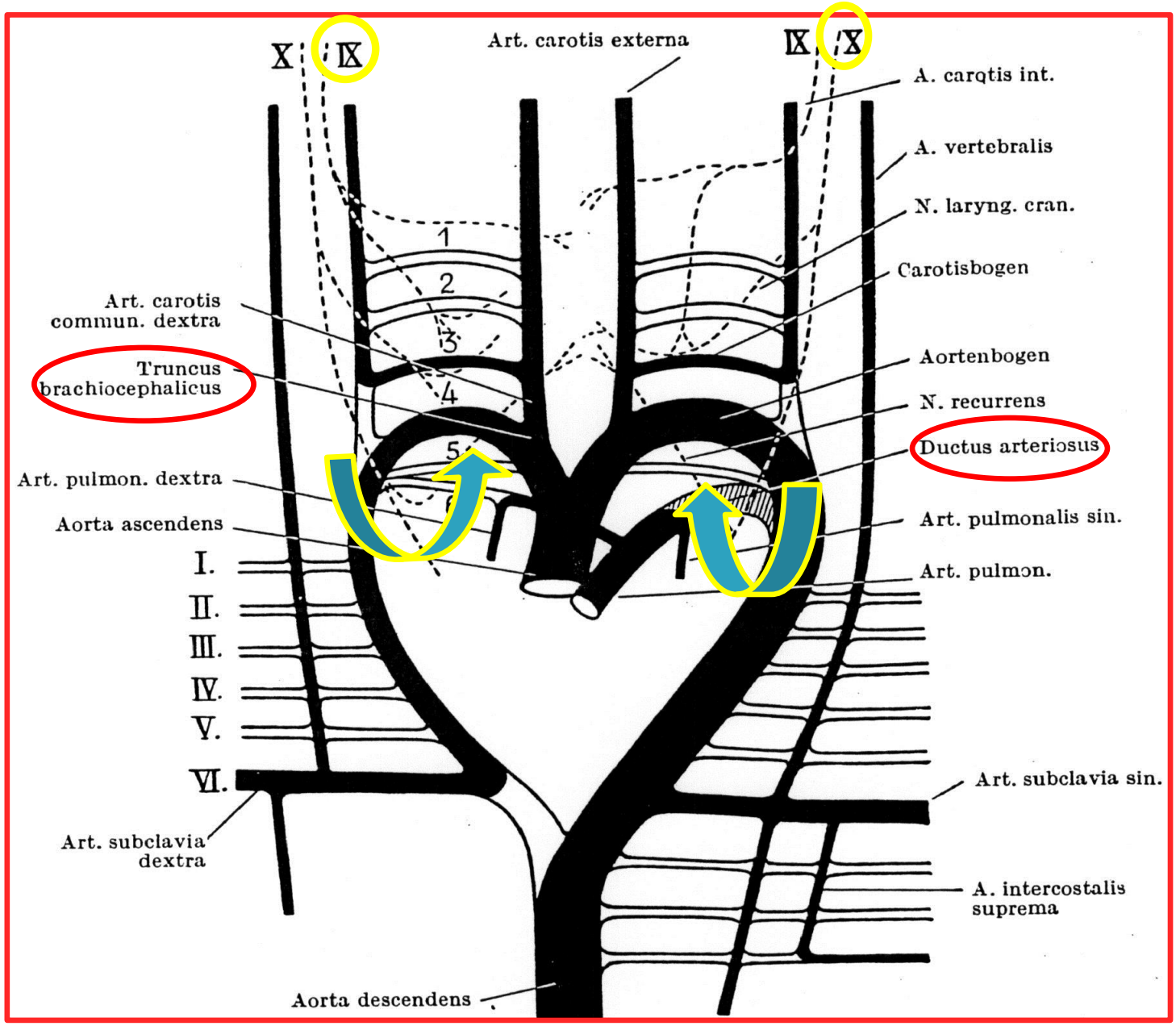

MEDIZINISCHE UNIVERSITÄT INNSBRUCK

N. laryngeus inferior non recurrens – aszendierend

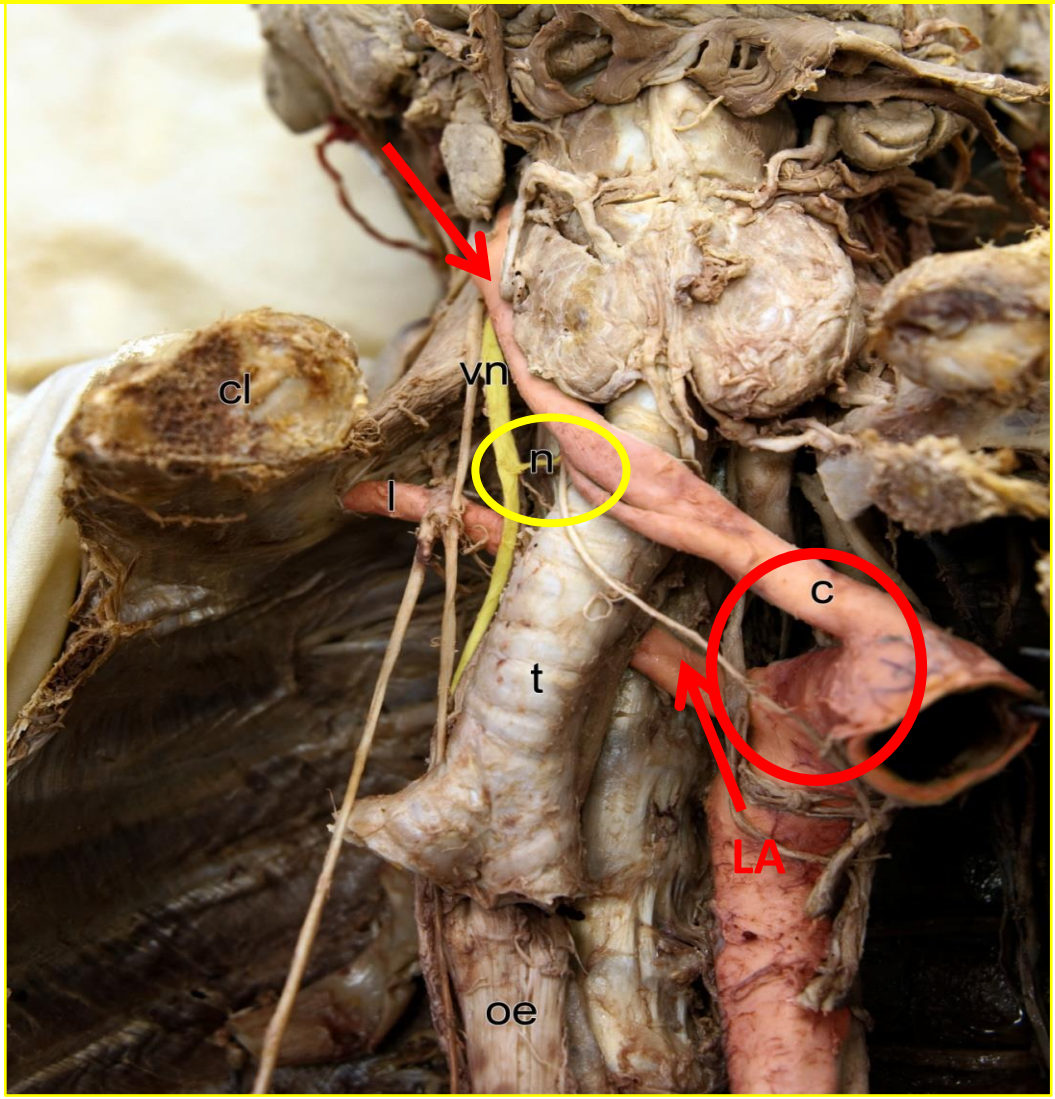

MEDIZINISCHE UNIVERSITÄT INNSBRUCK

Konschake M et al. The nonrecurrent laryngeal nerve: A clinical anatomic mapping with regard to intraoperative neuromonitoring. Surgery 2016.

N. laryngeus inferior non recurrens – horizontal

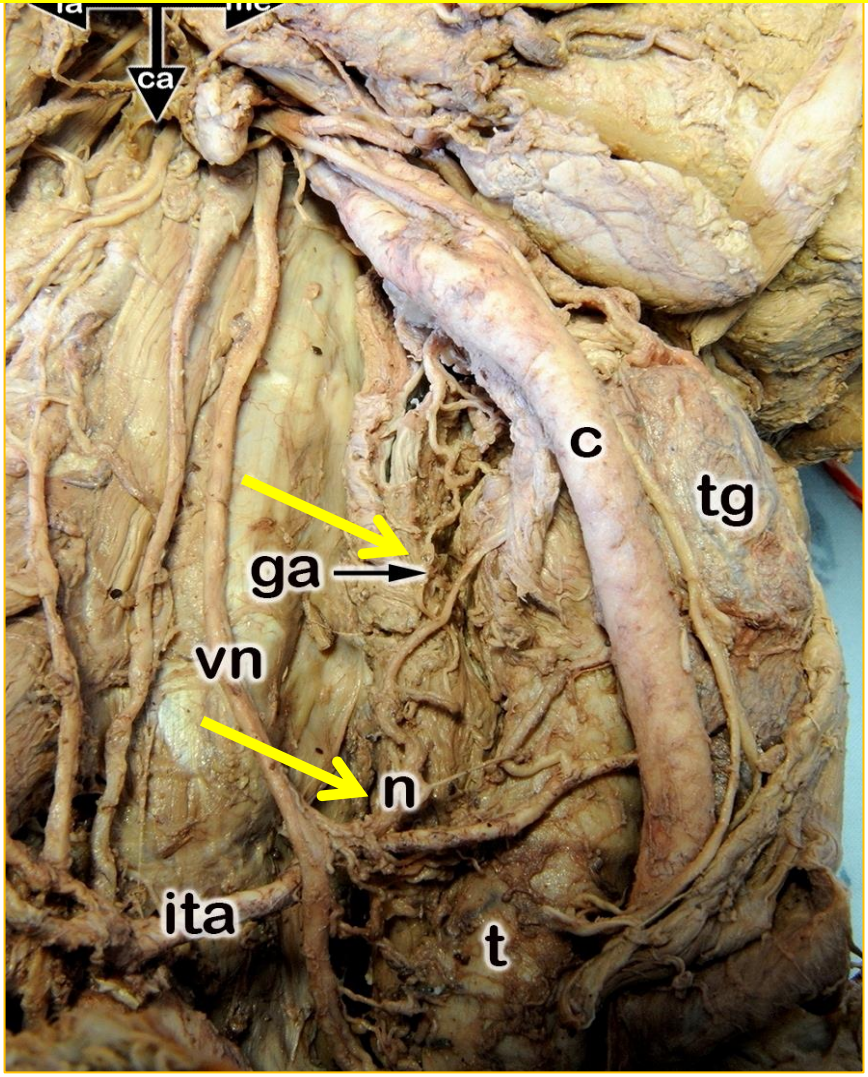

Konschake M et al. The nonrecurrent laryngeal nerve: A clinical anatomic mapping with regard to intraoperative neuromonitoring. Surgery 2016.

N. laryngeus inferior non recurrens

MEDIZINISCHE UNIVERSITÄT INNSBRUCK

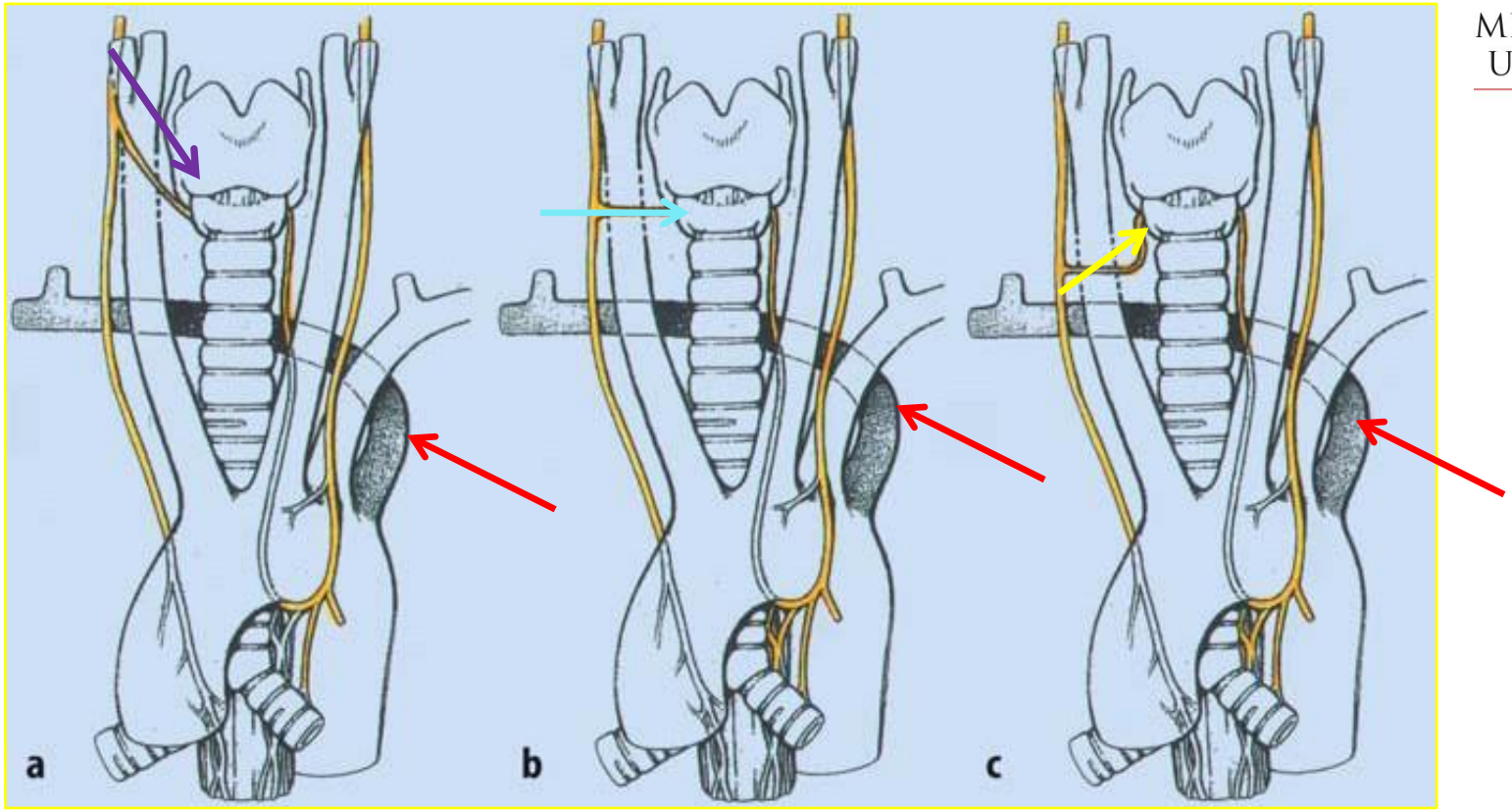

N. laryngeus inferior divisus

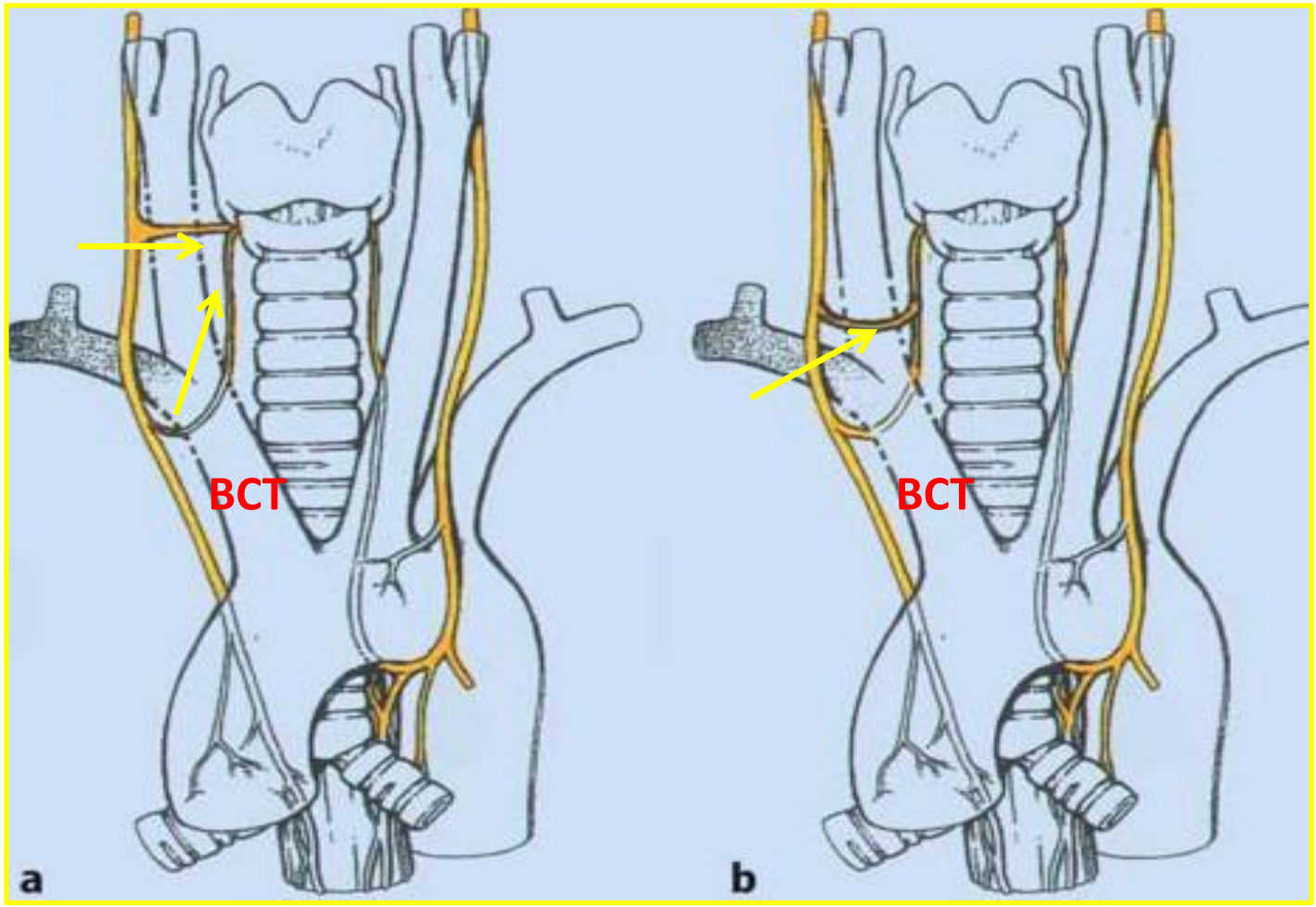

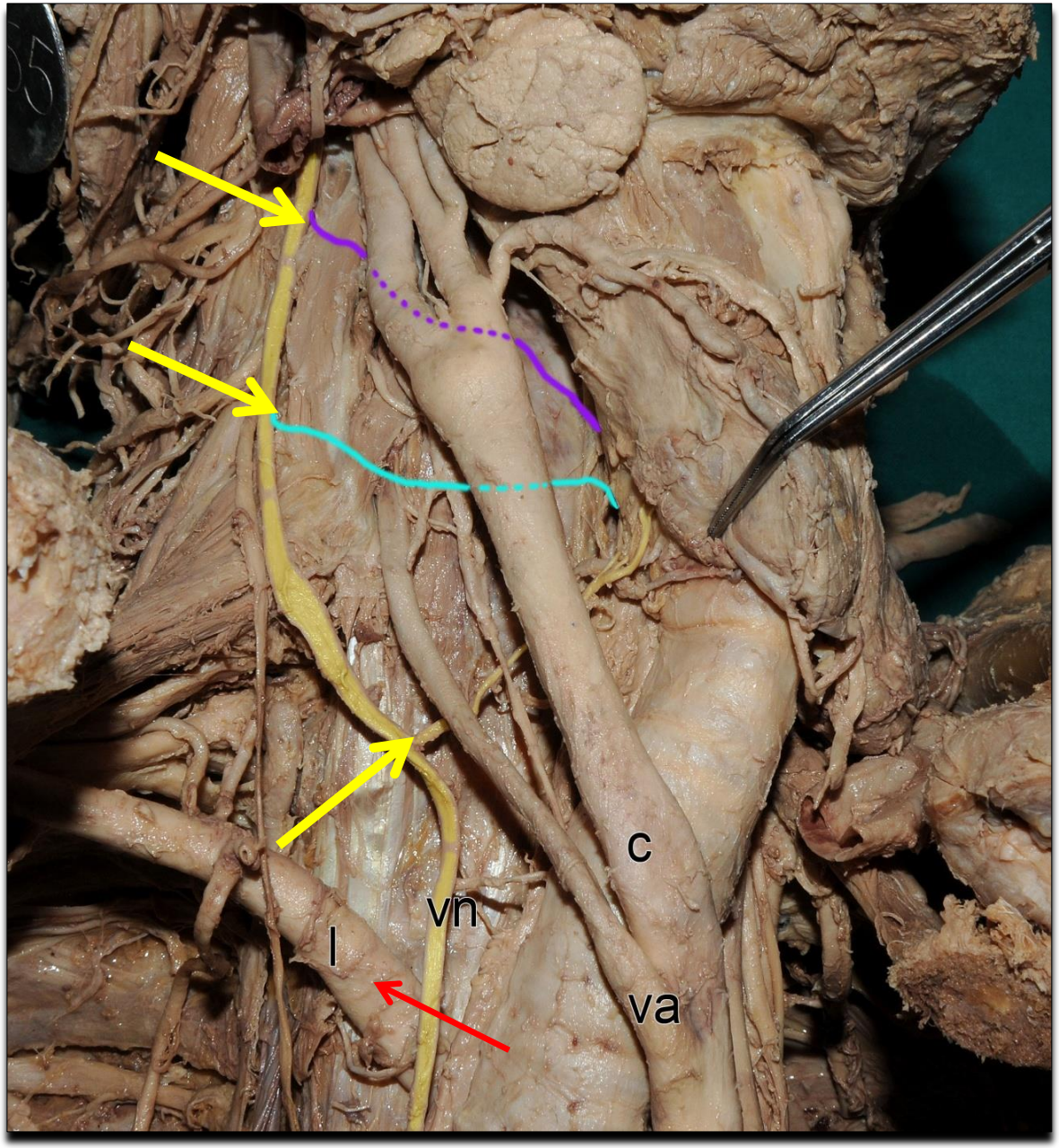

MEDIZINISCHE UNIVERSITÄT INNSBRUCK

Konschake M et al. The nonrecurrent laryngeal nerve: A clinical anatomic mapping with regard to intraoperative neuromonitoring. Surgery 2016.

Präoperativer Ultraschall des BCT !!

MEDIZINISCHE UNIVERSITÄT INNSBRUCK

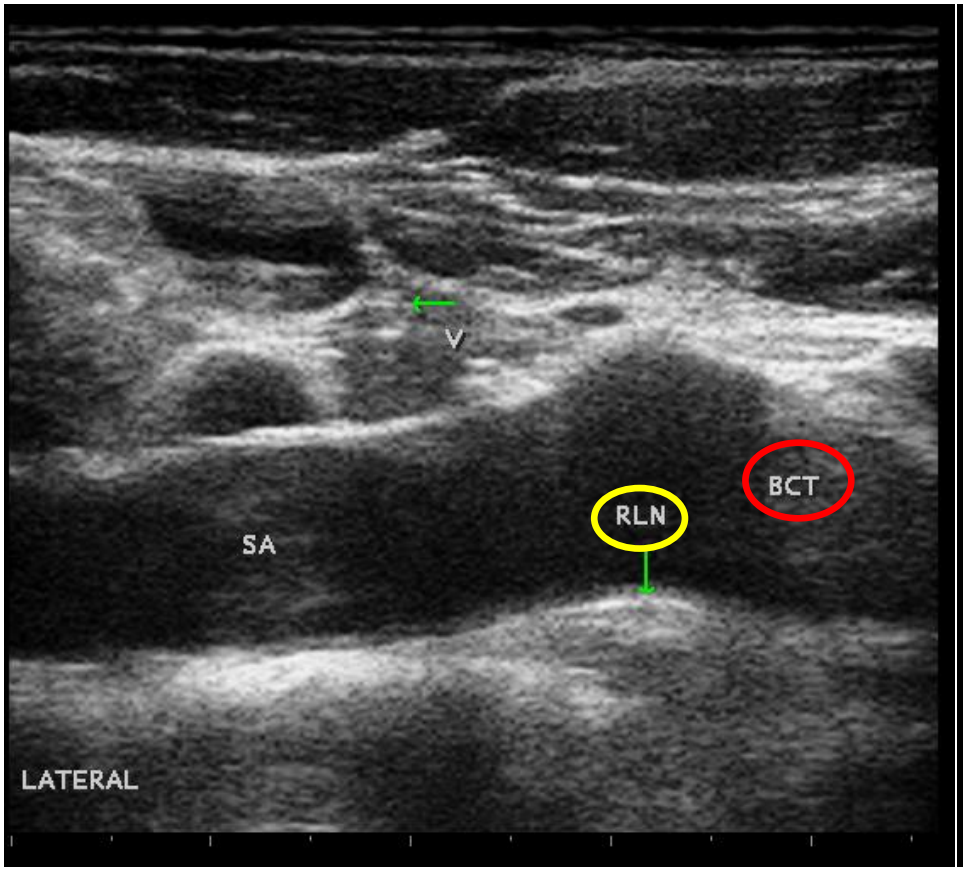

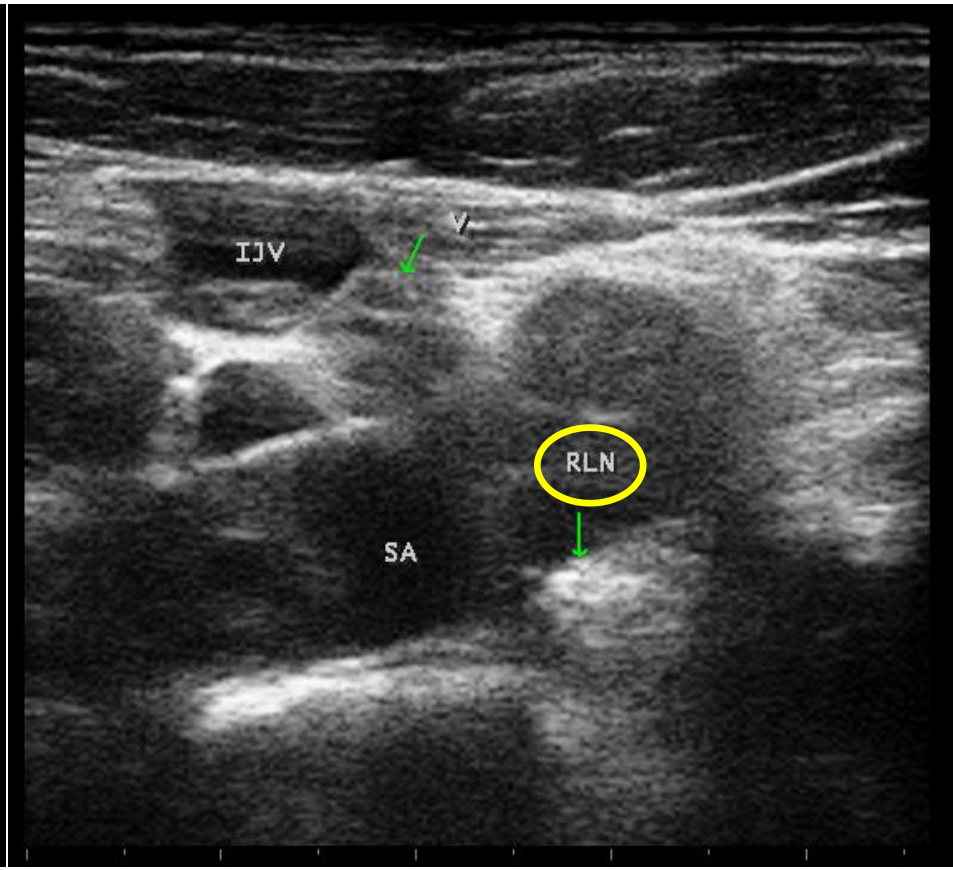

Konschake M et al. The nonrecurrent laryngeal nerve: A clinical anatomic mapping with regard to intraoperative neuromonitoring. Surgery 2016.

Extralaryngeale Divisionen

MEDIZINISCHE UNIVERSITÄT INNSBRUCK

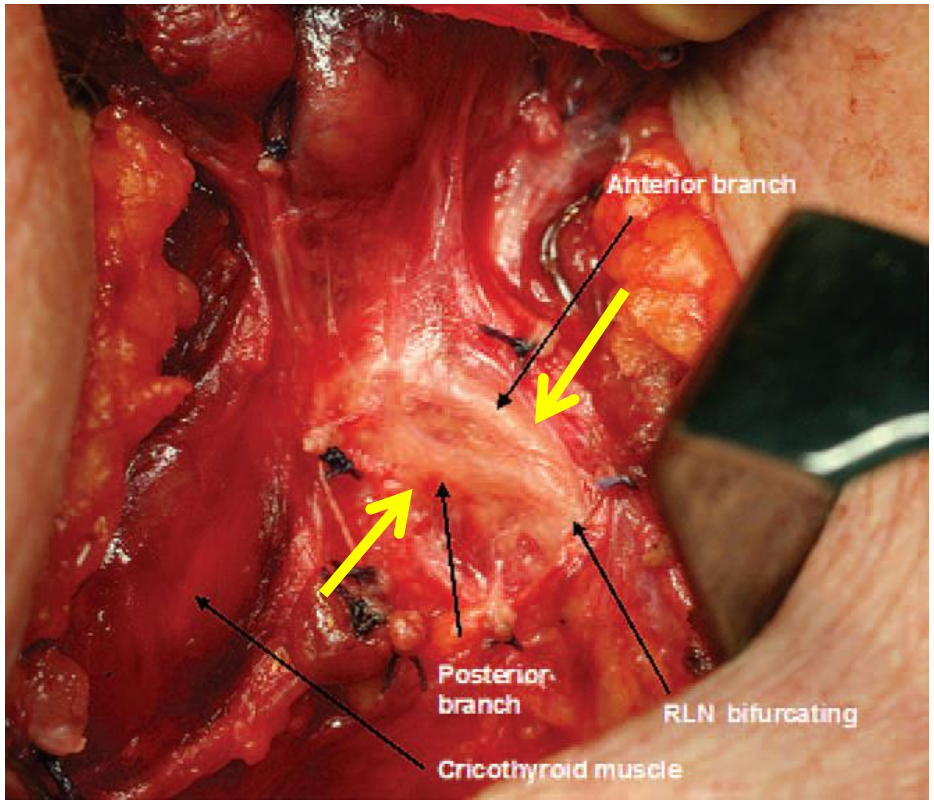

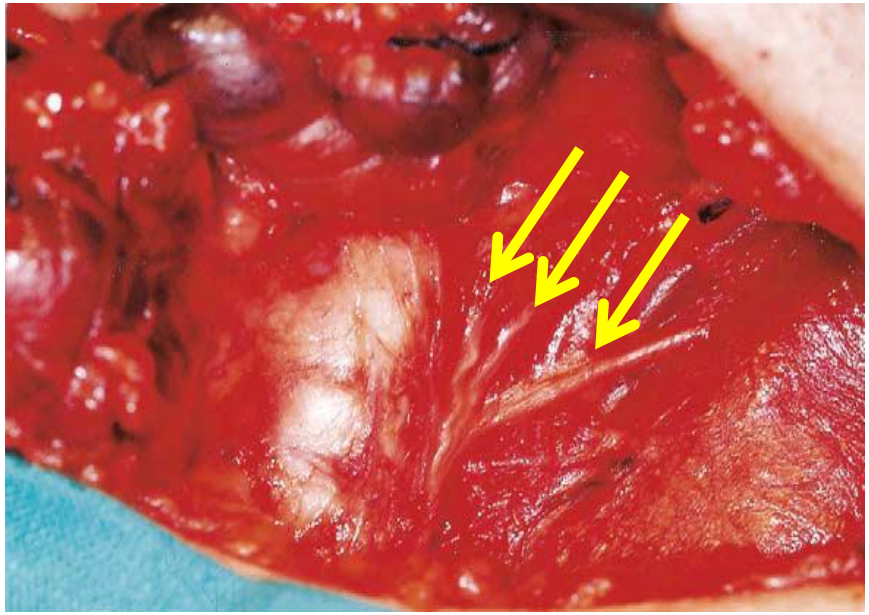

Beneragama, T. and Serpell, J. W. (2006), EXTRALARYNGEAL BIFURCATION OF THE RECURRENT LARYNGEAL NERVE: A COMMON VARIATION. ANZ Journal of Surgery, 76: 928–931.

Ardito G, Revelli L, D'Alatri L, Lerro V, Guidi ML, Ardito F. Revisited anatomy of the recurrent laryngeal nerves. The American journal of surgery 2004; 187:249-253.

Verhaltensmuster und Prävalenzrate – Meta-Analyse

MEDIZINISCHE UNIVERSITÄT INNSBRUCK

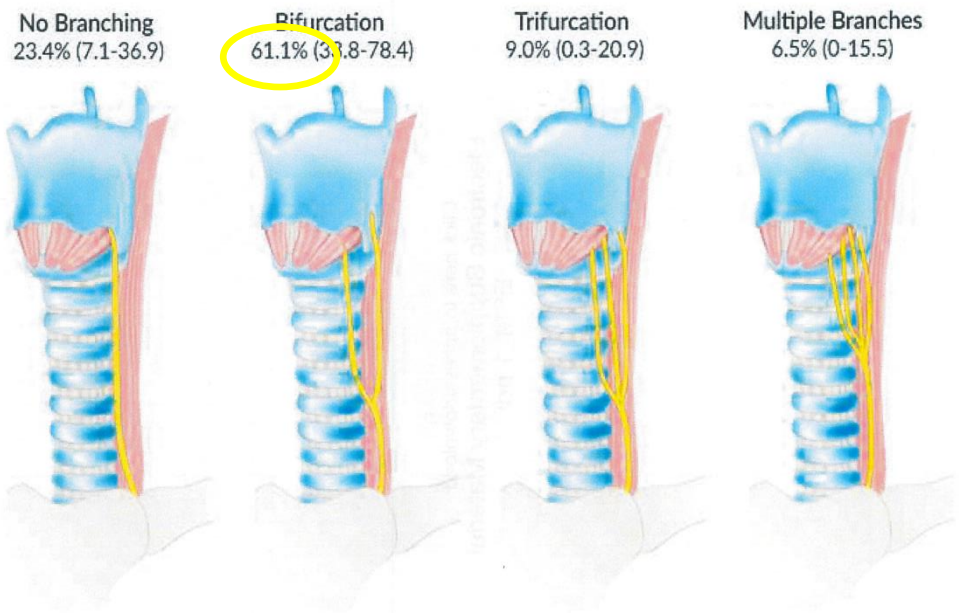

N=28.387

Anatomische + intraoperative (prospektive+retrospektive) Studien

Sir William Osler 1849

MEDIZINISCHE UNIVERSITÄT INNSBRUCK

William Osler



Variability is the law of life, and as no two faces are the same, so no two bodies are alike, and no two individuals react alike and behave alike under the abnormal conditions which we know as disease.

AZ QUOTES

Vielen Dank für die Aufmerksamkeit!

MEDIZINISCHE UNIVERSITÄT
INNSBRUCK