Landeskrankenhaus Graz Süd-West
Akademisches Lehrkrankenhaus der Medizinischen Universität Graz

Pathologie

Pathologie der Schilddrüse:

Was ist 2017 neu?

Sigurd Lax

Institut für Pathologie
LKH Graz Süd-West, Standort West

sigurd.lax@kages.at oder sigurd.lax@medunigraz.at

Neue Klassifikationen



4th ed. 2016

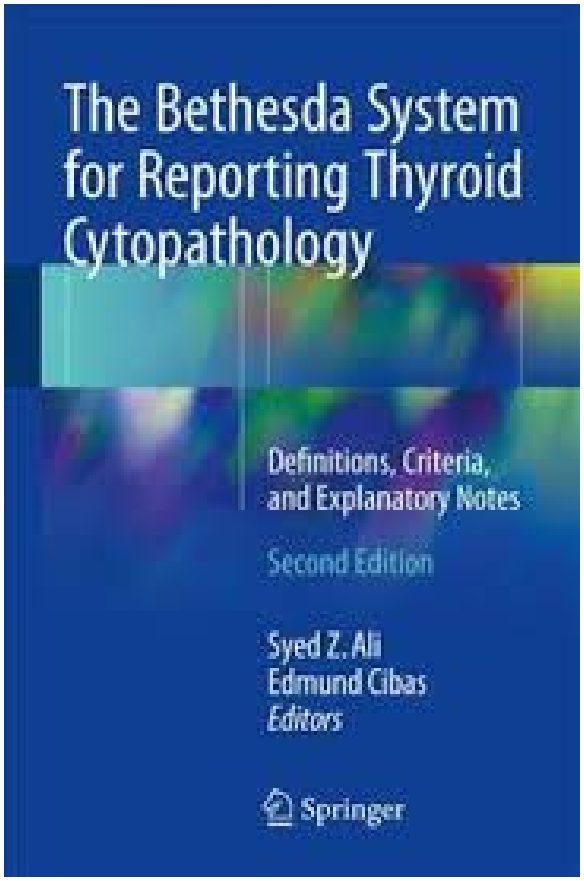

2nd ed. 2017



8th ed. 2017

WHO 2016: Schilddrüsentumoren

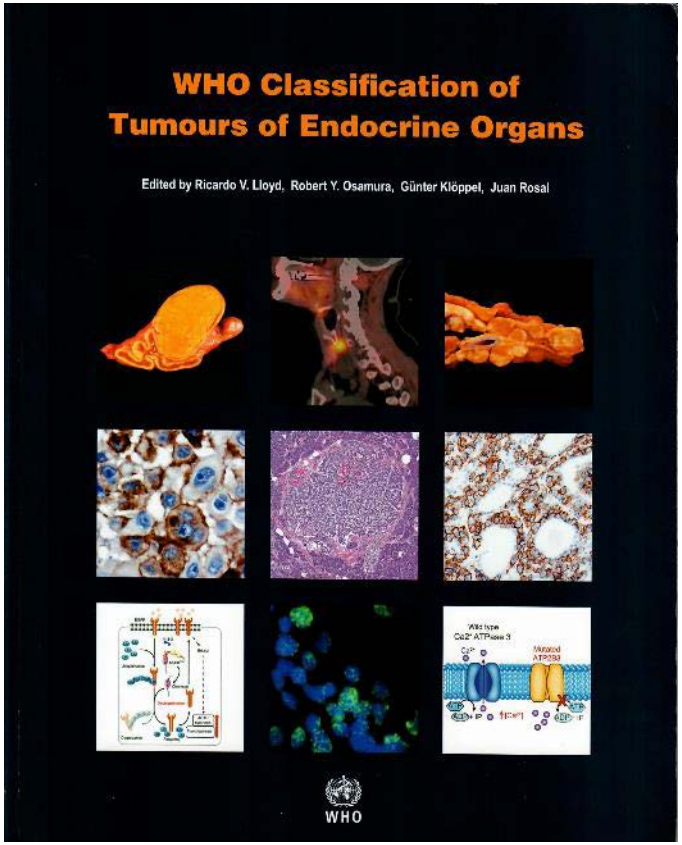

P. Komminoth, Zürich

K. Kaserer, Wien

S.F. Lax, Graz

A.Perren, Bern

K.W. Schmid, Essen

WHO 2016: Schilddrüsenkarzinome

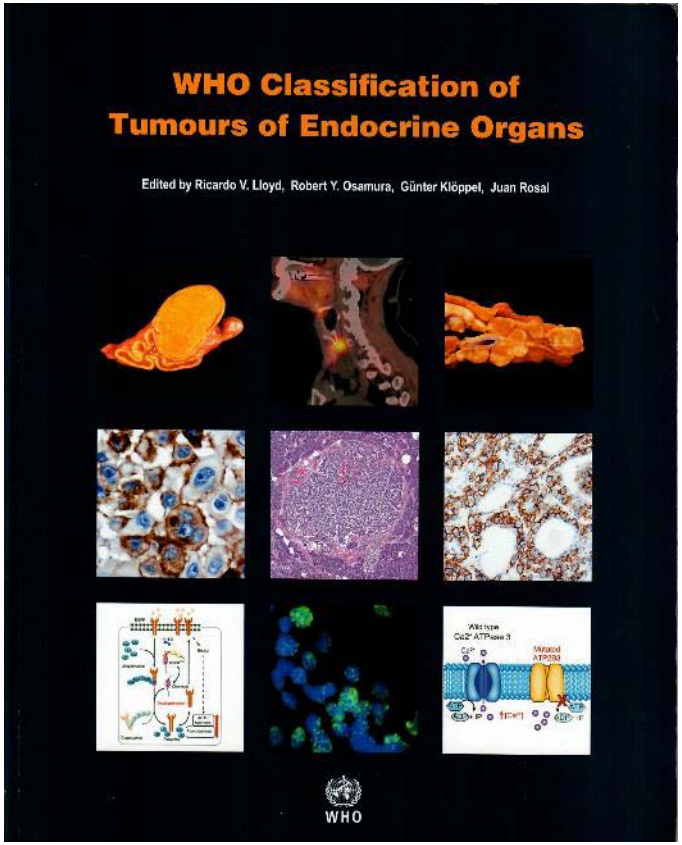

- Papillär
- Follikulär
- Hürthle cell
- Niedrig differenziert
- medullär
- Undifferenziert
- Gemischt medullär-follikulär
- Plattenepithelial
- Mukoepidermoid

WHO 2016: Neue Entitäten

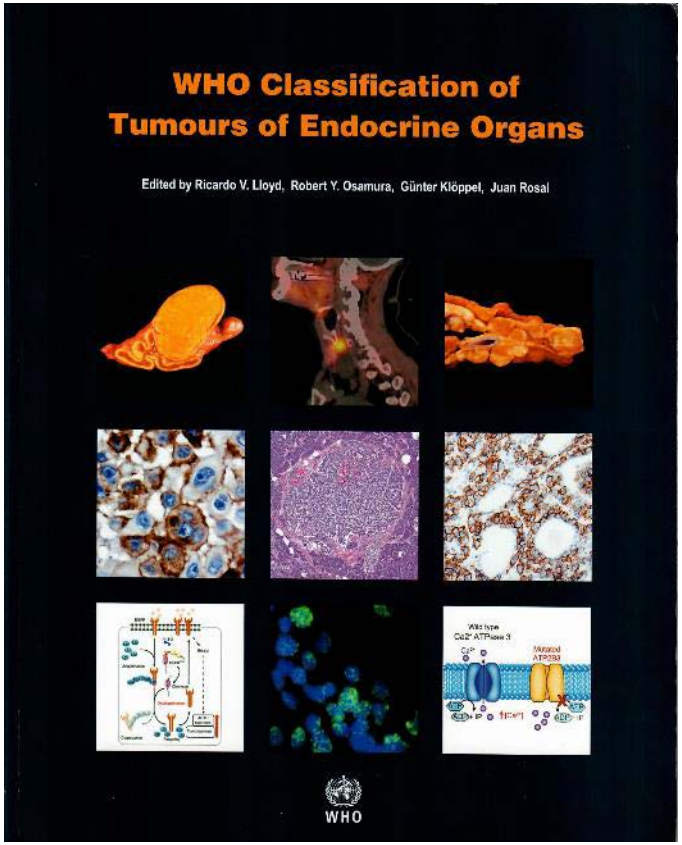

- Tumoren unsicherer maligner Potenz
- NIFT-P statt bekapselte follikuläre Variante des PTC
- Einteilung des follikulären Karzinoms
- Hürthlezell Tumoren

Benigne/intermediäre Tumoren

Follicular adenoma	8330/0
Hyalinizing trabecular tumour	8336/1*
Other encapsulated follicular-patterned thyroid tumours	
Follicular tumour of uncertain malignant potential	8335/1*
Well-differentiated tumour of uncertain malignant potential	8348/1*
Non-invasive follicular thyroid neoplasm with papillary-like nuclear features	8349/1*

Encapsulated follicular-patterned thyroid tumours

Table 2.02 2017 WHO classification: recommended nomenclature for encapsulated follicular-patterned tumours on the basis of the presence or absence of nuclear features of papillary thyroid carcinoma (PTC) and capsular or vascular invasion.

		Capsular or vascular invasion		
		Present	**Questionable**	**Absent**
Nuclear features of PTC	**Present**	Invasive encapsulated follicular variant of PTC	Well-differentiated tumour of uncertain malignant potential	Non-invasive follicular thyroid neoplasm with papillary-like nuclear features
	Questionable	Well-differentiated carcinoma, NOS		
	Absent	Follicular carcinoma	Follicular tumour of uncertain malignant potential	Follicular adenoma

NIFT-P

- Bekapselt
- Follikulärer Bau
- Kernveränderungen des papilären Karzinoms

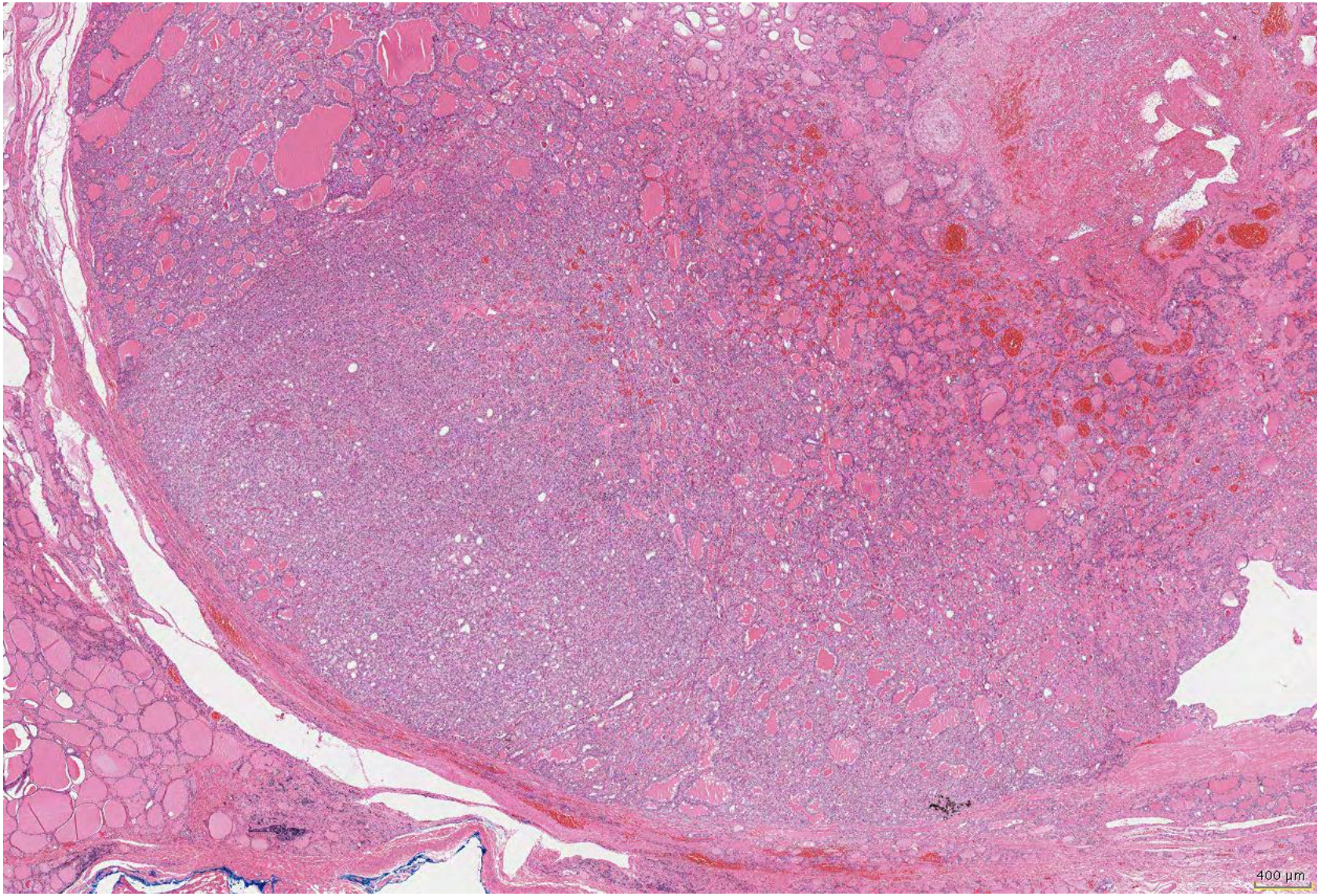
400 µm

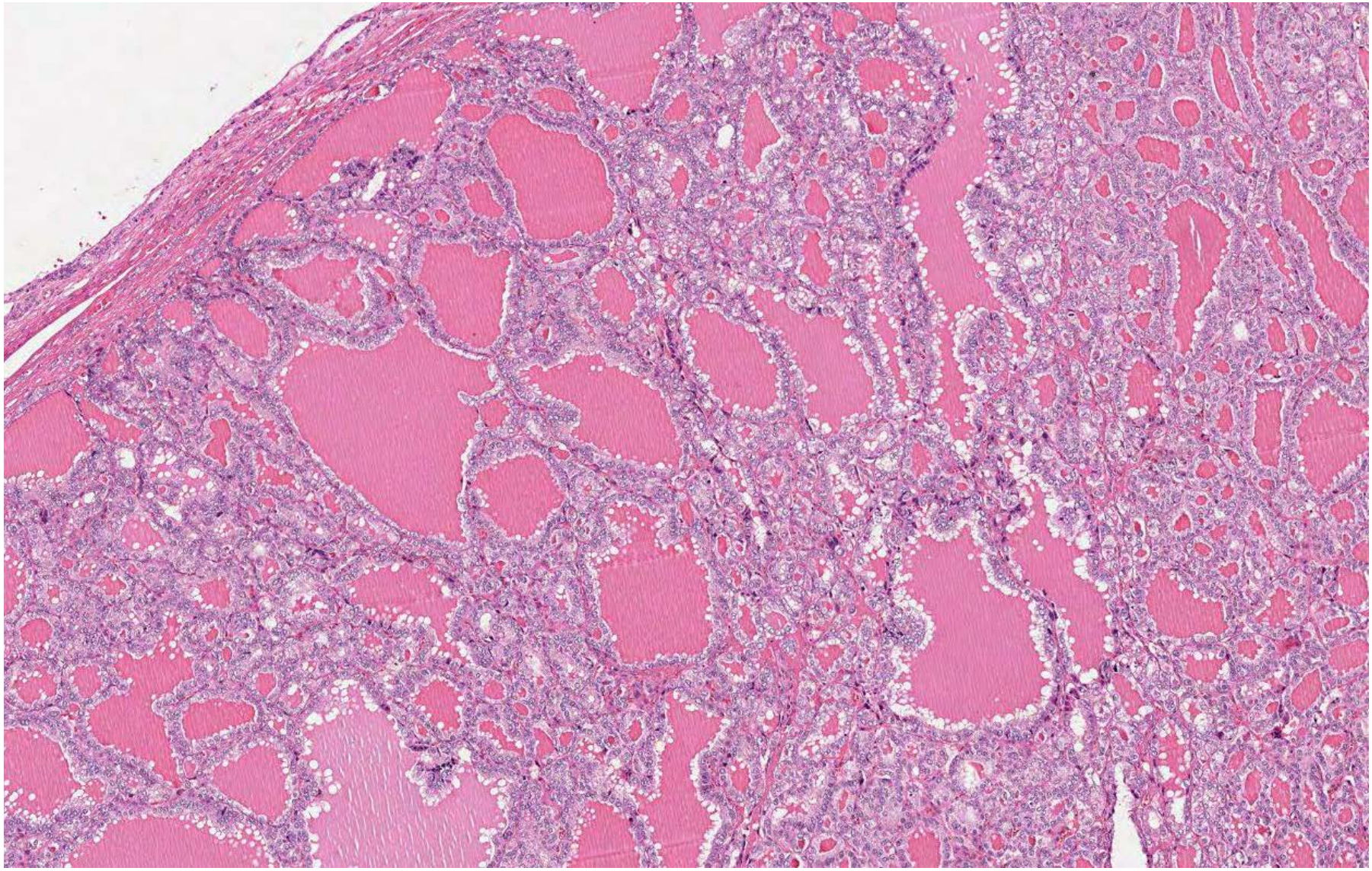

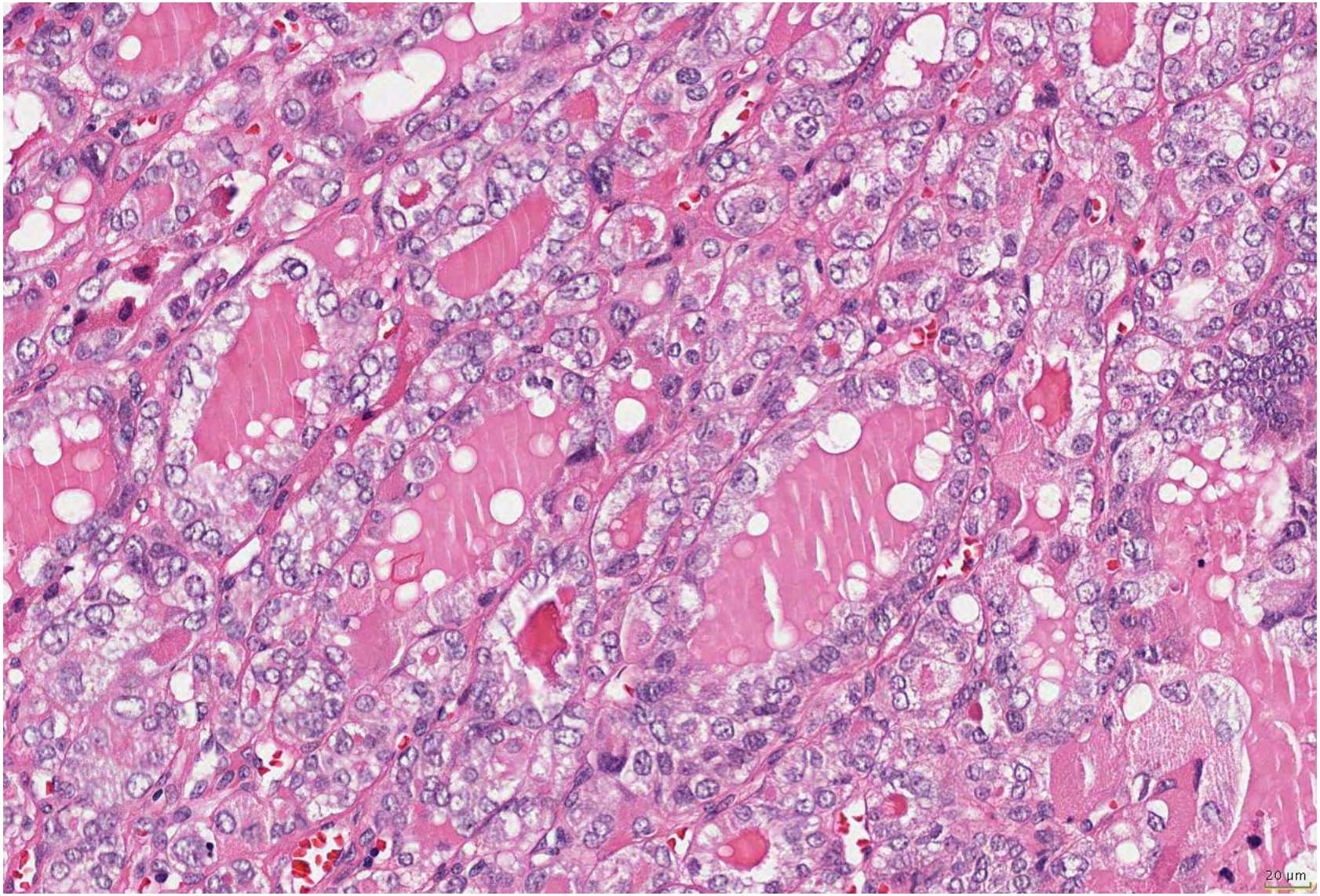
20 µm

Box 2. Diagnostic Criteria for NIFTP

1. Encapsulation or clear demarcation[a]
2. Follicular growth pattern[b] with
   <1% Papillae
   No psammoma bodies
   <30% Solid/trabecular/insular growth pattern
3. Nuclear score 2-3
4. No vascular or capsular invasion[c]
5. No tumor necrosis
6. No high mitotic activity[d]

[a] Thick, thin, or partial capsule or well circumscribed with a clear demarcation from adjacent thyroid tissue.

[b] Including microfollicular, normofollicular, or macrofollicular architecture with abundant colloid.

[c] Requires adequate microscopic examination of the tumor capsule interface.

[d] High mitotic activity defined as at least 3 mitoses per 10 high-power fields (400×).

Nikiforov et al., JAMA Oncol. 2016;2(8):1023-1029. doi:10.1001/jamaoncol.2016.0386

Scoring scale for nuclear features

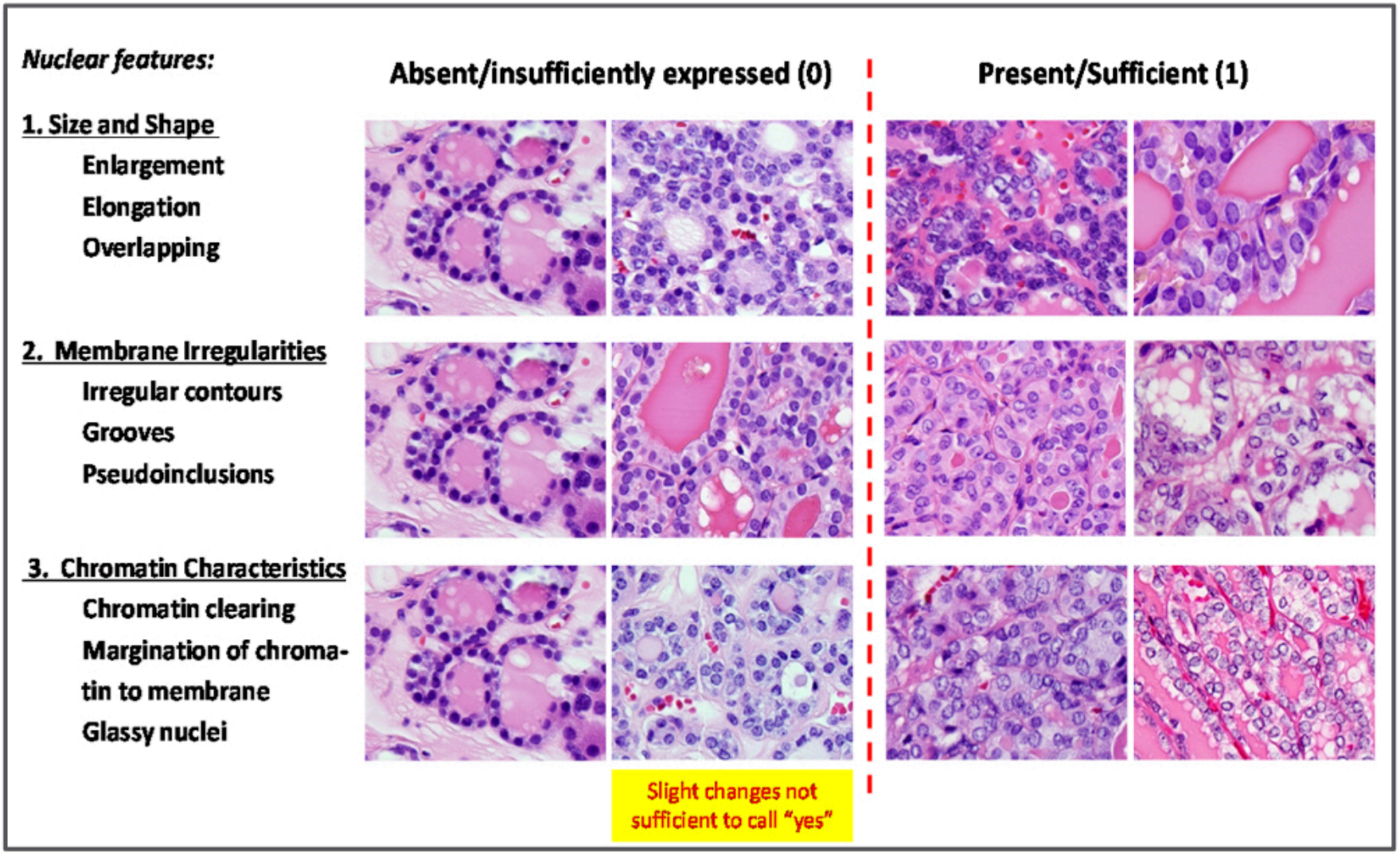

Nikiforov et al., JAMA Oncol 2016 Suppl.

Meilenstein

JAMA Oncology | Original Investigation

Nomenclature Revision for Encapsulated Follicular Variant of Papillary Thyroid Carcinoma

A Paradigm Shift to Reduce Overtreatment of Indolent Tumors

Yuri E. Nikiforov, MD, PhD; Raja R. Seethala, MD; Giovanni Tallini, MD; Zubair W. Baloch, MD, PhD; Fulvio Basolo, MD; Lester D. R. Thompson, MD; Justine A. Barletta, MD; Bruce M. Wenig, MD; Abir Al Ghuzlan, MD; Kennichi Kakudo, MD, PhD; Thomas J. Giordano, MD, PhD; Venancio A. Alves, MD, PhD; Elham Khanafshar, MD, MS; Sylvia L. Asa, MD, PhD; Adel K. El-Naggar, MD; William E. Gooding, MS; Steven P. Hodak, MD; Ricardo V. Lloyd, MD, PhD; Guy Maytal, MD; Ozgur Mete, MD; Marina N. Nikiforova, MD; Vania Nosé, MD, PhD; Mauro Papotti, MD; David N. Poller, MB, ChB, MD, FRCPath; Peter M. Sadow, MD, PhD; Arthur S. Tischler, MD; R. Michael Tuttle, MD; Kathryn B. Wall; Virginia A. LiVolsi, MD; Gregory W. Randolph, MD; Ronald A. Ghossein, MD

JAMA Oncol. 2016;2(8):1023-1029. doi:10.1001/jamaoncol.2016.0386

Table. Summary of Follow-up Information for Patients in the Study Groups

Characteristic	Group 1 (Noninvasive EFVPTC) (n = 109)	Group 2 (Invasive EFVPTC) (n = 101)
Age, mean (range), y	45.9 (21-81)	42.8 (8-78)
Sex, No. (%)		
Female	91 (83)	71 (70)
Male	18 (17)	30 (30)
Tumor size, mean (range), cm	3.1 (1.1-9.0)	2.5 (0.6-5.5)
Extent of surgery		
Lobectomy	67	15
Total thyroidectomy	42	86
Follow-up, y		
Mean (range)	14.4 (10-26)	5.6 (1-18)
Median	13.0	3.5
Adverse events during follow-up, No. (%)	0	12 (12)

No RAI therapy

Frequency of encapsulated follicular variant of PTC

Source	Setting/ Location	Time interval	Total number of PTC	Analysis performed	FVPTC	EFVPTC	EFVPTC with no invasion
G. Tallini, *unpublished*	Bellaria Hospital, Bologna, Italy	2000-2015	523	Hospital database search	22.4%	20.7%	13.6%
M. Papotti, *unpublished*	San Luigi Hospital, Turin, Italy	2005-2014	409	Hospital database search	36%	36%	25%
F. Basolo, *unpublished*	Hospital of Pisa, Pisa, Italy	2000-2004	2197	Hospital database search	43.4%	22.7%	18.7%
R. Ghossein, *unpublished*	MSKCC, NY, USA	2000-2003	303	Pathology slide review	27.7%	23.4%	18.8%
							Mean – 18.6%

PTC, papillary thyroid carcinoma; FVPTC, follicular variant of PTC; EFVPTC, encapsulated follicular variant of PTC

Nikiforov et al., JAMA Oncol 2016 Suppl.

Invasion rather than nuclear features correlates with outcome in encapsulated follicular tumors: further evidence for the reclassification of the encapsulated papillary thyroid carcinoma follicular variant☆

Ian Ganly MD, PhD[a], Laura Wang MD[a], R. Michael Tuttle MD[b], Nora Katabi MD[c], Gustavo A. Ceballos MD[d], H. Ruben Harach MD, PhD[e], Ronald Ghossein MD[c,*]

Human Pathology (2015) 46, 657–664

- 57 non invasive, 26 invsive EFVPTC
- 9.5 years FU
- NIEFVPTC behave like adenoma
- 16% of IFVPTC poor outcome

Tumoren unsicheren malignen Potenzials: FT-UMP, WDT-UMP)

- Fragliche Invasion (Kapsel, Gefäße)
- Fragliche Kernkriterien des PTC

Papilläres Karzinom

Papillary thyroid carcinoma (PTC)	
Papillary carcinoma	8260/3
Follicular variant of PTC	8340/3
Encapsulated variant of PTC	8343/3
Papillary microcarcinoma	8341/3
Columnar cell variant of PTC	8344/3
Oncocytic variant of PTC	8342/3

Papilläres Karzinom

Mikrokarzinom: okkult

Klinisch manifestes Karzinom

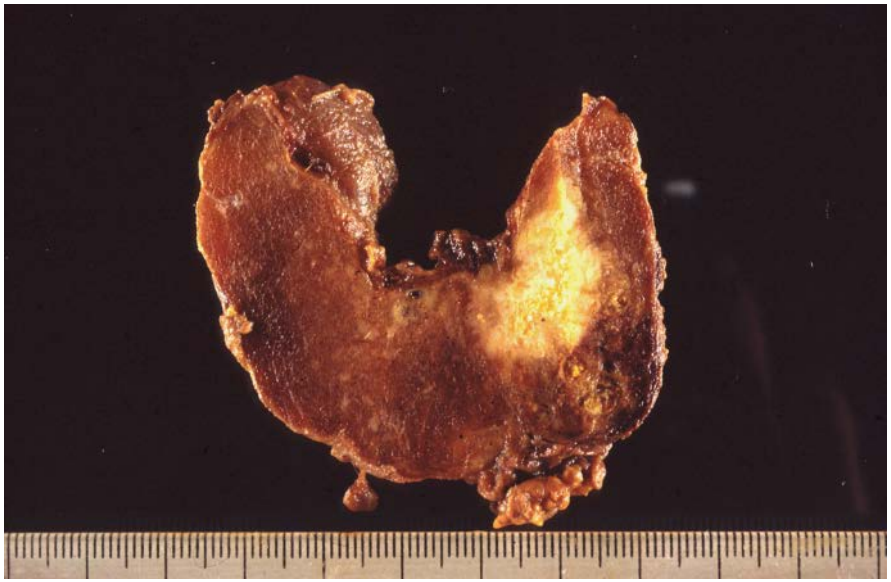

Papilläres Karzinom

Histologie

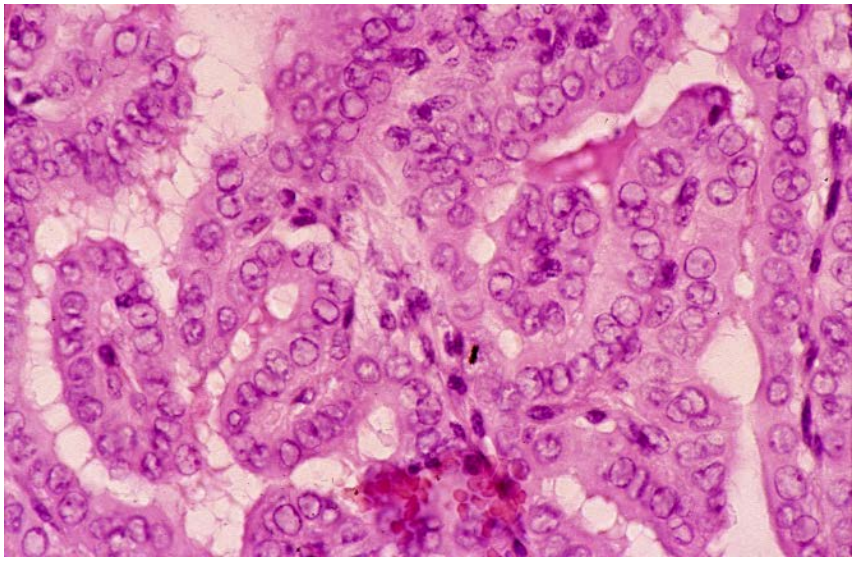

Zytologie

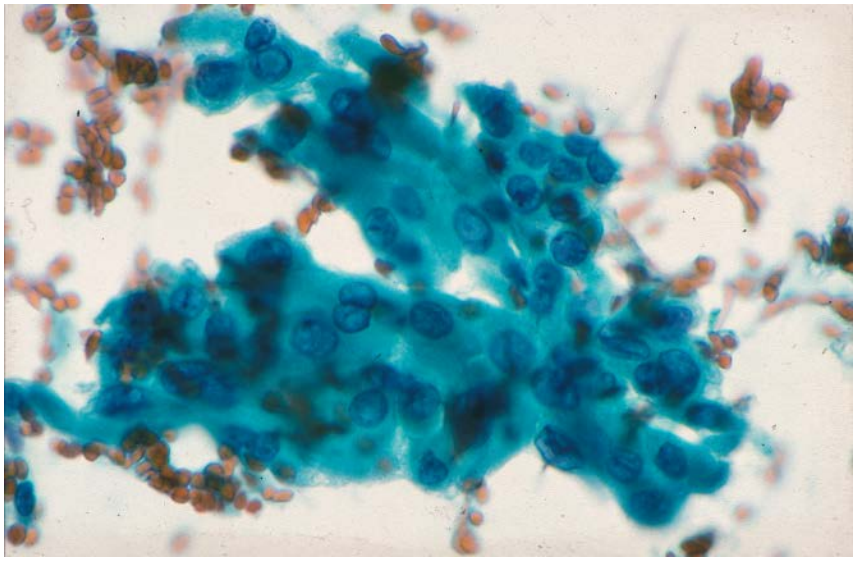

Papilläres Karzinom: columnar cell

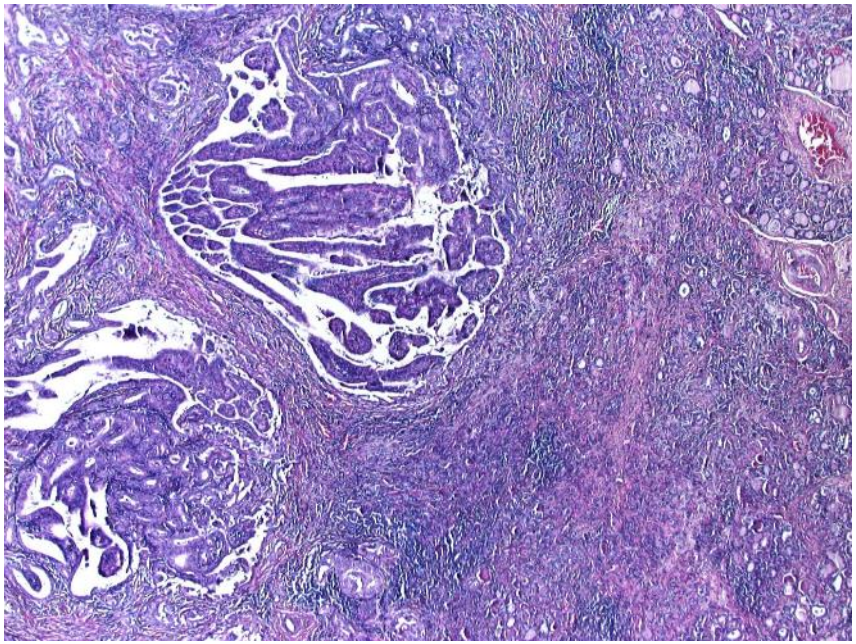

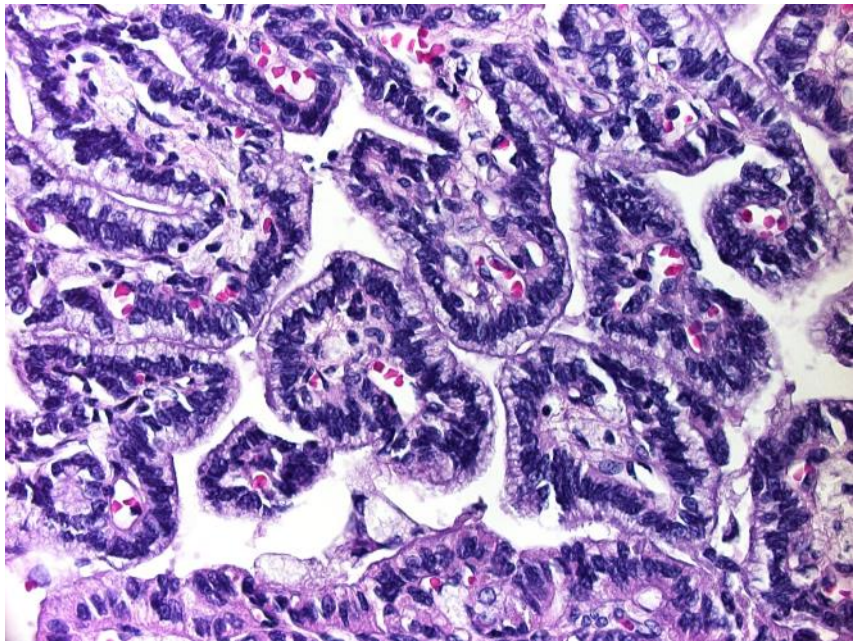

Papilläres Mikrokarzinom

- Multifokalität in 30%
- Klinische Lymphknotenmetastasen in <1%
- Rezidive in 0,05% (Neuhold et al., Ann Surg Oncol 2011)
- Kein aggressives Verhalten !
- Porto Proposal: Papillärer Mikrotumor
- Ausnahmen (ca. 1%):
  - klinische Lymphknotenmetastasen
  - Extrathyroidales Wachstum

Zufallsbefund im Rahmen einer Strumaresektion

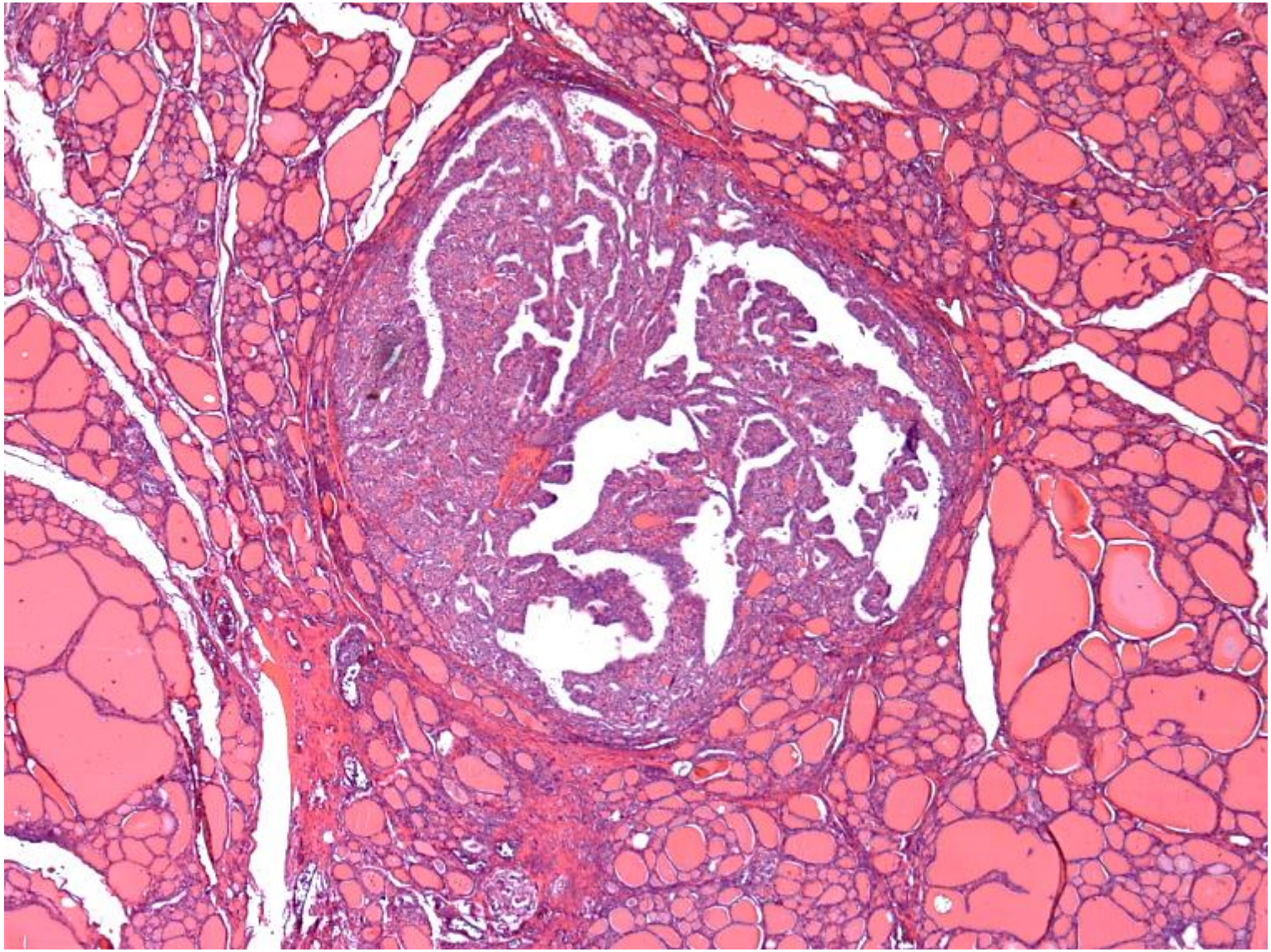

Follikuläres Karzinom und andere

Follicular thyroid carcinoma (FTC), NOS	8330/3
FTC, minimally invasive	8335/3
FTC, encapsulated angioinvasive	8339/3*
FTC, widely invasive	8330/3
Hürthle (oncocytic) cell tumours	
Hürthle cell adenoma	8290/0
Hürthle cell carcinoma	8290/3
Poorly differentiated thyroid carcinoma	8337/3

Follikuläres Schilddrüsenkarzinom

- Kernveränderungen des PTC fehlen
- Meist bekapselt
- Invasives Wachstum (Angioinvasion)
- Keine oxiphile Differenzierung

- Zytologie: follikuläre Neoplasie
- DD: PDTC, FA, FTUMP

Follikuläres Schilddrüsenkarzinom

Table 2.07 Classification of follicular thyroid carcinoma

Traditional {2596}	**Armed Forces Institute of Pathology (AFIP) 2014** {2340}		**WHO 2017**
Minimally invasive	Minimally invasive	With capsular invasion	Minimally invasive
		With limited vascular invasion (<4 vessels)	Encapsulated angioinvasive
		With extensive vascular invasion (≥4 vessels)	
Widely invasive	Widely invasive		Widely invasive

Minimal invasives follikuläres Karzinom

- 65 Fälle
- > 10 Jahre Follow up
- Trennung von Kapselinvasion und Gefäßinvasion

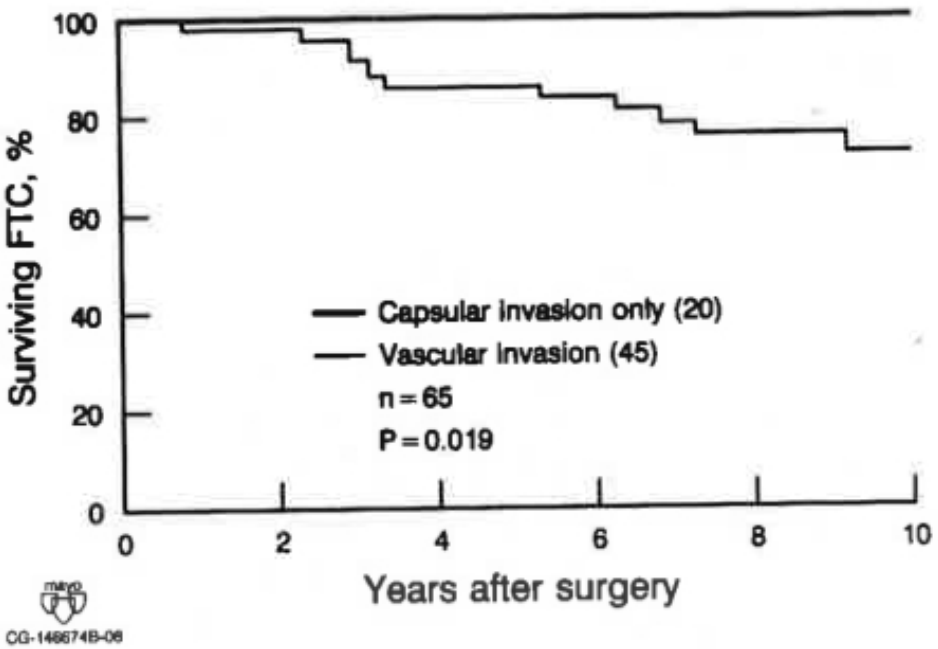

Van Heerden et al., Surgery 1992

Follikuläres Karzinom:Kapsel-/Angioinvasion

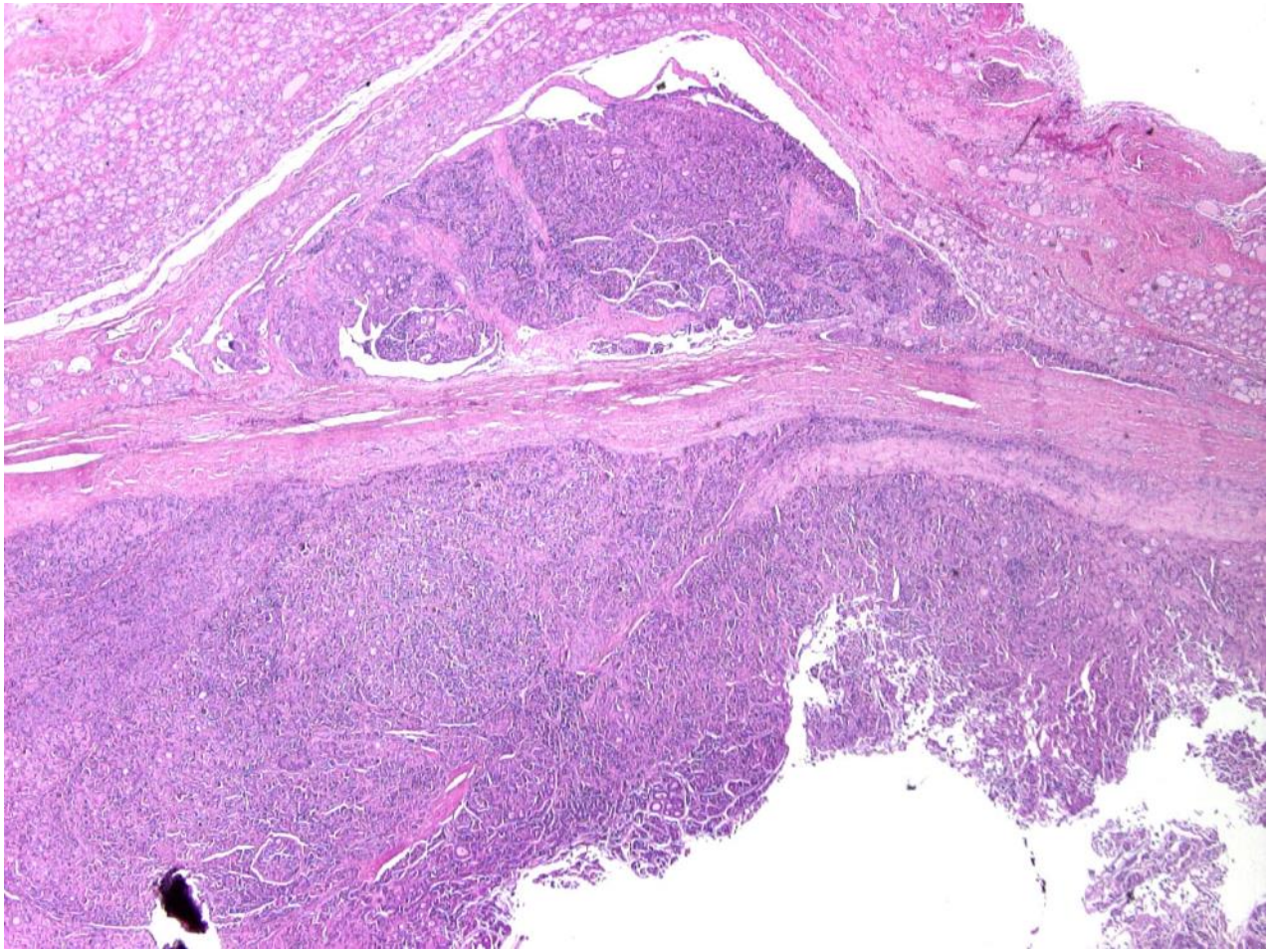

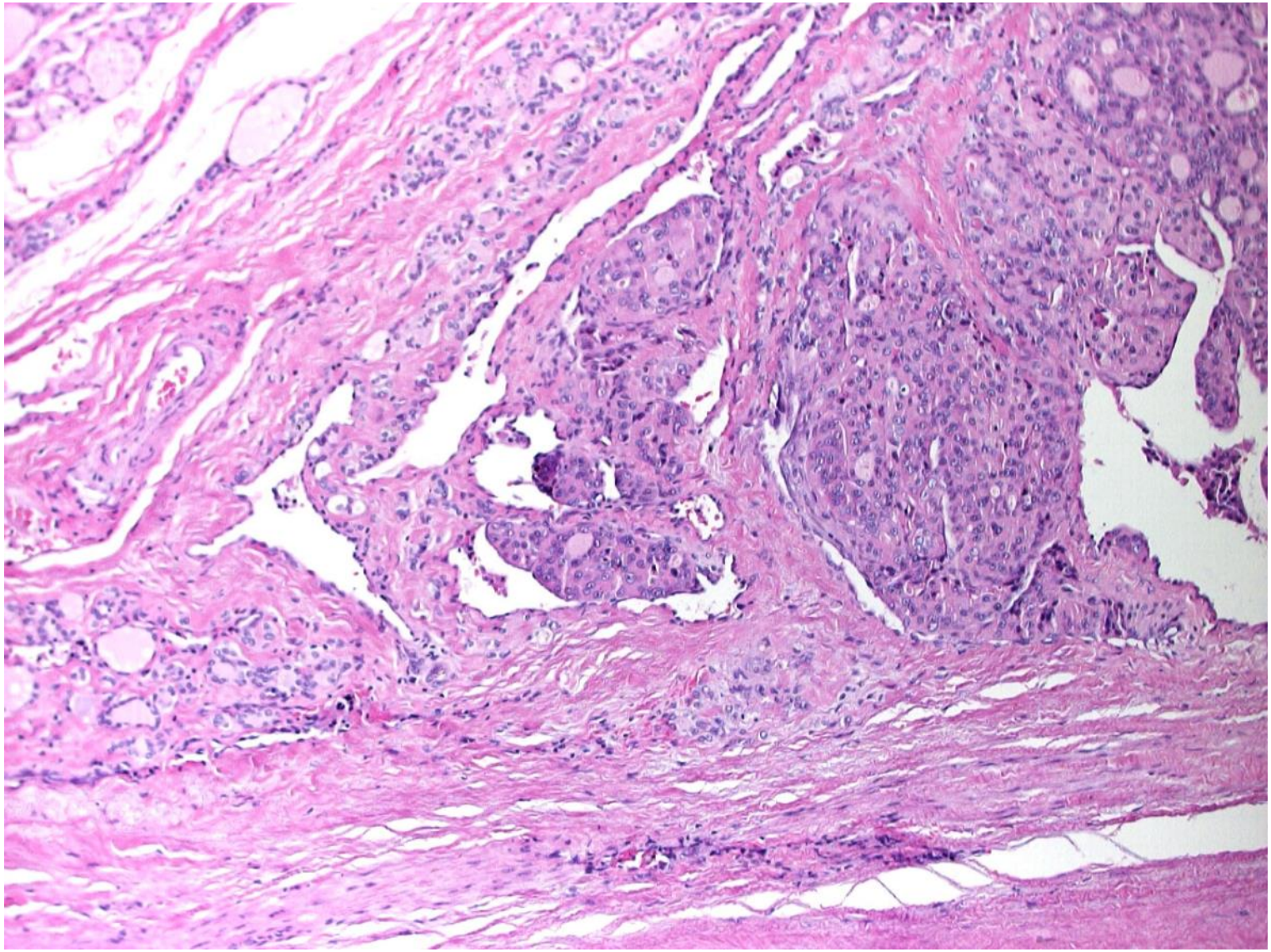

Hürthlezell (onkozytäre) Tumoren

- Eigene Kategorie (früher: follikuläre Ad/Ca)
- Molekular: Mutationen in Genen für Mitochondrienmembran; RAS Mut. seltener
- Begriff falsch aber in Literatur etabliert
- Adenom versus Karzinom: Invasion
- Karzinome: eher trabekulär, kleinere Zellen
- Nach FNA (onkozyt. Npl.)Totalnekrose möglich
- kleiner Teil der HCC > anaplastisches Karzinom

Follikuläre (Onkozytäre) Neoplasie

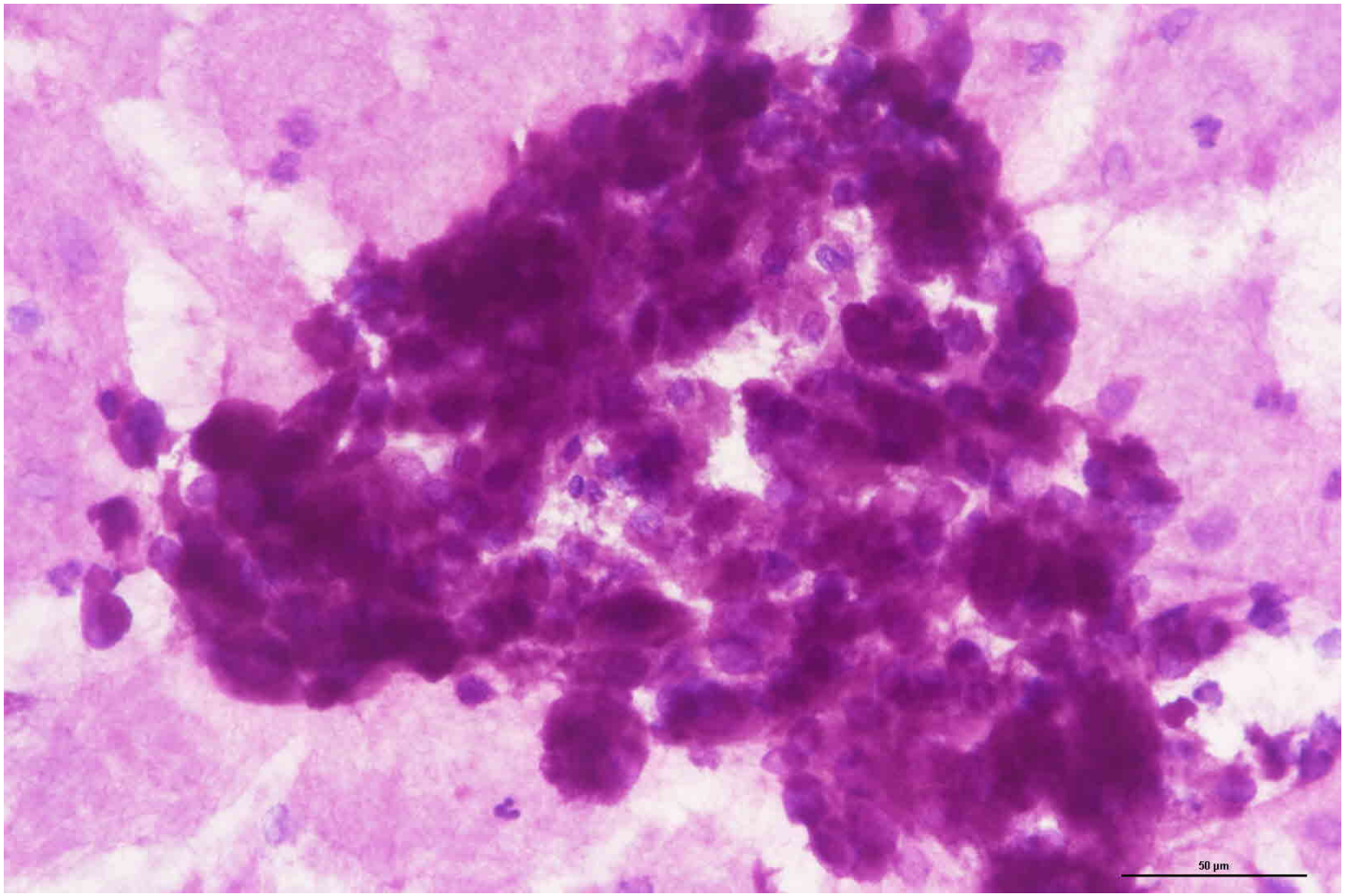

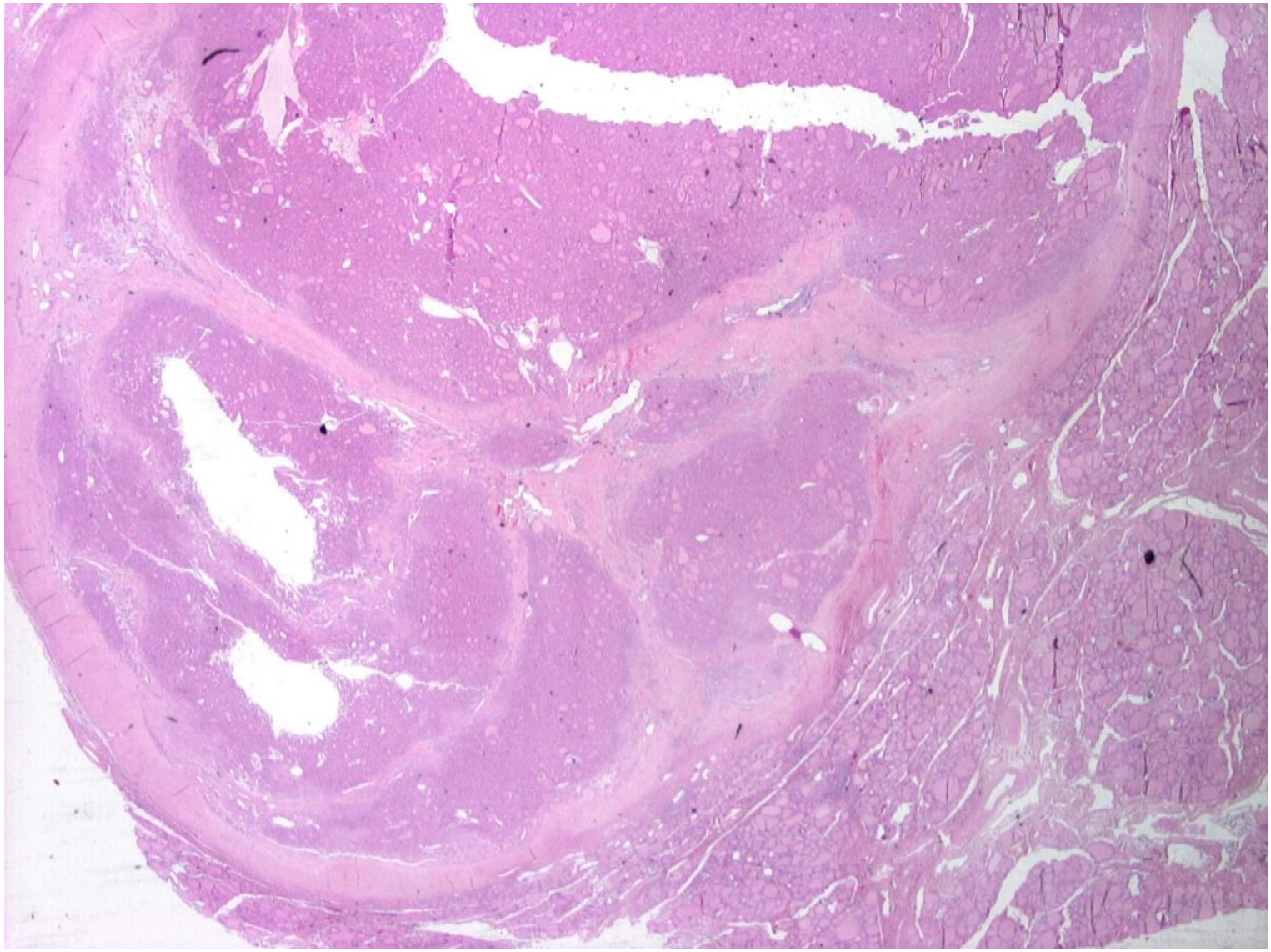

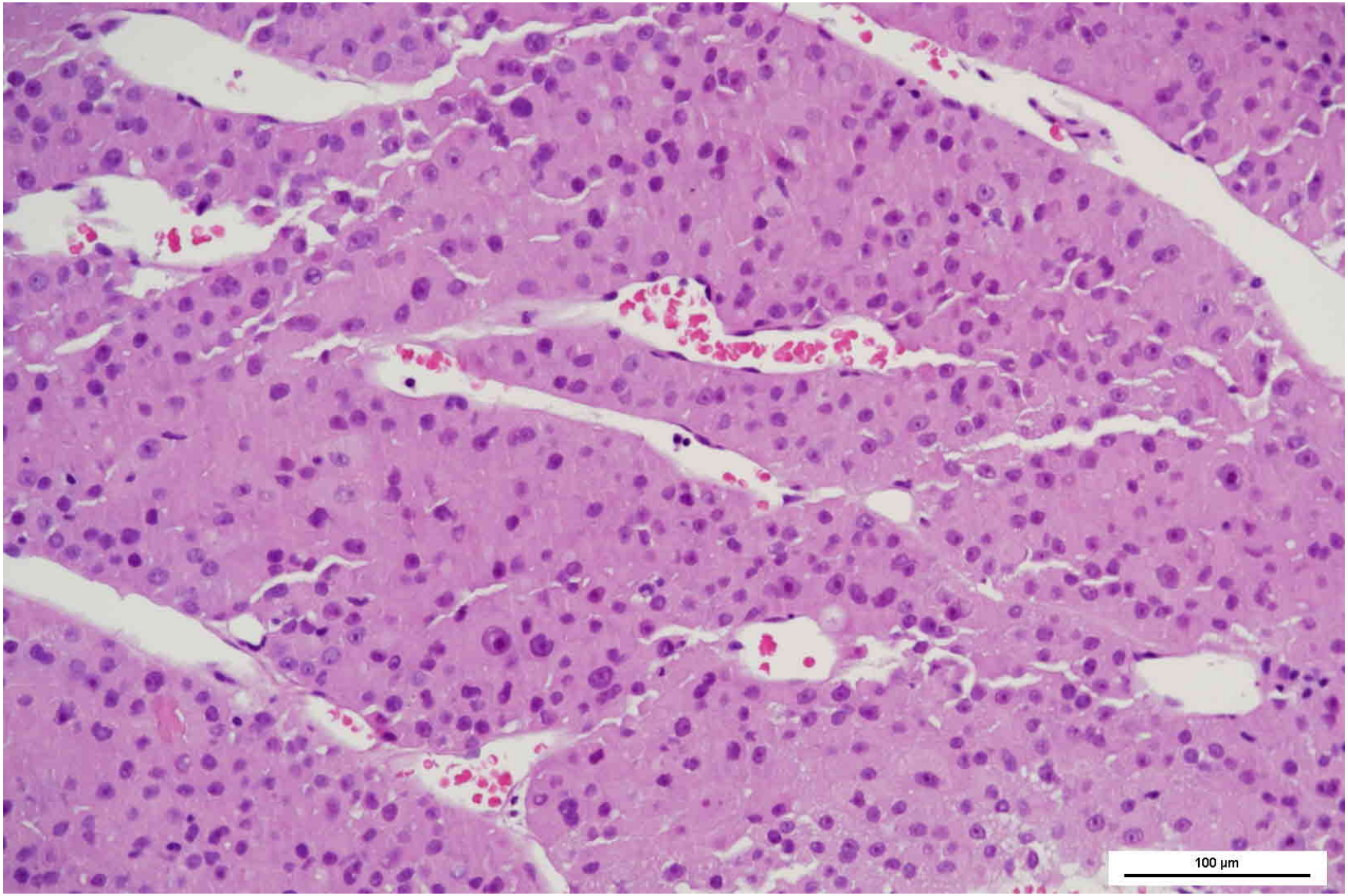
100 µm

Hürthlezell Karzinom

- 50 Fälle
- Alle enkapsuliert
- Gefäßeinbrüche signifikant für rezidivfreies Überleben
- Daneben: solider Aufbau; Mitosen; >4cm

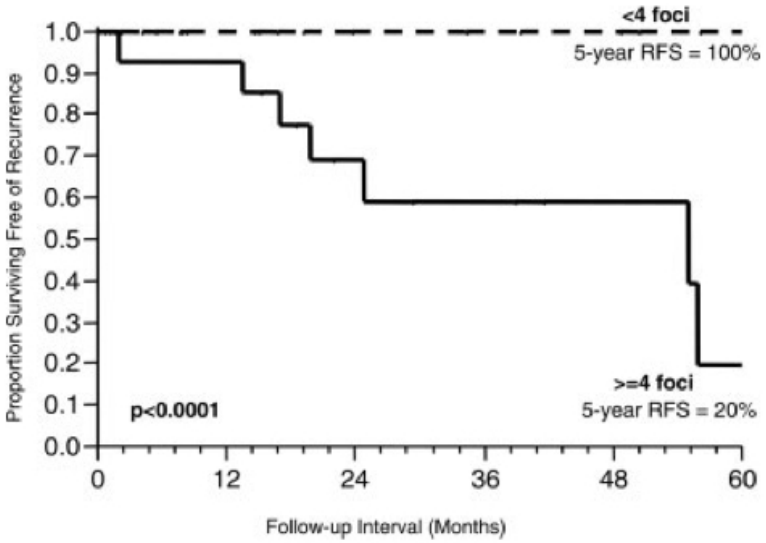

Ghossein et al., Cancer 2006

Niedrig differenziertes Karzinom

- Follikel-Bezug aber follikuläre Differenzierung eingeschränkt erkennbar
- Prognose zwischen papillärem/follikulärem und anaplastischem Karzinom

Diagnose des PDTC

- Baumuster (solide, trabekulär, insulär)
- Zellkerne rosinenartig (convoluted)
- Nekrosen
- Mitosen

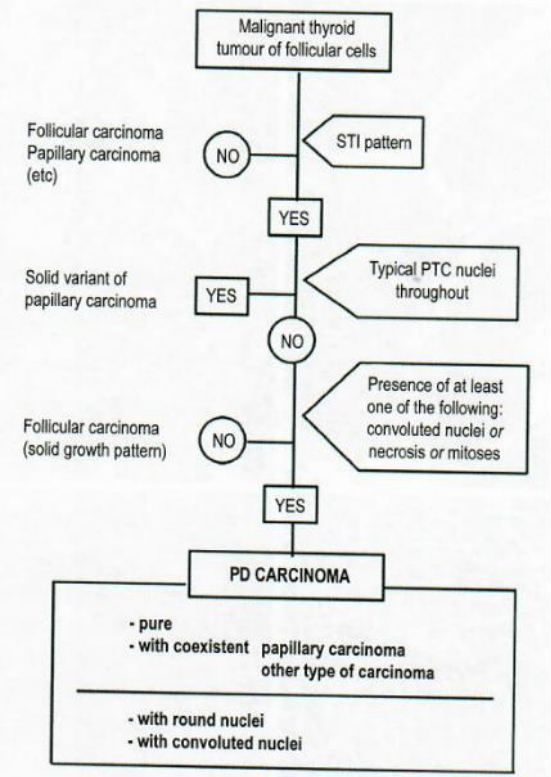

Fig. 2.63 Algorithm for the diagnosis of poorly differentiated (PD) thyroid carcinoma using the Turin consensus criteria. PTC, papillary thyroid carcinoma; STI, solid, trabecular, or insular. Reprinted from Volante M, Collini P, Nikiforov YE, et al. (2007) {2891}.

Niedrig differenziertes Karzinom

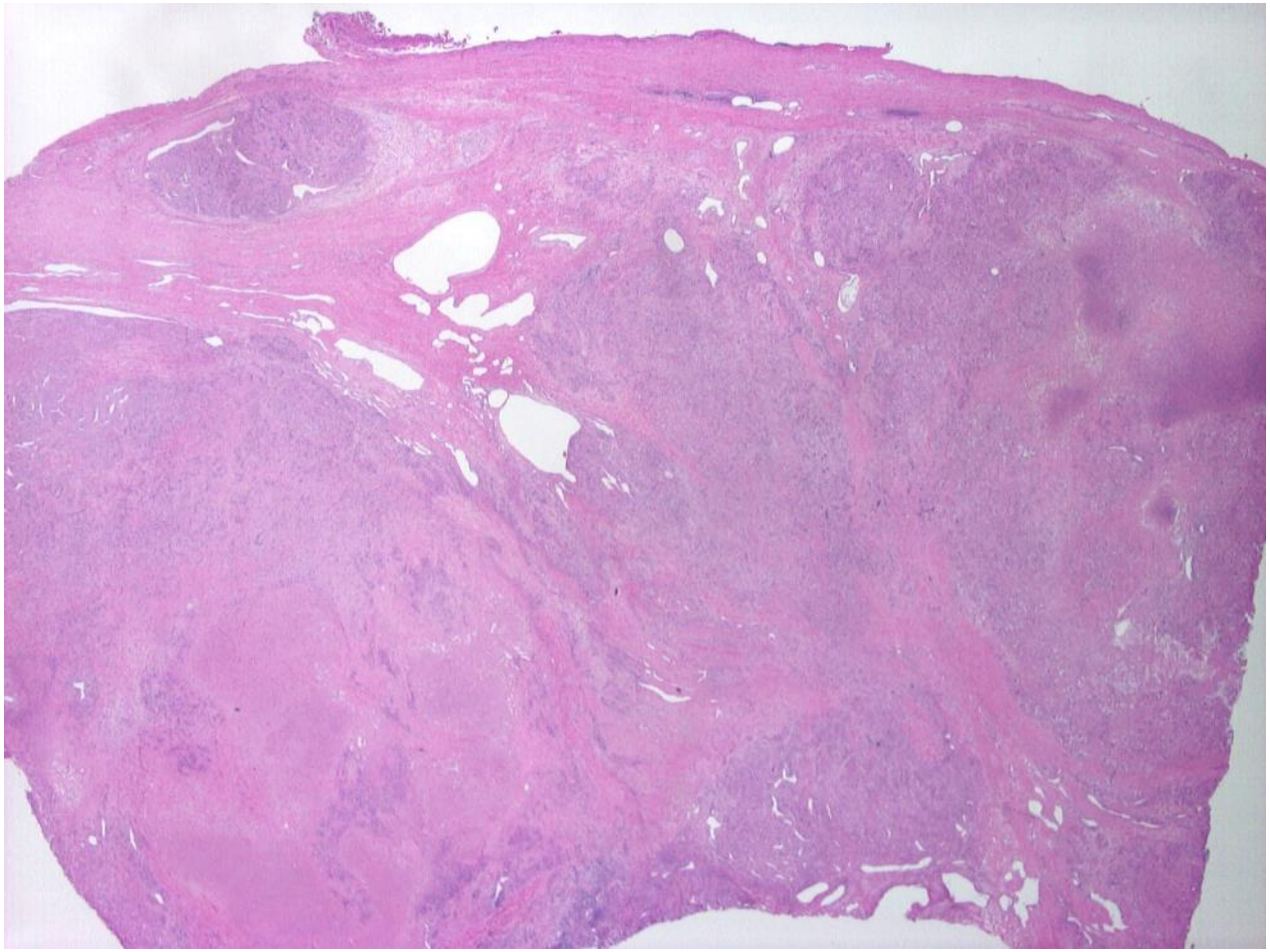

Morphologie - Wachstumsmuster

insulär

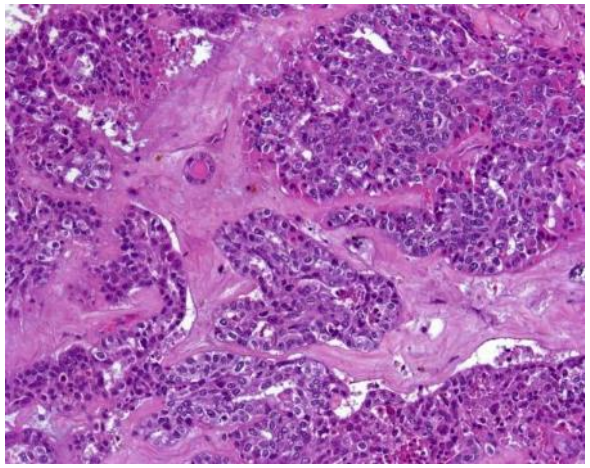

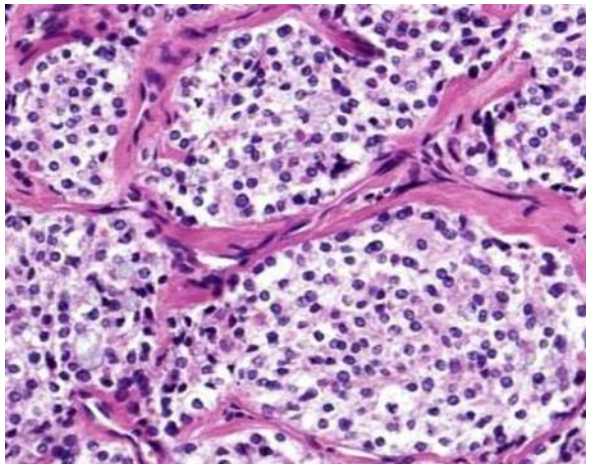

solide

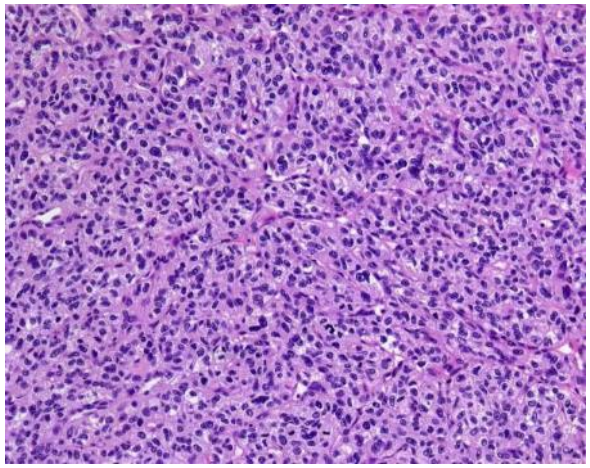

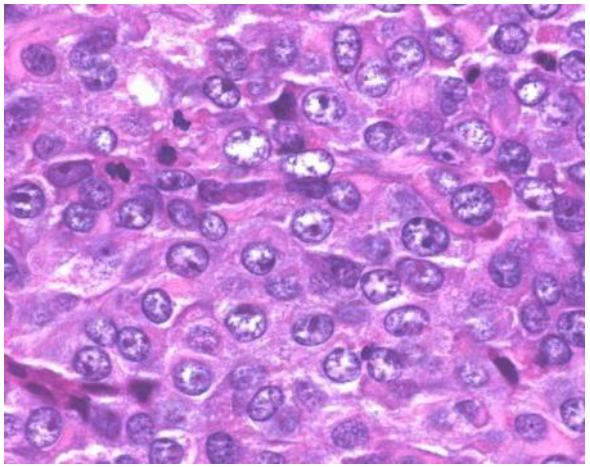

trabekulär

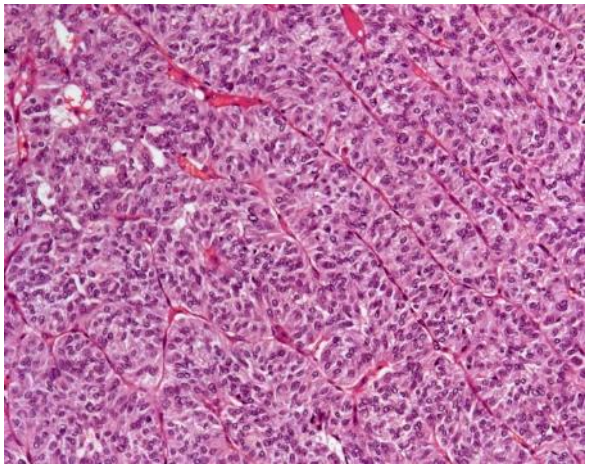

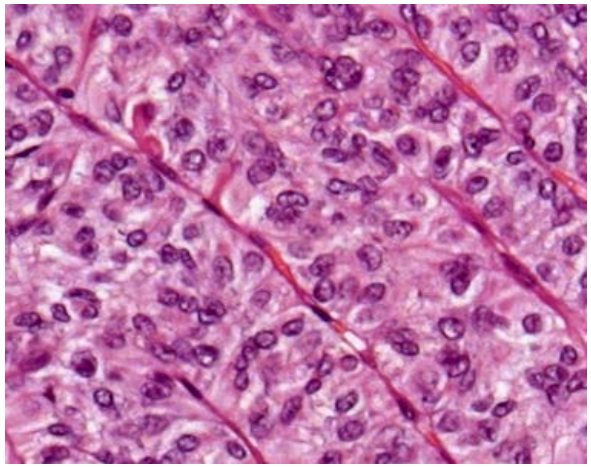

Courtesy: Prof. K.W. Schmid, Essen

Zytologie

Kerne, Mitosen, Nekrosen

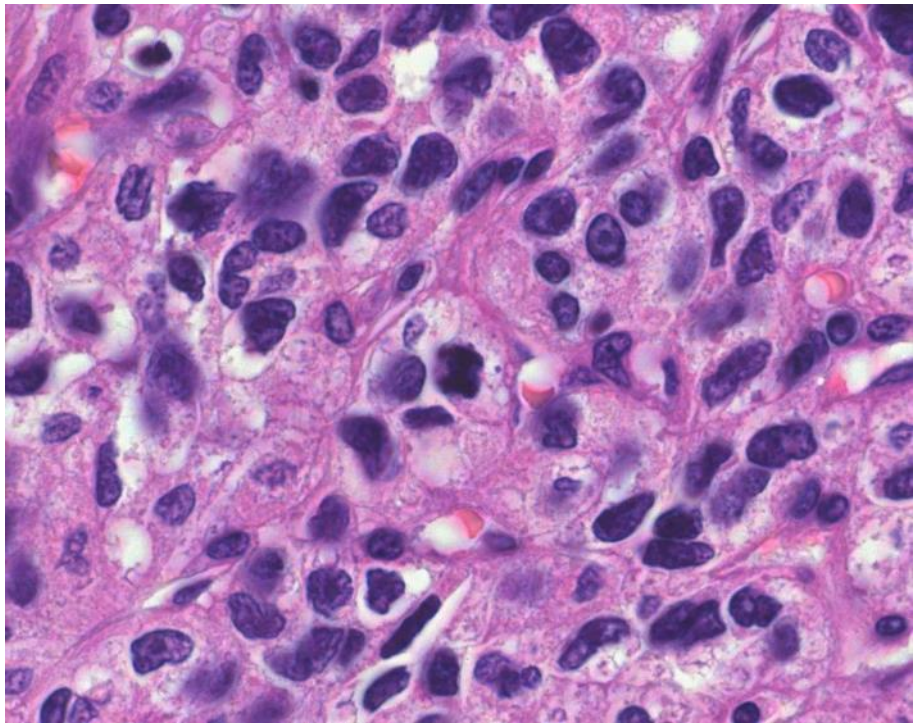

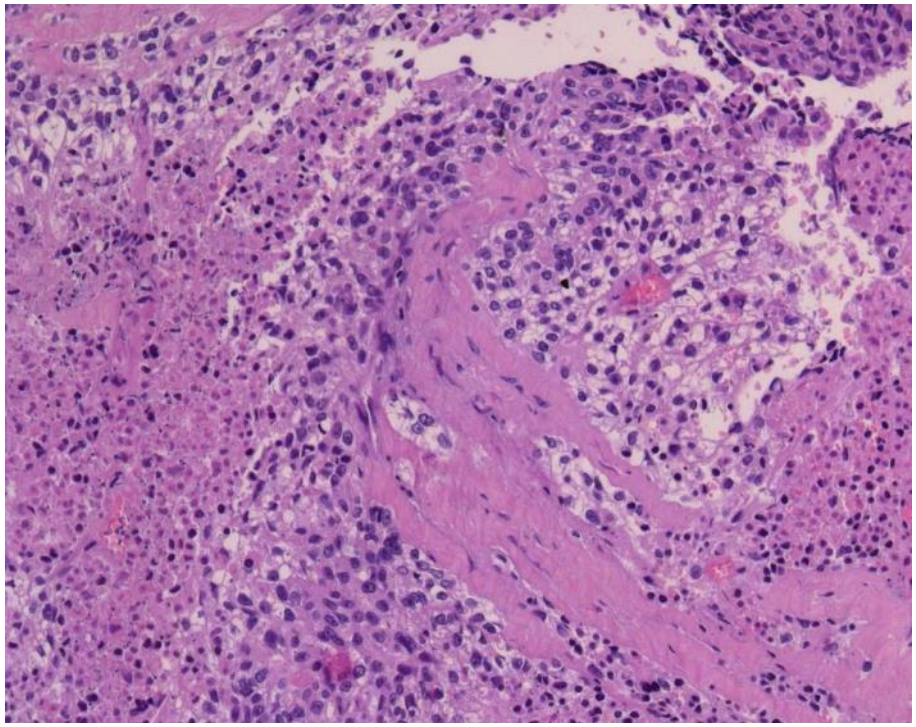

Courtesy: Prof. K.W. Schmid, Essen

PDTC: Weitere Eigenschaften

- Positivität für P53 (fokal), Cyclin D1
- Erhöhter Ki-67 Färbeindex
- RAS, TERT Mutationen

PDTC: Prognostische Faktoren

Table 2.10 Prognostic factors independently associated with survival in poorly differentiated carcinomas by multivariate analysis.

Poor prognosis		
Clinicopathological factors – Patient age ≥ 45 years {106} – Tumour size ≥ 5 cm {997} – Macroscopically evident extrathyroidal extension (pT4a) at surgery {1205} – Distant metastases (M1) at presentation {1205}	**Histological and immunohistochemical factors** – Tumour necrosis {106} – IMP3 immunoreactivity {106} – Oncocytic features[a] {671}	**Molecular genetic factors** – RAS gene mutation {2895} – Downregulation of miR-150[b] {672}
Good prognosis		
Histological factor – Convoluted (papillary carcinoma–like) neoplastic cell nuclei {106}		

[a] This association is controversial; poorly differentiated oncocytic carcinomas were not statistically associated with poor survival in other series {106,1143}.

[b] Downregulation of miR-23b was independently associated with tumour recurrence in the same study {672}.

Überlebenskurven von Patienten mit Schilddrüsenkarzinomen mit Follikelzell-Differenzierung

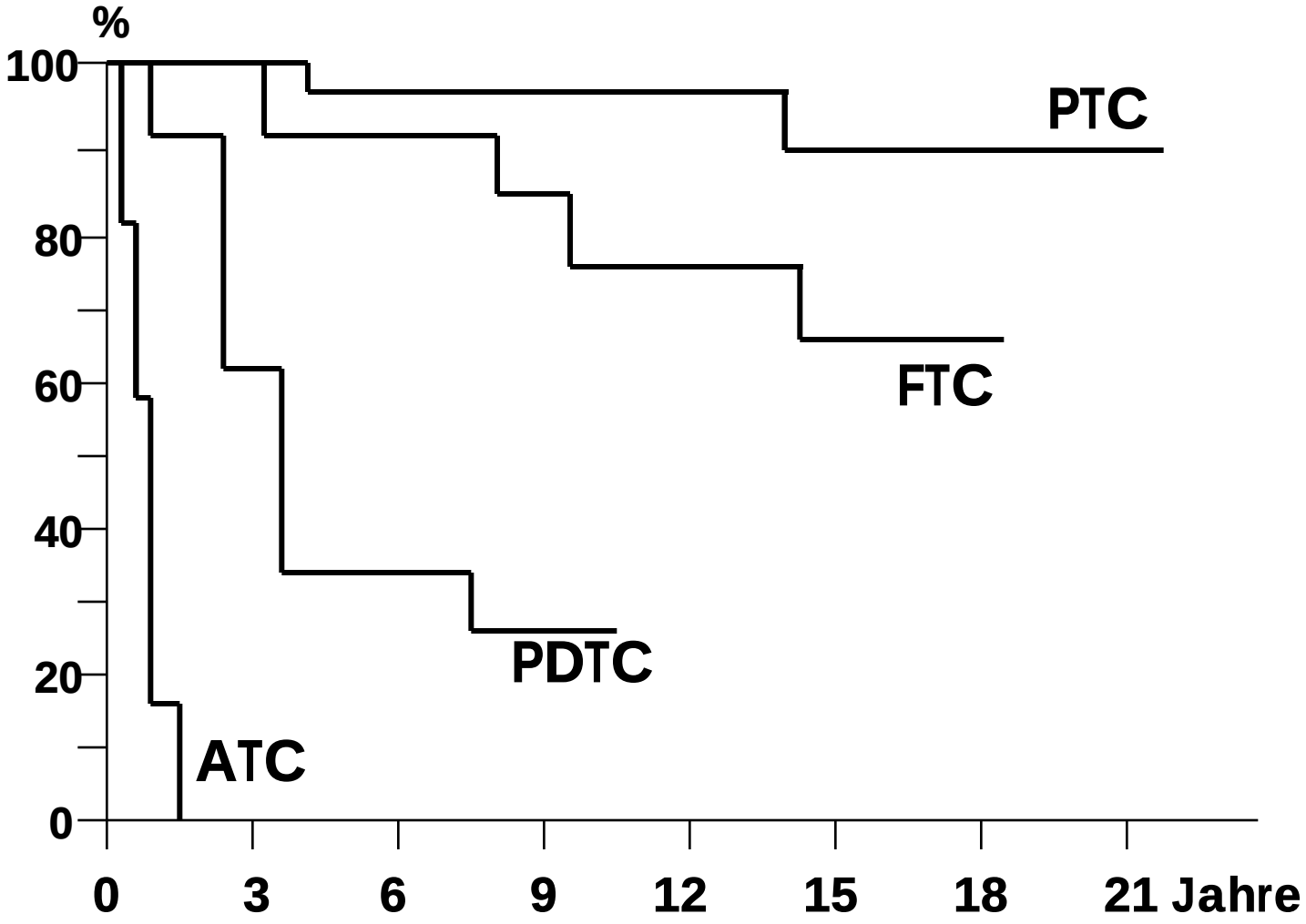

Courtesy: Prof. K.W. Schmid, Essen

Diverse andere Tumoren

Anaplastic thyroid carcinoma	8020/3
Squamous cell carcinoma	8070/3
Medullary thyroid carcinoma	8345/3
Mixed medullary and follicular thyroid carcinoma	8346/3
Mucoepidermoid carcinoma	8430/3
Sclerosing mucoepidermoid carcinoma with eosinophilia	8430/3
Mucinous carcinoma	8480/3

Medulläres Karzinom

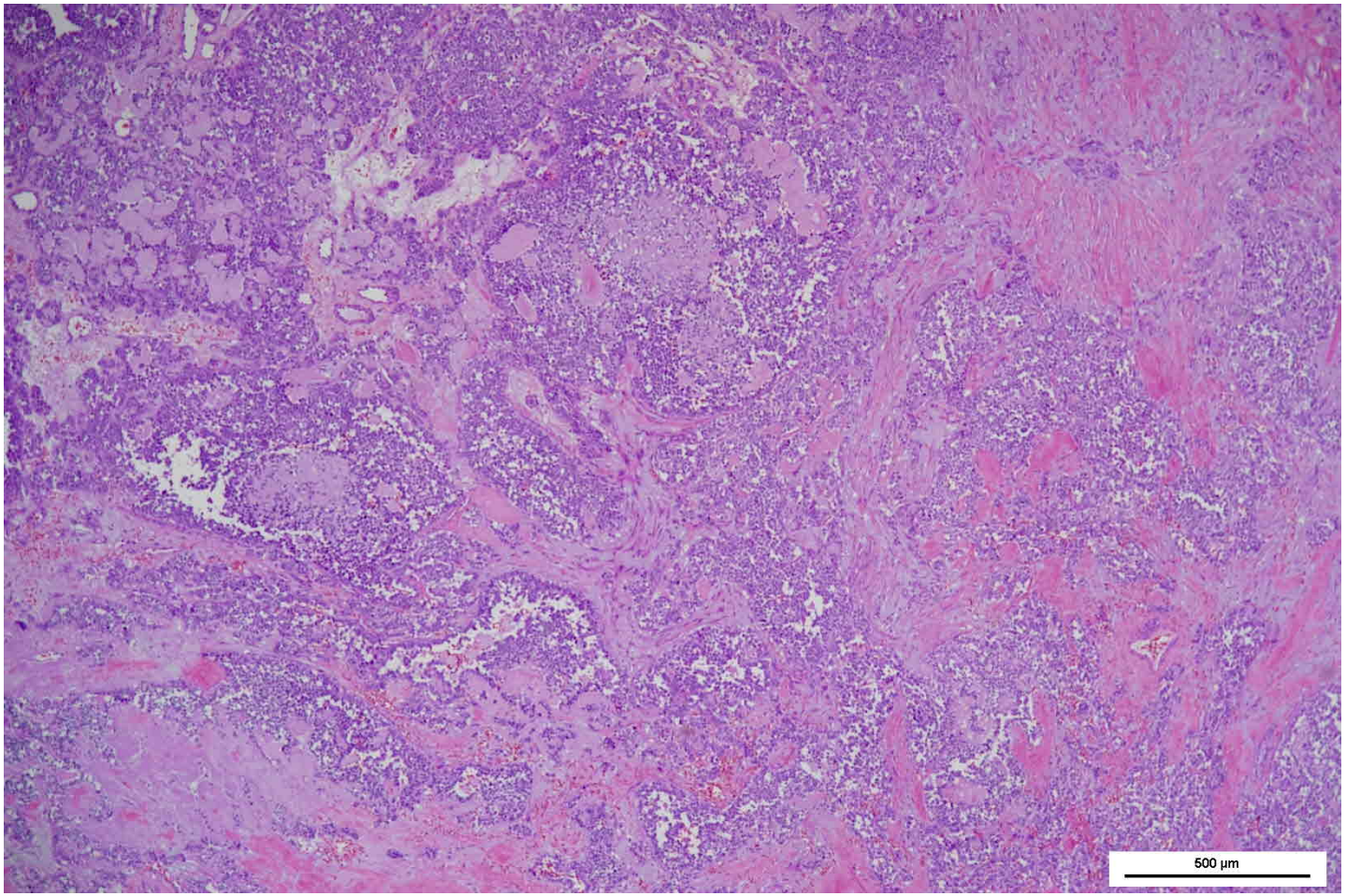

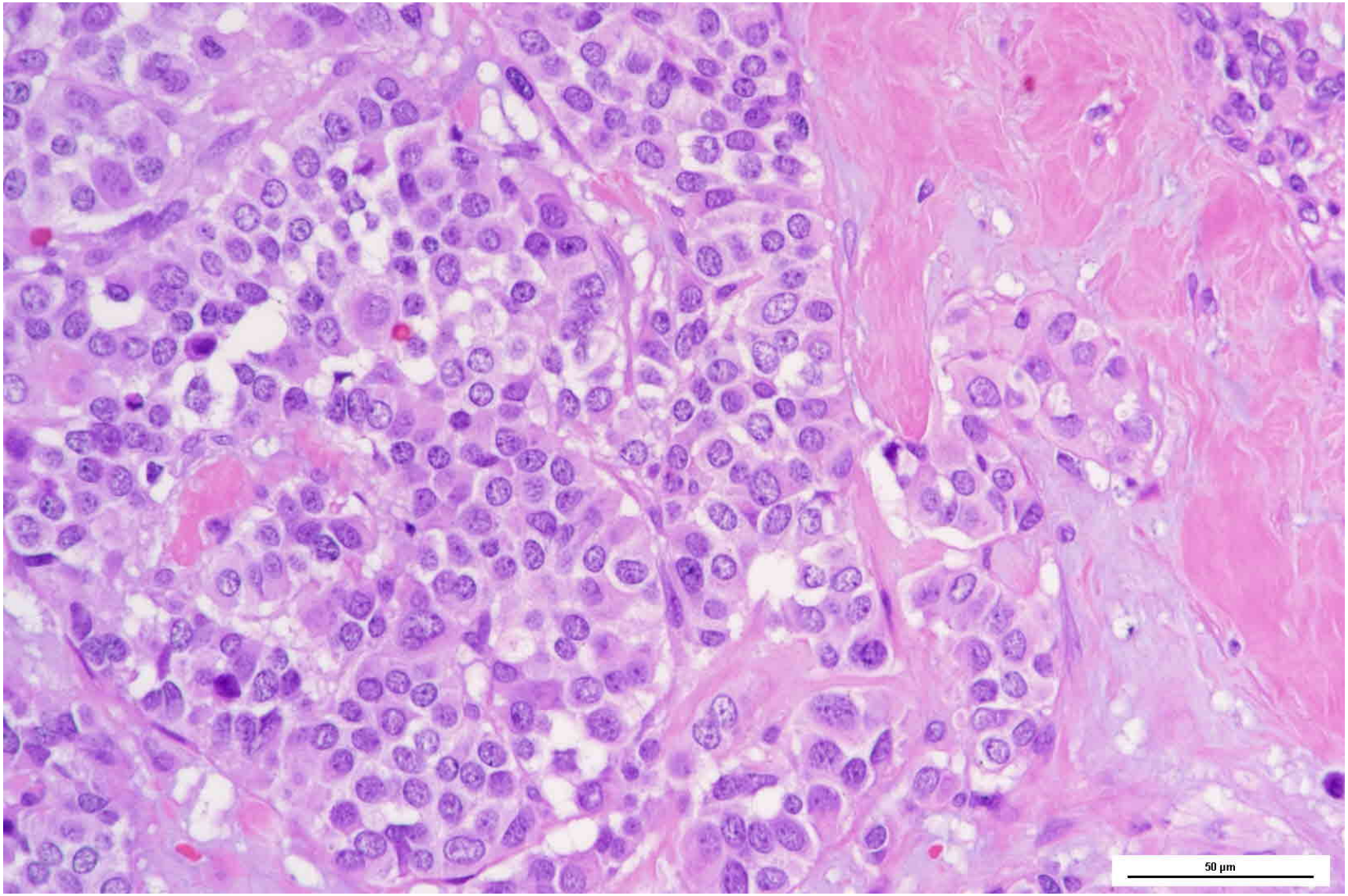
50 µm

Immunhistochemie: Calcitonin

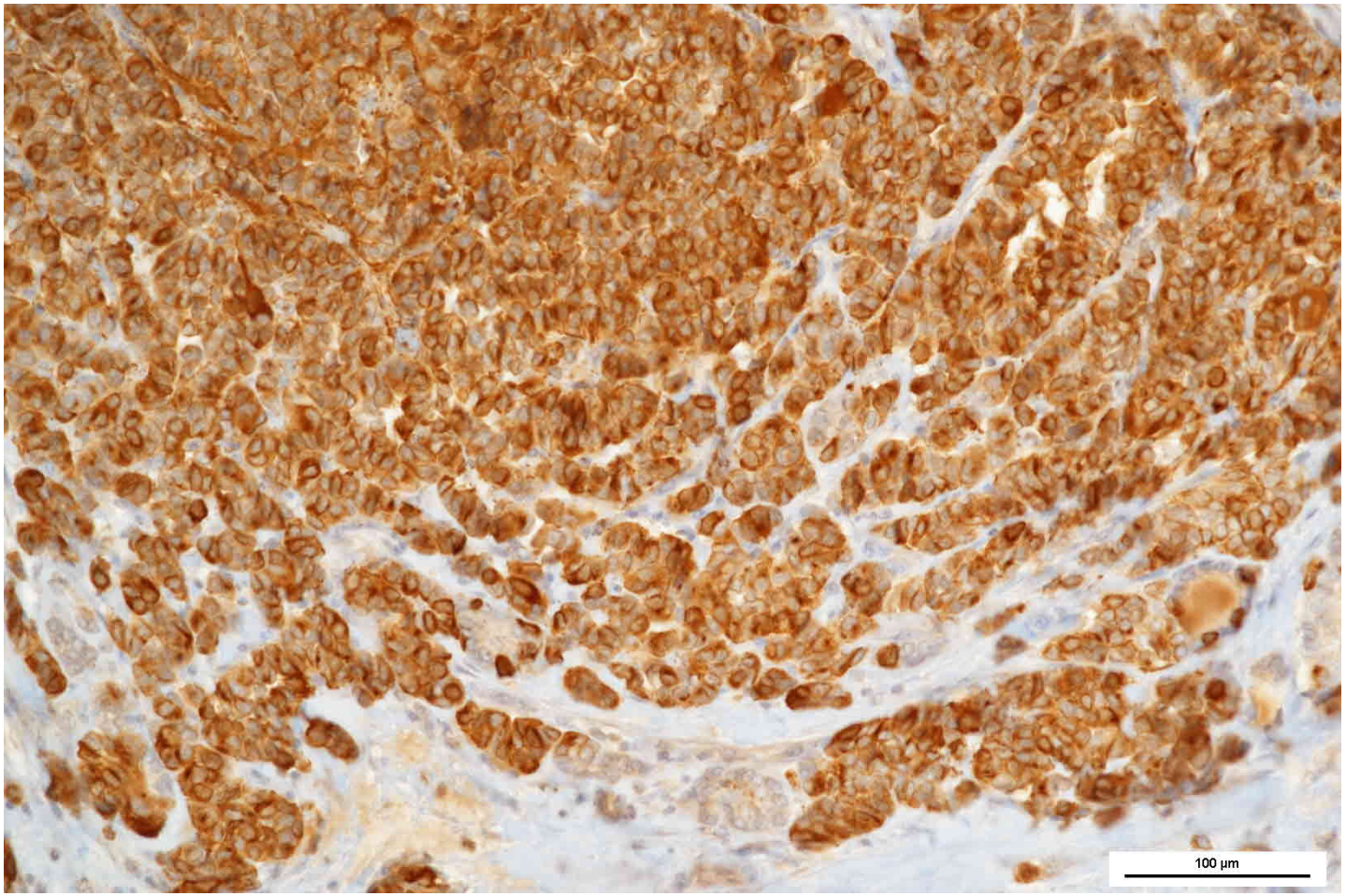

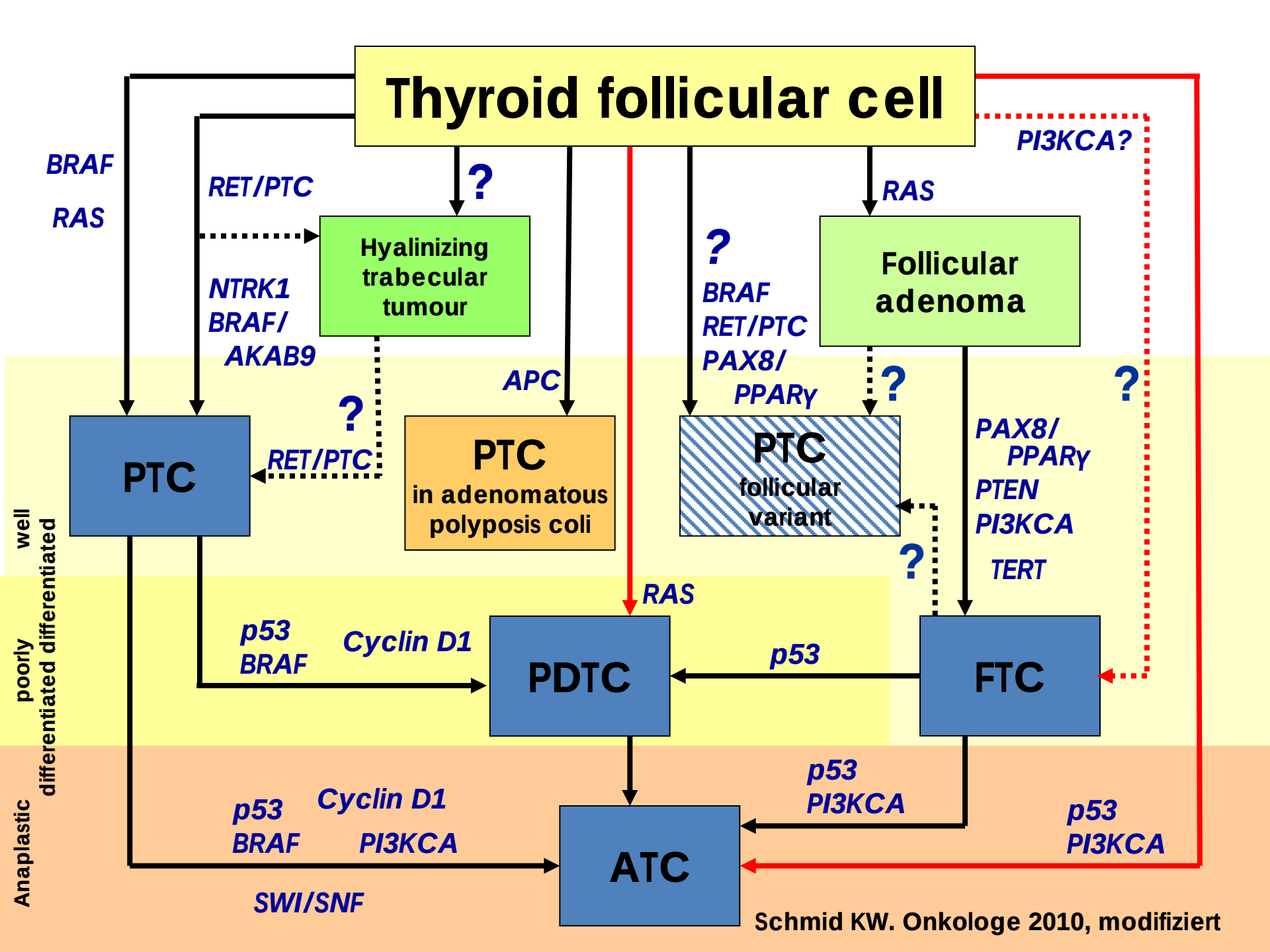

Schmid KW. Onkologe 2010, modifiziert

Cytology: Terminology

ÖGZ Group		Terminology (Bethesda)	ÖGP Group	Risk of Malignancy (%)	Usual Management	Thyroid Surgery	Lymph node dissection
0	Non diagnostic	Non diagnostic or unsatisfactory	0	**	Repeat FNA with US	No	No
A	Benign	Benign	A	0-3	Clinical Follow-up	No	No
B	Indeterminate (e.g. follicular neoplasm)	AUS or FLUS	B0	5-15	Repeat FNA/ (Surgery)	No/(Hemi-thyroidectomy)	No
		Follicular neoplasm or suspicious for a follicular neoplasm (specify if Hürthle cell (oncocytic) type)	B1	15-30	Surgery	Hemi-thyroidectomy/ (Total thyroidectomy)	No
		Suspicious for malignancy	B2	60-75		Hemithyroidectomy/ (Total thyroidectomy)	Central neck dissection (unilateral)
C	Highly suspicious for malignancy/ malignant	Malignant	C	97-99		(Total thyroidectomy)	Central neck dissection (bilateral) Functional lateral neck dissection (Uni-/bilateral)

Table 1. The 2017 Bethesda System for Reporting Thyroid Cytopathology: Recommended Diagnostic Categories

I. NONDIAGNOSTIC OR UNSATISFACTORY
Cyst fluid only
Virtually acellular specimen
Other (obscuring blood, clotting artifact, etc.)
II. BENIGN
Consistent with a benign follicular nodule (includes adenomatoid nodule, colloid nodule, etc.)
Consistent with lymphocytic (Hashimoto) thyroiditis in the proper clinical context
Consistent with granulomatous (subacute) thyroiditis
Other
III. ATYPIA OF UNDETERMINED SIGNIFICANCE *or* FOLLICULAR LESION OF UNDETERMINED SIGNIFICANCE
IV. FOLLICULAR NEOPLASM *or* SUSPICIOUS FOR A FOLLICULAR NEOPLASM
Specify if Hürthle cell (oncocytic) type
V. SUSPICIOUS FOR MALIGNANCY
Suspicious for papillary carcinoma
Suspicious for medullary carcinoma
Suspicious for metastatic carcinoma
Suspicious for lymphoma
Other
VI. MALIGNANT
Papillary thyroid carcinoma
Poorly differentiated carcinoma
Medullary thyroid carcinoma
Undifferentiated (anaplastic) carcinoma
Squamous-cell carcinoma
Carcinoma with mixed features (specify)
Metastatic carcinoma
Non-Hodgkin lymphoma
Other

Adapted with permision from Ali and Cibas (7).

WHO 2016 und Zytologie

- Keine wesentlichen Veränderungen in Bethesda 2017
- Bethesda hat WHO 2016 zum Teil vorweggenommen
- NIFT-P hat unterschiedliche Zytologie: häufig follikuläre Neoplasie oder AUS, selten maligne (Singh et al., Thyroid 2017)

Thyroid Carcinoma
Papillary and Follicular

The definition of T3 has been revised for papillary and follicular and medullary carcinomas

T3a Tumour more than 4 cm in greatest dimension, limited to the thyroid

T3b Tumor of any size with gross extrathyroidal extension invading only strap muscles (sternohyoid, sternothyroid, or omohyoid muscles)

The age for a poor prognosis has changed from 45 years to 55 years

Stage < 55 years old

Stage I	Any T	Any N	M0
Stage II	Any T	Any N	M1

Stage ≥55 years old

Stage I	T1a,T1b,T2	N0	M0
Stage II	T3	N0	M0
	T1, T2, T3	N1	M0
Stage III	T4a	Any N	M0
Stage IVA	T4b	Any N	M0
Stage IVB	Any T	Any N	M1

Inzidenz und Mortalität des Schilddrüsenkarzinoms: Österreich 1990-2007

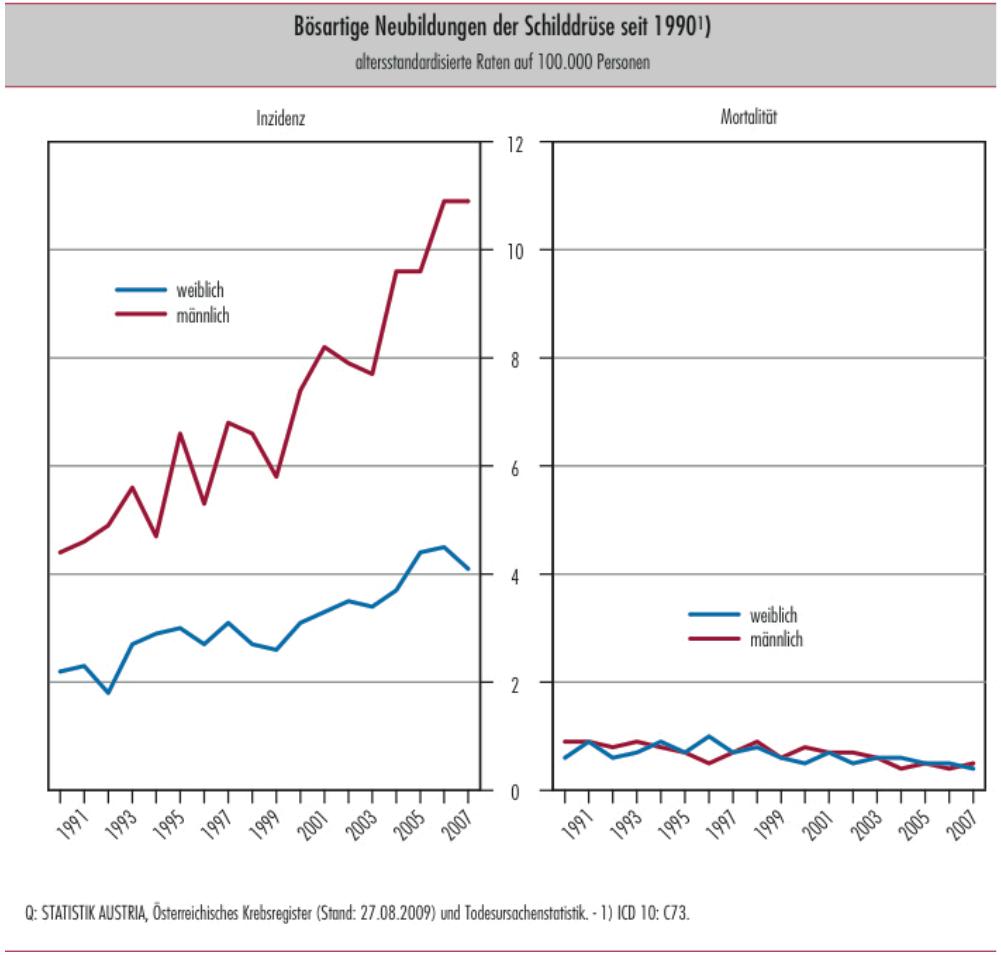

Entwicklung der bösartigen Neubildungen der Schilddrüse[1]), Österreich ab 2002

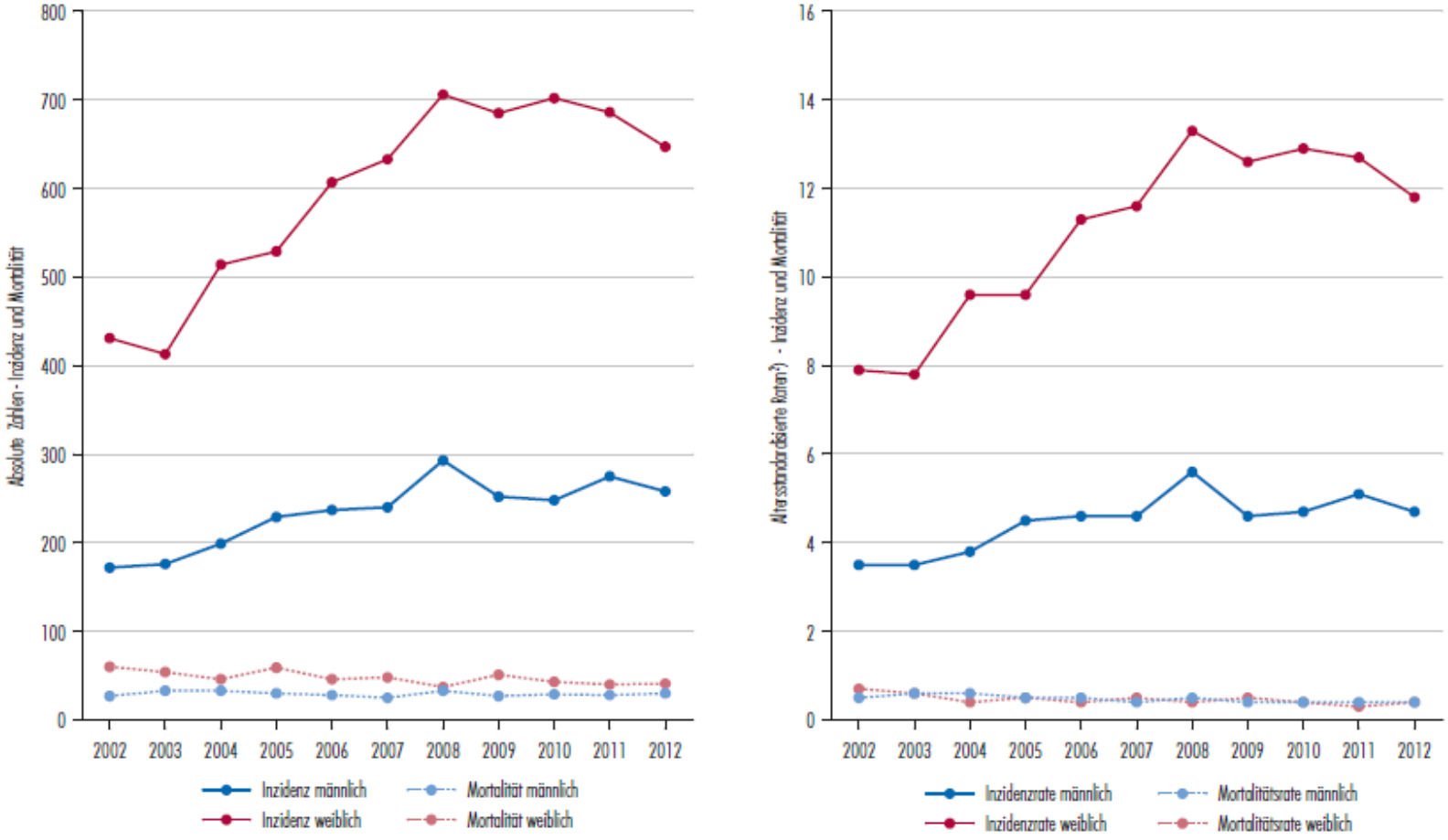

Q: STATISTIK AUSTRIA, Österreichisches Krebsregister (Stand 02.10.2015) und Todesursachenstatistik. – 1) ICD10: C73. – 2) Jeweils auf 100.000 Personen/Männer/Frauen, Standardbevölkerung = WHO-Weltbevölkerung 2001.

Regionale Unterschiede in der Inzidenz des Schilddrüsenkarzinoms in Österreich

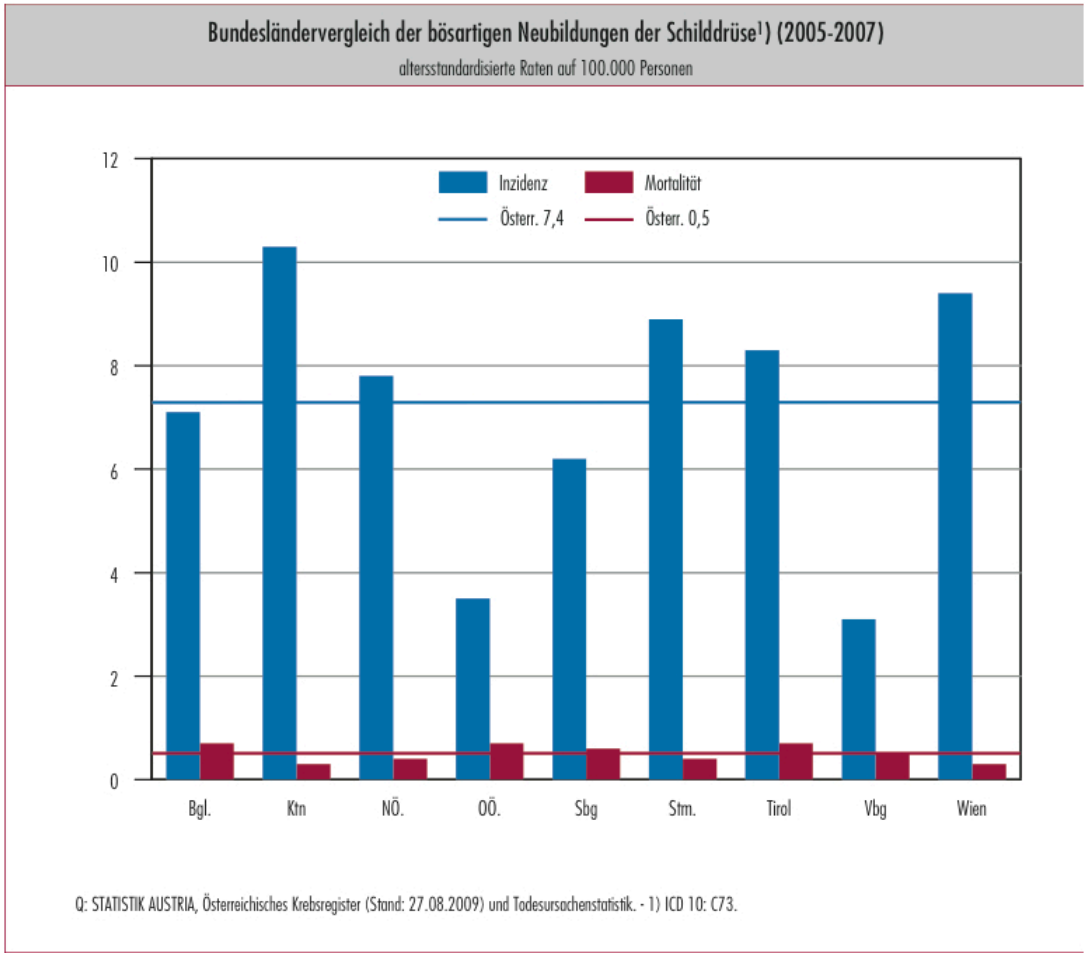

Bundesländervergleich der bösartigen Neubildungen der Schilddrüse[1]), 2010-2012

altersstandardisierte Raten auf 100.000 Männer bzw. Frauen[2])

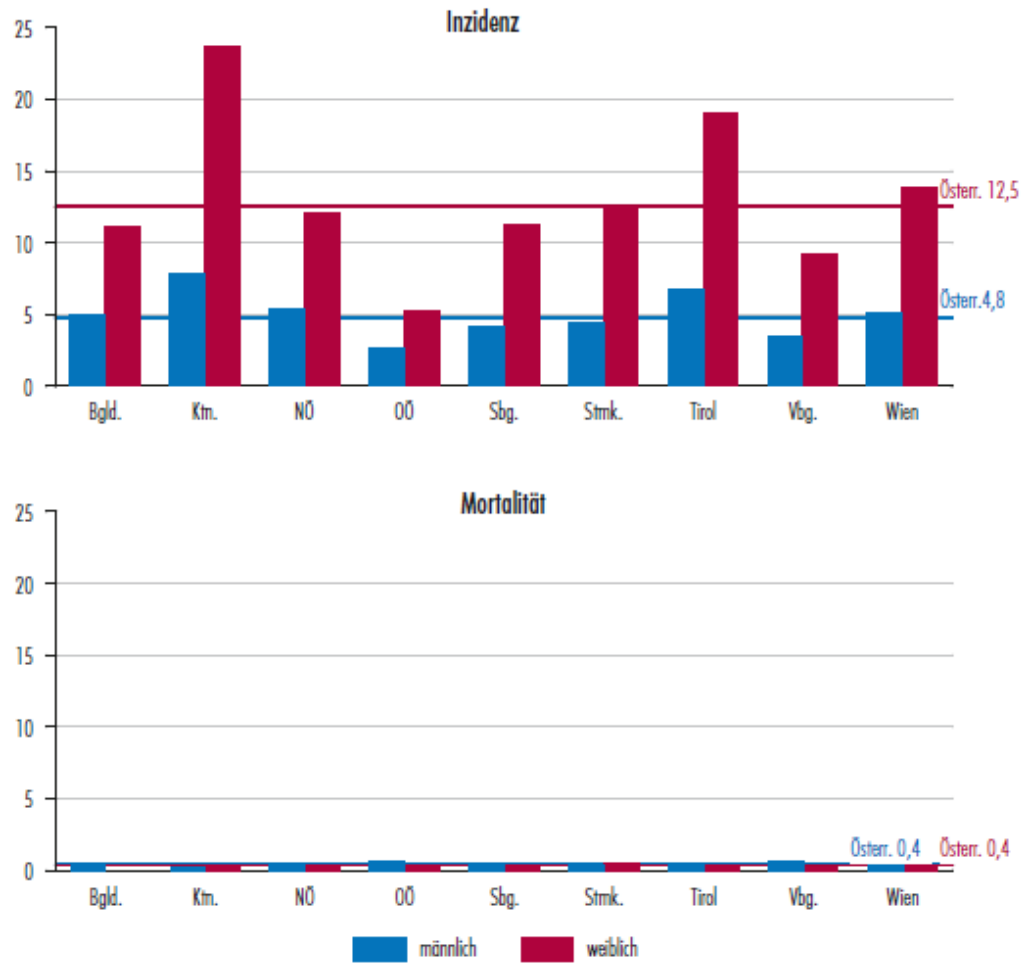

Q: STATISTIK AUSTRIA, Österreichisches Krebsregister (Stand 02.10.2015) und Todesursachenstatistik. – 1) ICD10: C73. – 2) Standardbevölkerung = WHO-Weltbevölkerung 2001.

Entwicklung der bösartigen Neubildungen der Schilddrüse[1]), Österreich ab 1992

	Inzidenz[2])						Mortalität					
	absolute Zahlen			altersstand. Raten[3])			absolute Zahlen			altersstand. Raten[3])		
	Insg.	m	w	Insg.	m	w	Insg.	m	w	Insg.	m	w
1992	351	79	272	3,5	1,8	4,9	96	27	69	0,7	0,6	0,8
1993	420	121	299	4,2	2,7	5,6	112	35	77	0,8	0,7	0,9
1994	393	134	259	3,8	2,9	4,7	117	44	73	0,8	0,9	0,8
1995	473	135	338	4,8	2,9	6,6	95	37	58	0,7	0,7	0,7
1996	422	129	293	4,1	2,8	5,3	103	52	51	0,8	1,0	0,5
1997	499	143	356	5,0	3,1	6,8	99	35	64	0,7	0,7	0,7
1998	496	134	362	4,8	2,8	6,7	125	41	84	0,9	0,8	0,9
1999	439	125	314	4,3	2,6	5,9	89	30	59	0,6	0,6	0,6
2000	546	149	397	5,4	3,1	7,5	97	30	67	0,7	0,5	0,8
2001	603	169	434	5,9	3,4	8,3	102	36	66	0,7	0,7	0,7
2002	603	172	431	5,8	3,5	7,9	87	27	60	0,6	0,5	0,7
2003	589	176	413	5,6	3,5	7,8	87	33	54	0,6	0,6	0,6
2004	713	199	514	6,7	3,8	9,6	79	33	46	0,5	0,6	0,4
2005	758	229	529	7,1	4,5	9,6	89	30	59	0,5	0,5	0,5
2006	844	237	607	8,0	4,6	11,3	74	28	46	0,5	0,5	0,4
2007	873	240	633	8,1	4,6	11,6	73	25	48	0,4	0,4	0,5
2008	999	293	706	9,5	5,6	13,3	70	33	37	0,4	0,5	0,4
2009	937	252	685	8,6	4,6	12,6	78	27	51	0,5	0,4	0,5
2010	950	248	702	8,8	4,7	12,9	72	29	43	0,4	0,4	0,4
2011	961	275	686	8,9	5,1	12,7	68	28	40	0,4	0,4	0,3
2012	905	258	647	8,3	4,7	11,8	71	30	41	0,4	0,4	0,4

Q: STATISTIK AUSTRIA, Österreichisches Krebsregister (Stand 02.10.2015) und Todesursachenstatistik. – 1) ICD10: C73. – 2) Maligne invasive Fälle, inkl. DCO-Fälle. – 3) Jeweils auf 100.000 Personen/Männer/Frauen, Standardbevölkerung = WHO-Weltbevölkerung 2001.

Histologie und Qualitätsmerkmale, Schilddrüse[1]) 2010-2012				
Histologie, ohne DCO-Fälle	männlich		weiblich	
	n	%	n	%
Insgesamt	259	100,0	672	100,0
Karzinome	255	98,5	664	98,8
Follikuläre Karzinome	35	13,7*	70	10,5*
Papilläre Karzinome	183	71,8*	543	81,8*
Medulläre Karzinome	22	8,5*	25	3,8*
Anaplastische Karzinome	7	2,6*	7	1,1*
Karzinome m. n. A.	3	1,1*	5	0,7*
Karzinome o. n. A.	6	2,4*	15	2,2*
Sarkome	1	0,3	1	0,1
Bösartige Neubildungen o. n. A.	0	0,0	0	0,0

Statistik Austria 2016

Schilddrüsenkarzinom in Deutschland

Inzidenz und Mortalität 1980 - 2004

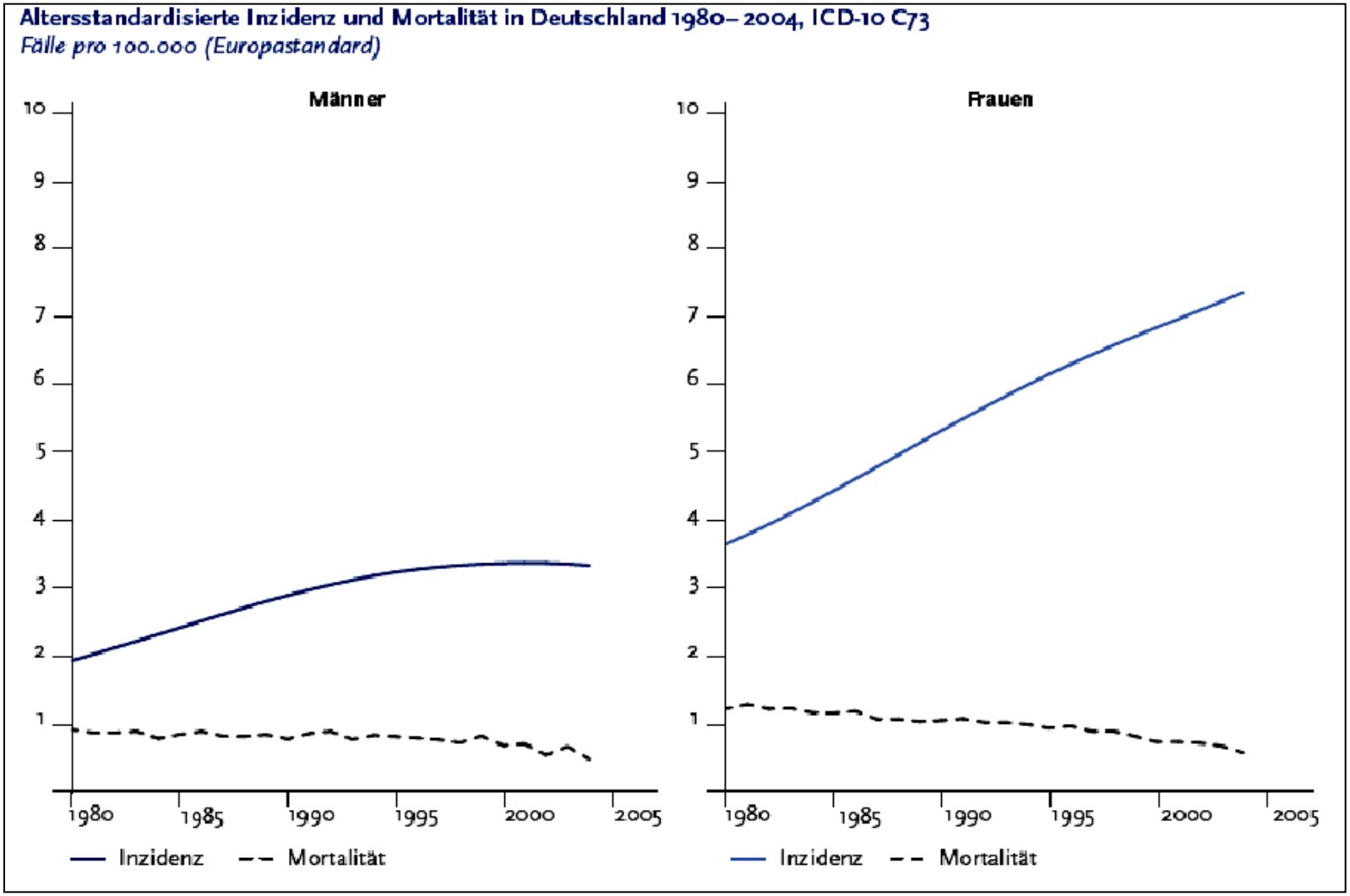

Inzidenz des Schilddrüsenkarzinoms - USA

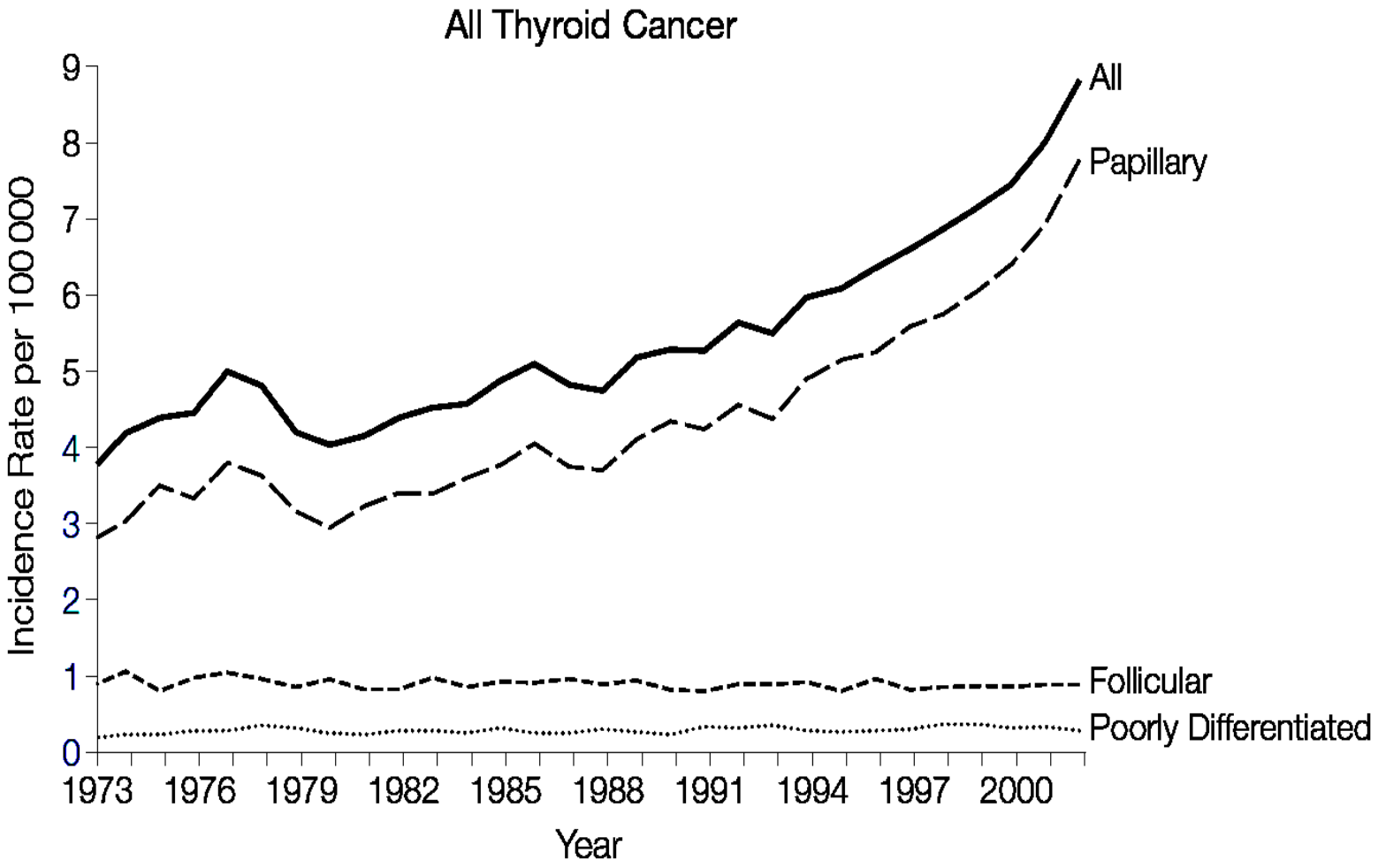

Tumortypen und Größe

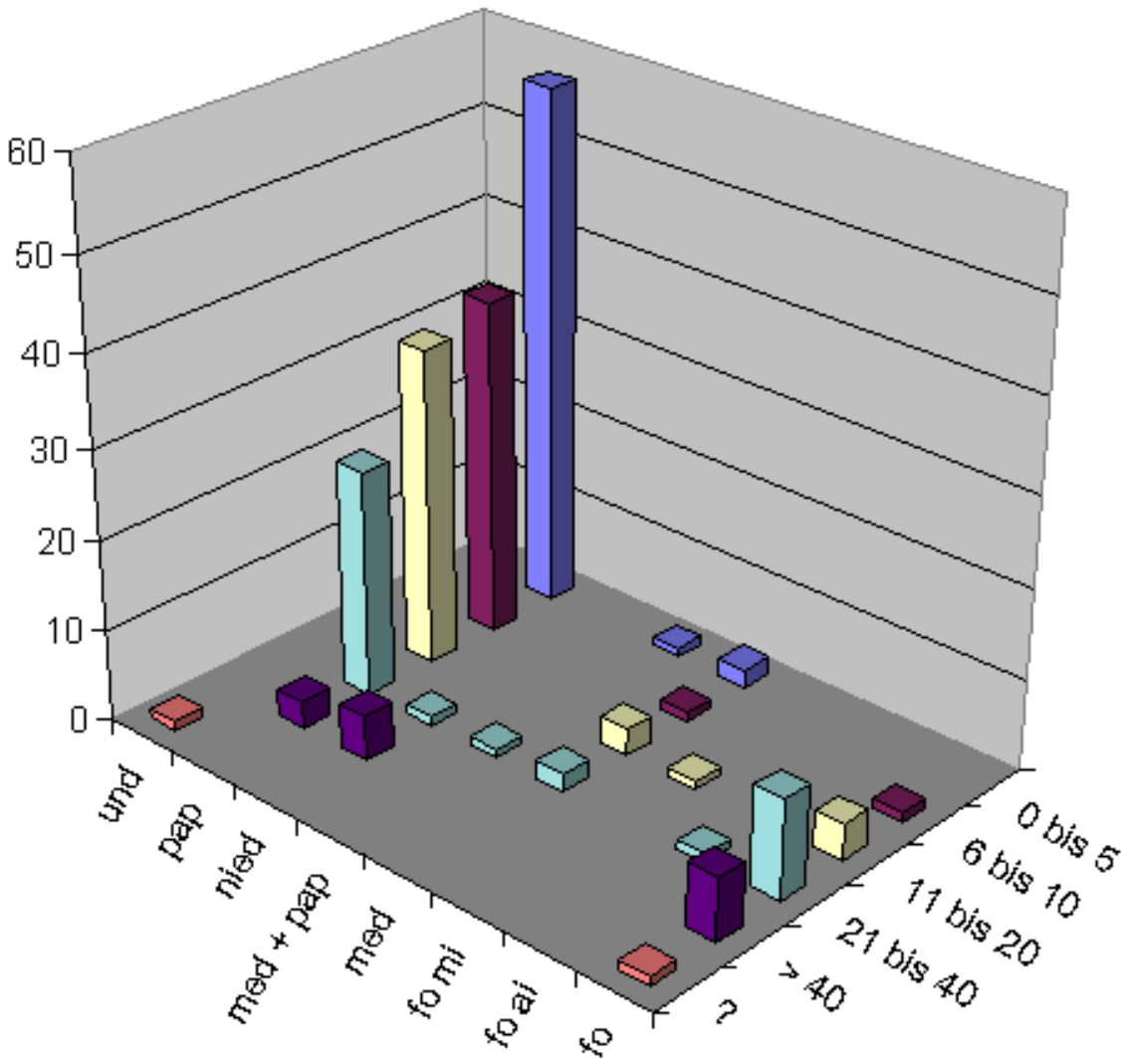

Pathologie LKH Graz Süd-West 2004-06

Zusammenfassung und Konklusion

- Neue Kategorien, Vieles bestätigt
- Neue intermediäre Kategorien und NIFT-P: therapeutische De-Eskalation
- Hürthlezell (onkozytäre) Tumoren separat
- Unterteilung des follikulären Karzinoms
- Kein wesentlicher Einfluss auf Zytologie
- Schilddrüsenkarzinome häufiger, aber Überleben verbessert

Vielen Dank!