Brauchen wir TIRADS?

Georg Zettinig
Schilddrüsenpraxis Josefstadt
1080 Wien

ÖSTERREICHISCHE SCHILDDRÜSENGESELLSCHAFT
AUSTRIAN THYROID ASSOCIATION

Was ist TIRADS?

SCHILDDRÜSENSONOGRAPHIE:

Kleine echoarme Schilddrüse. Das Echomuster inhomogen. Über dem Isthmus finden sich zwei Delphische Lymphknoten.

Ergebnis: Bild wie bei Autoimmunthyreopathie bzw. Autoimmunthyreoiditis Typ Hashimoto.
Bei fehlenden Voruntersuchung sonographische Verlaufskontrolle in 9 – 12 Monaten inkl. Labor empfehlenswert.
TIRADS 3.

Mit bestem Dank für die Zuweisung
und freundlichen Grüßen

TIRADS: Thyroid Imaging Reporting And Documentation System
TIRADS 0: Nicht beurteilbar, Untersuchung unzureichend. **TIRADS 1**: Normale Schilddrüsensonographie. **TIRADS 2**: Gutartiger Befund nahezu sicher benigen. **TIRADS 3**: Wahrscheinlich gutartiger Befund. Malignitätswahrscheinlichkeit unter 2%.
TIRADS 4a: Malignitätswahrscheinlichkeit 5 – 10%. **TIRADS 4b**: Malignitätswahrscheinlichkeit 10 – 50%
TIRADS 4c: Malignitätswahrscheinlichkeit 50 – 80%. **TIRADS 5**: Wahrscheinlich maligner Befund, Malignitätswahrscheinlichkeit über 80%. **TIRADS 6**: gesichertes Schilddrüsen-Karzinom.

ÖSTERREICHISCHE SCHILDDRÜSENGESELLSCHAFT
AUSTRIAN THYROID ASSOCIATION

Zettinig 2014

BIRADS

BI-RADS-Kategorie	Bedeutung
0	Die mammographische Untersuchung ist unvollständig. Weitere Bildgebung oder Vergleichsmammographien werden benötigt.
1	Negativ
2	Gutartiger Befund, z. B. kalzifizierte Fibroadenome, verkalkte Sekretgänge, Ölzysten, Lipome, Galaktozelen, Hamartome, Lymphknoten oder auch Implantate.
3	Vermutlich gutartiger Befund. Weniger als 2 % Malignomwahrscheinlichkeit. Kontrolluntersuchung in 6 Monaten empfohlen.
4	Verdächtiger Befund. Eine Biopsie sollte in Erwägung gezogen werden. Die Stufe 4 kann fakultativ in 4a-c (Screeningmammographie: nur 4a-b) mit steigender Malignomwahrscheinlichkeit unterteilt werden.
5	Hochverdächtig auf Malignität. Mehr als 95 % Malignomwahrscheinlichkeit. Histologische Sicherung notwendig.
6	Biopsie durchgeführt, Malignität nachgewiesen, Dokumentation vor definitiver Therapie.

Die deutsche S3-Leitlinie zur Brustkrebs-Früherkennung[3] fordert für alle BI-RADS 4 oder 5 klassifizierten Befunde eine histologische Sicherung mittels Vakuumbiopsie oder Stanzbiopsie. Unter bestimmten Voraussetzungen werden auch BI-RADS-3-Befunde biopsiert, z. B. bei Inkongruenz von Klinik und Bildgebung, bei Karzinophobie der Patientin oder entsprechendem Risikoprofil.

Quelle: www.wikipedia.org

Epidemiologie

- Prävalenz Schilddrüsenknoten: 20-50%
- Inzidenz Schilddrüsenkarzinom 11/100.000/Jahr
- In Autopsieserien bis 13% Mikrokarzinome
- Mortalitätsrate
  - Männer 0.2-1.2/100.000
  - Frauen 0.4-2.8/100.000
- Diagnostische Herausforderung: Identifizierung der Risikopatienten

ÖSTERREICHISCHE SCHILDDRÜSENGESELLSCHAFT
AUSTRIAN THYROID ASSOCIATION

Zettinig 2014

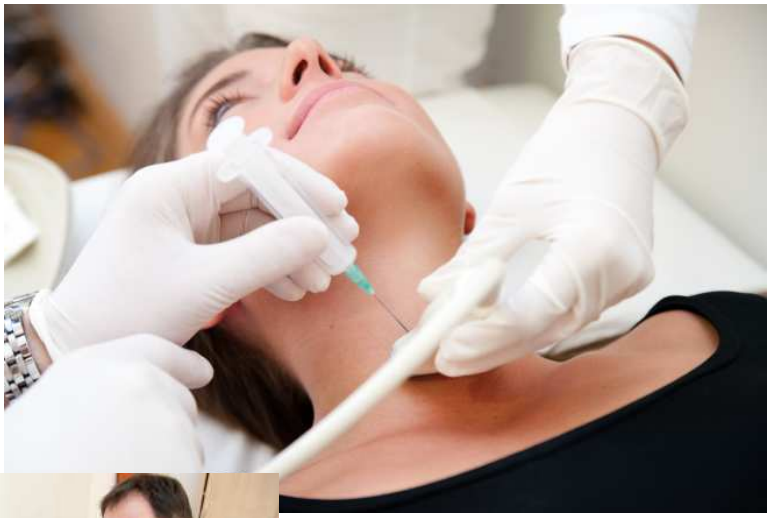

ÖSTERREICHISCHE
SCHILDDRÜSENGESELLSCHAFT
AUSTRIAN THYROID ASSOCIATION

Zettinig 2014

ORIGINAL ARTICLE

Endocrine Care—Brief Report

An Ultrasonogram Reporting System for Thyroid Nodules Stratifying Cancer Risk for Clinical Management

Eleonora Horvath, Sergio Majlis, Ricardo Rossi, Carmen Franco, Juan P. Niedmann, Alex Castro, and Miguel Dominguez

Thyroid Board (E.H., S.M., R.R., J.P.N., A.C., M.D.), Clinica Alemana de Santiago, Av. Vitacura 5951 Santiago, Chile; and Instituto de Anatomia Patologica (C.F.), Av. Manquehue Norte 1707 of. 9 Santiago, Chile

Context: There is a high prevalence of thyroid nodules on ultrasonographic (US) examination. However, most of them are benign. US criteria may help to decide cost-effective management.

Objective: Our objective was to develop a standardized US characterization and reporting data system of thyroid lesions

Design: This was
Imaging Reporti

Materials: A cor
1959 lesions bic
was divided into
stage, four TIRA
defined in the B
lignancy), TIRAD
malignancy).

Results: The TIRA
nodules (benign:
predictive value,
The ratio of beni

Conclusions: The
avoiding unnece
radiologists and

THYROID
Volume 19, Number 11, 2009

DOI: 10.1089/thy.2008.0021

THYROID RADIOLOGY AND NUCLEAR MEDICINE

A Proposal for a Thyroid Imaging Reporting and Data System for Ultrasound Features of Thyroid Carcinoma

Ji-Young Park,[1] Hui Joong Lee,[2] Han Won Jang,[3] Ho Kyun Kim,[4] Jae Hyuck Yi,[2] Wonho Lee,[2] and Seong Hun Kim[5]

Background: Several thyroid ultrasound (TUS) findings have been associated with an increased risk for thyroid cancer; however, there is no consensus as to the format and style for reporting the results of TUS. The objective of this study was to discover the features indicative of malignancy in thyroid nodules based on TUS, generate an equation using these features that would be predictive of malignancy in thyroid nodules, and stratify the results of this equation into TUS categories reflecting the probability of malignancy.

ÖSTERREICHISCHE SCHILDDRÜSENGESELLSCHAFT
AUSTRIAN THYROID ASSOCIATION

Zettinig 2014

Horvath et al., 2009, JCEM

- Korrelation US und FNP in 1.959 histologisch ausgewerteten Herdbefunden

- Phase 1: Definition von 10 US Muster

ORIGINAL ARTICLE

Endocrine Care—Brief Report

An Ultrasonogram Reporting System for Thyroid Nodules Stratifying Cancer Risk for Clinical Management

Eleonora Horvath, Sergio Majlis, Ricardo Rossi, Carmen Franco, Juan P. Niedmann, Alex Castro, and Miguel Dominguez

Thyroid Board (E.H., S.M., R.R., J.P.N., A.C., M.D.), Clinica Alemana de Santiago, Av. Vitacura 5951 Santiago, Chile; and Instituto de Anatomia Patologica (C.F.), Av. Manquehue Norte 1707 of. 9 Santiago, Chile

Context: There is a high prevalence of thyroid nodules on ultrasonographic (US) examination. However, most of them are benign. US criteria may help to decide cost-effective management.

Objective: Our objective was to develop a standardized US characterization and reporting data system of thyroid lesions for clinical management: the Thyroid Imaging Reporting and Data System (TIRADS)

ÖSTERREICHISCHE SCHILDDRÜSENGESELLSCHAFT
AUSTRIAN THYROID ASSOCIATION

Horvath et al., 2009, JCEM - Phase 1

- Bei 362 Herdefunden FNP.
  - Anschließend der FNP Ausstrich vom Objektträger entfernt
  - In Formalin aufgelöst
  - In Paraffin eingebettet
  - Histologische Schnitte
- "Histologie" wurde in 3 Gruppen unterteilt:
  - Benigne, indeterminate/suspekt (follikuläre Läsion), maligne

Horvath et al., 2009, JCEM - Phase 2

- Definition von 4 TIRADS Gruppen "according to risk"
- Malignitätshäufigkeit der 4 Gruppen wurde von BIRADS übernommen
  - Tirads 2: 0% Malignität
  - Tirads 3: < 5% Malignität
  - Tirads 4: 5-80% Malignität
  - Tirads 5: > 80% Malignität

Horvath et al., 2009, JCEM - Phase 3

- Evaluation der Kriterien bei 1097 Knoten
  - Benigne: 703
  - Follikuläre Läsion: 238
  - Maligne: 156
- Sens. 88%, Spez. 49%
- PPV 88%, NPV 94%
- Aber Achtung: FNP im Follow up nur bei jenen Knoten bei denen der experienced radiologist der Meinung war, eine FNP sei indiziert.

Conclusion der Autoren

- TIRADS verbessert das Patientenmanagement
- TIRADS erhöht die Kosteneffizienz
- Vermeidung unnötiger Feinnadelpunktionen
- Es wurde ein Standard etabliert.

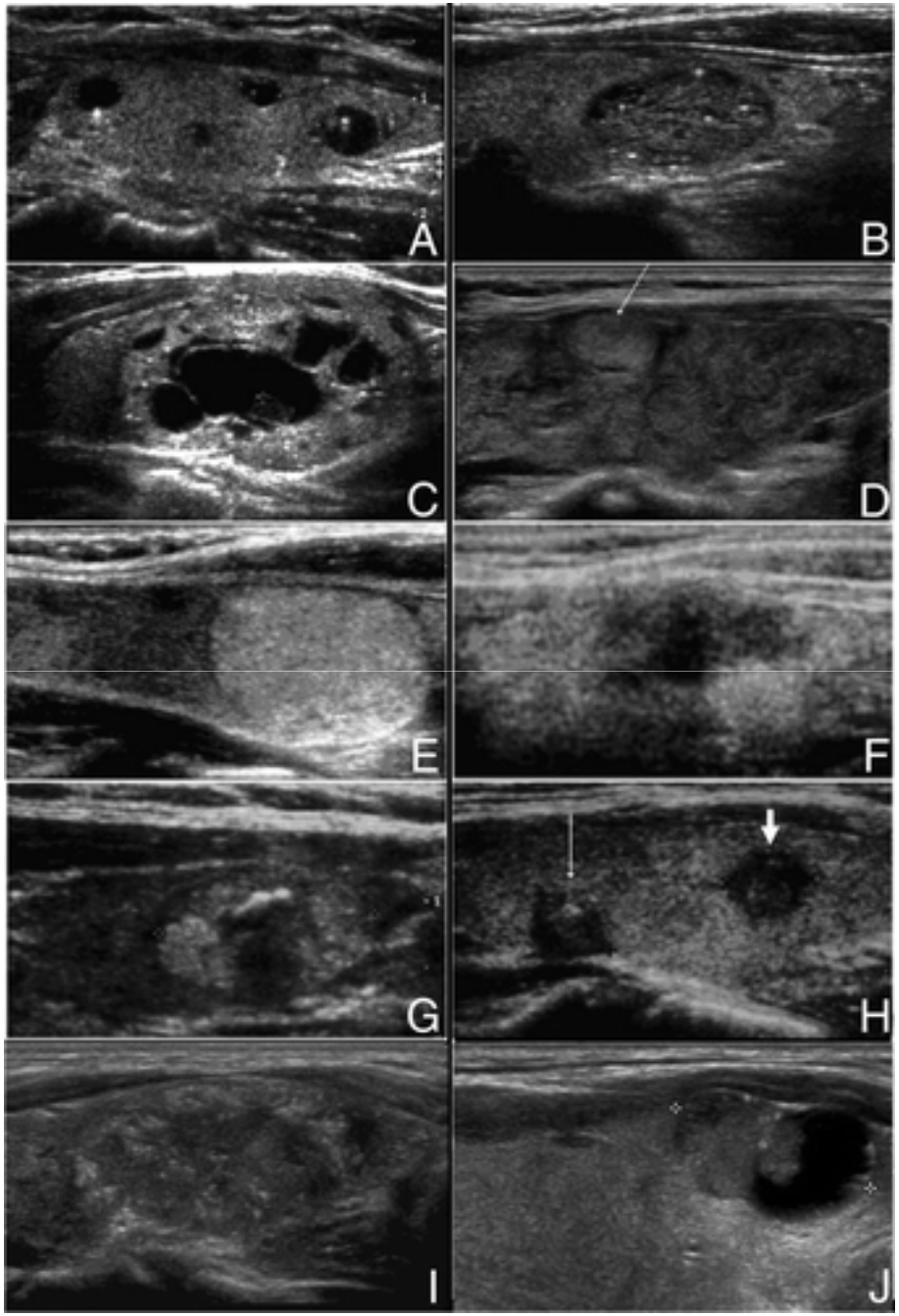

J Clin Endocrinol Metab 2009, 90 (5): 1748-1751

Zettinig 2014

ÖSTERREICHISCHE SCHILDDRÜSENGESELLSCHAFT
AUSTRIAN THYROID ASSOCIATION

TABLE 1. US characteristics of thyroid nodules, 10 US patterns with their malignancy risk, and TIRADS category

Description of US pattern	US patterns	Malignancy	TIRADS
Anechoic with hyperechoic spots, nonvascularized lesion.	Colloid type 1		
Nonencapsulated, mixed, nonexpansile, with hyperechoic spots, vascularized lesion, "grid" aspect (spongiform nodule).	Colloid type 2	0%	TIRADS 2: benign findings
Nonencapsulated, mixed with solid portion, isoechogenic, expansile, vascularized nodule with hyperechoic spots.	Colloid type 3		
Hyper, iso, or hypoechoic, partially encapsulated nodule with peripheral vascularization, in Hashimoto's thyroiditis.	Hashimoto pseudo-nodule	<5%	TIRADS 3: probably benign
Solid or mixed hyper, iso, or hypoechoic nodule, with a thin capsule.	Simple neoplastic pattern	5–10%	TIRADS 4A: undetermined
Hypoechoic lesion with ill-defined borders, without calcifications.	de Quervain pattern		
Hyper, iso, or hypoechoic, hypervascularized, encapsulated nodule with a thick capsule, containing calcifications (coarse or microcalcifications).	Suspicious neoplastic pattern		
Hypoechoic, nonencapsulated nodule, with irregular shape and margins, penetrating. vessels, with or without calcifications	Malignant pattern A	10–80%	TIRADS 4B: suspicious
Iso or hypoechoic, nonencapsulated nodule with multiple peripheral microcalcifications and hypervascularization.	Malignant pattern B	>80%	TIRADS 5: consistent with malignancy
Nonencapsulated, isoechoic mixed hypervascularized nodule with or without calcifications, without hyperechoic spots.	Malignant pattern C Cancer, confirmed by previous biopsy	100%	TIRADS 6: malignant

J Clin Endocrinol Metab 2009, 90 (5): 1748-1751

ÖSTERREICHISCHE SCHILDDRÜSENGESELLSCHAFT
AUSTRIAN THYROID ASSOCIATION

Zettinig 2014

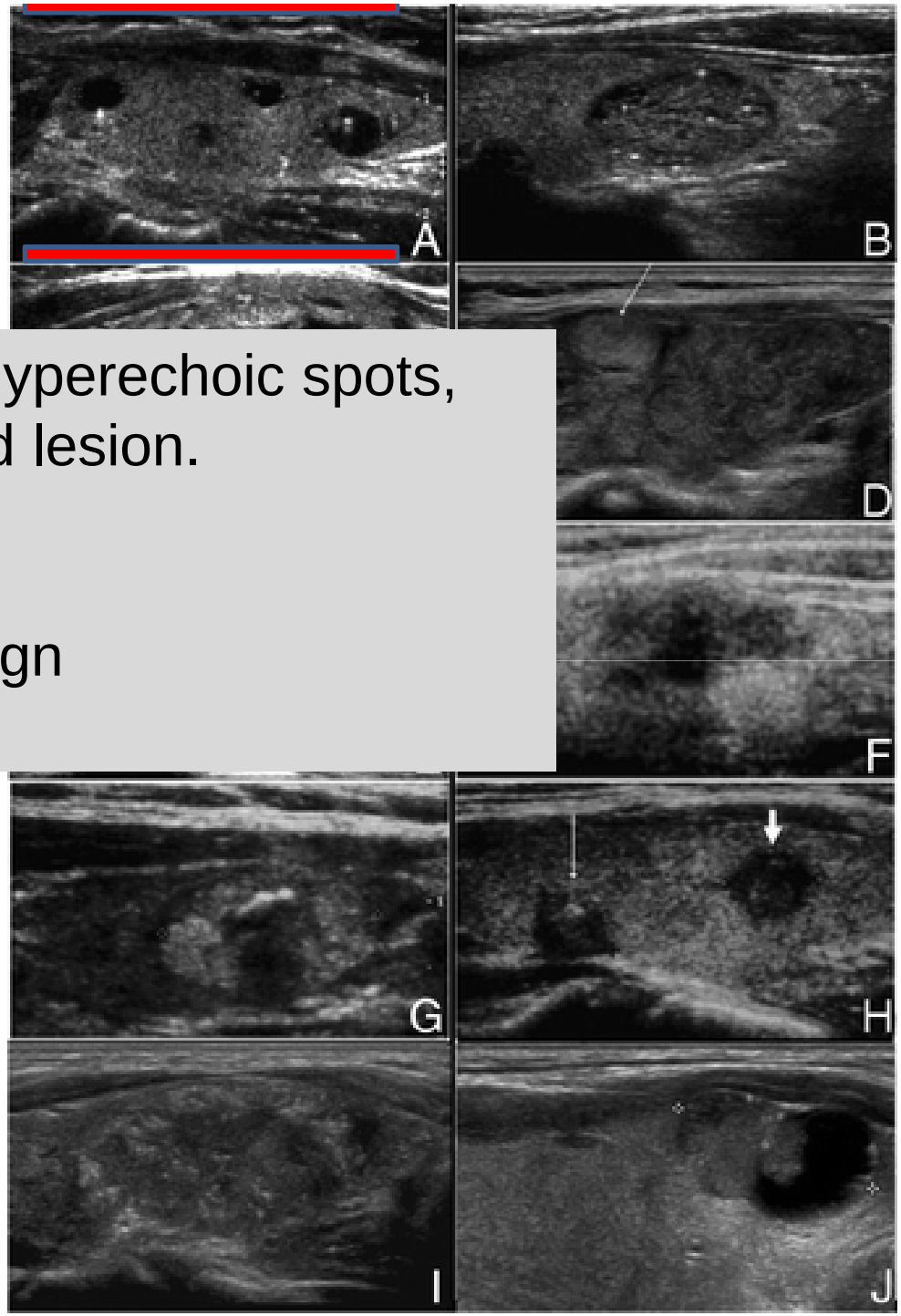

Anechoic with hyperechoic spots, nonvascularized lesion.
Colloid type 1
Malignancy 0%
TIRADS 2: benign
Fig. A

J Clin Endocrinol Metab 2009, 90 (5): 1748-1751

ÖSTERREICHISCHE SCHILDDRÜSENGESELLSCHAFT
AUSTRIAN THYROID ASSOCIATION

Zettinig 2014

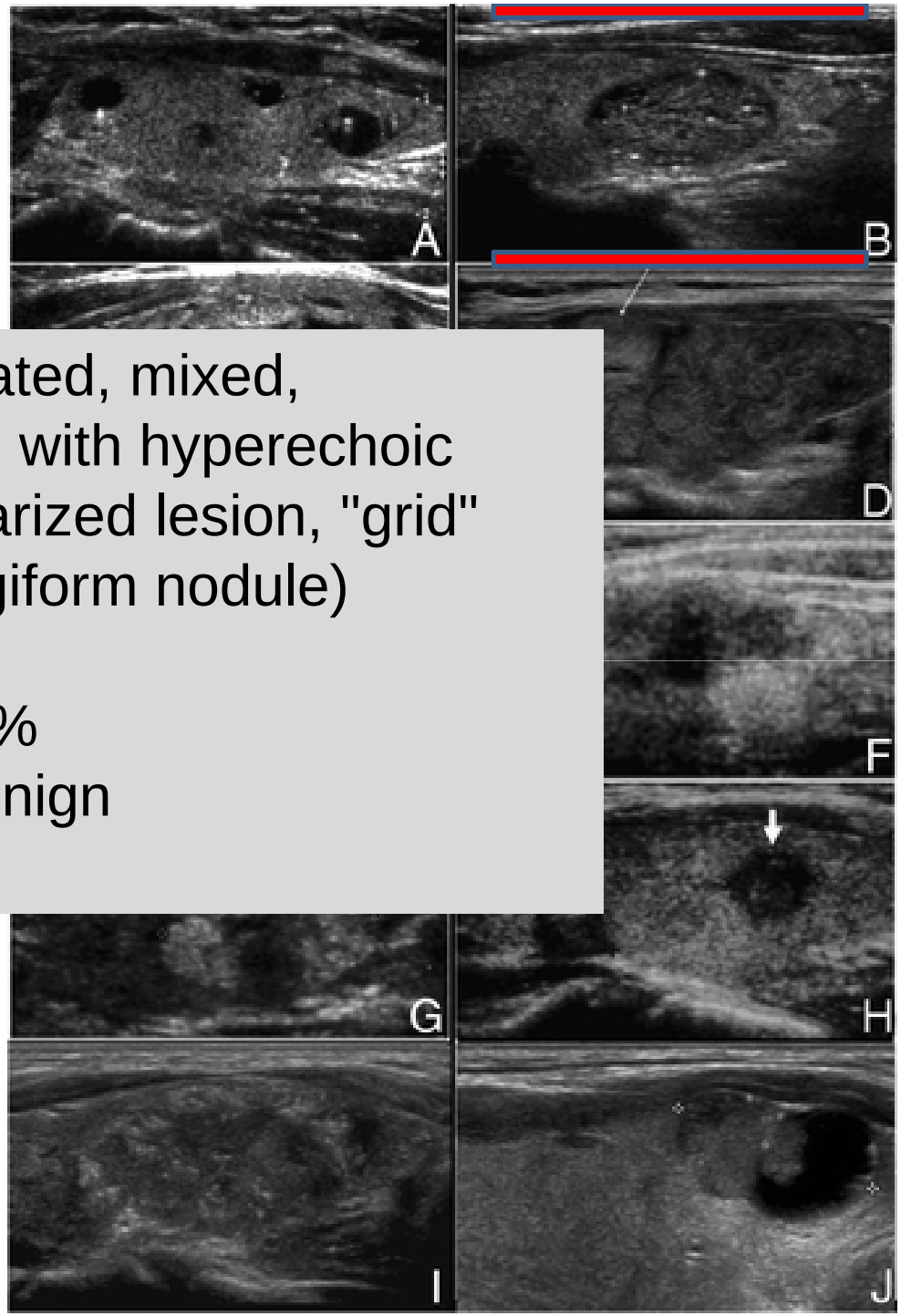

Nonencapsulated, mixed, nonexpansile, with hyperechoic spots, vascularized lesion, "grid" aspect (spongiform nodule)
Colloid type 2
Malignancy 0%
TIRADS 2: benign
Fig. B

J Clin Endocrinol Metab 2009, 90 (5): 1748-1751

ÖSTERREICHISCHE SCHILDDRÜSENGESELLSCHAFT
AUSTRIAN THYROID ASSOCIATION

Zettinig 2014

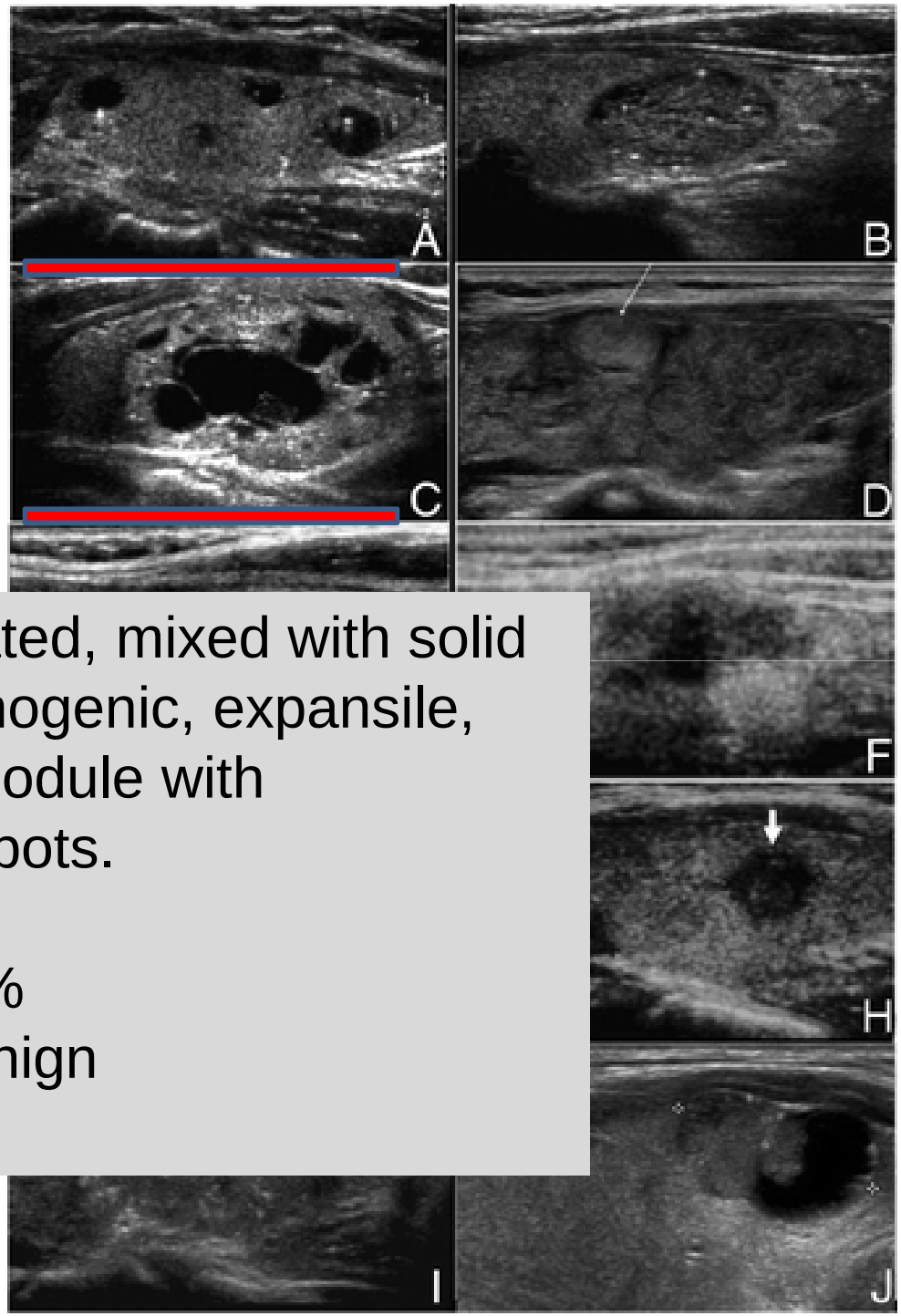

Nonencapsulated, mixed with solid portion, isoechogenic, expansile, vascularized nodule with hyperechoic spots.
Colloid type 3
Malignancy 0%
TIRADS 2: benign
Fig. C

J Clin Endocrinol Metab 2009, 90 (5): 1748-1751

ÖSTERREICHISCHE SCHILDDRÜSENGESELLSCHAFT
AUSTRIAN THYROID ASSOCIATION

Zettinig 2014

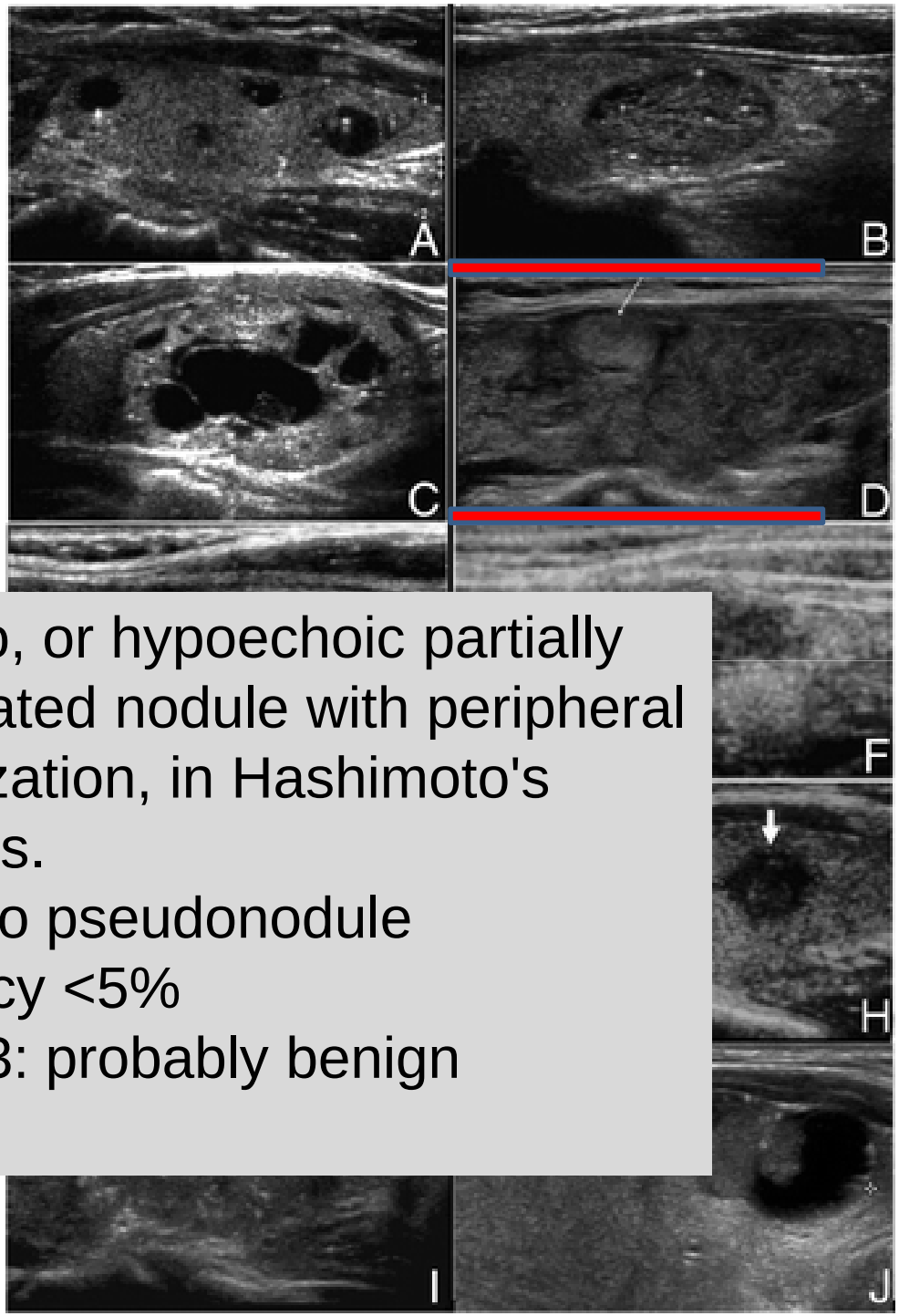

Hyper, iso, or hypoechoic partially encapsulated nodule with peripheral vascularization, in Hashimoto's thyreoiditis.
Hashimoto pseudonodule
Malignancy <5%
TIRADS 3: probably benign
Fig. D

J Clin Endocrinol Metab 2009, 90 (5): 1748-1751

ÖSTERREICHISCHE SCHILDDRÜSENGESELLSCHAFT
AUSTRIAN THYROID ASSOCIATION

Zettinig 2014

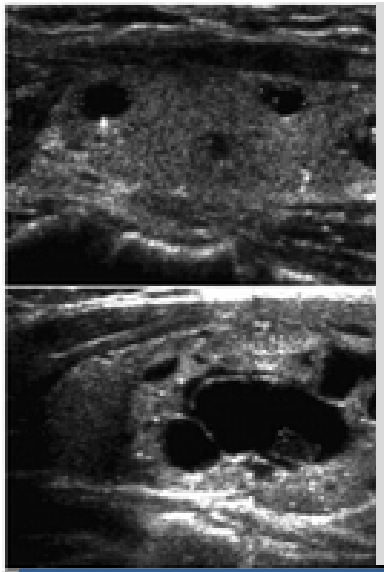

Solid or mixed hyper iso or hypooechoic nodule with a thin capsule.
Simple neoplastic pattern
Malignancy 5-10%
TIRADS 4A: undetermined
Fig. E

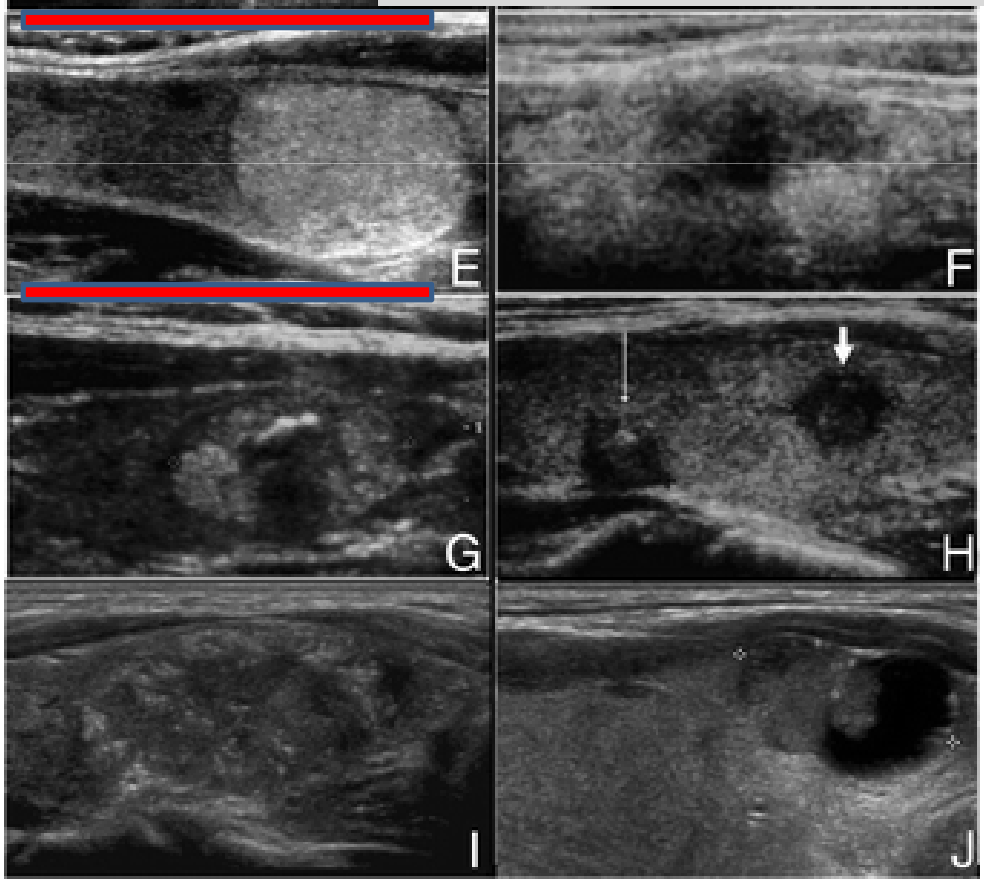

J Clin Endocrinol Metab 2009, 90 (5): 1748-1751

Zettinig 2014

ÖSTERREICHISCHE SCHILDDRÜSENGESELLSCHAFT
AUSTRIAN THYROID ASSOCIATION

Hypoechoic lesion with ill-defined borders, without calcifications
de Quervain pattern
Malignancy 5-10%
TIRADS 4A: undetermined
Figure F

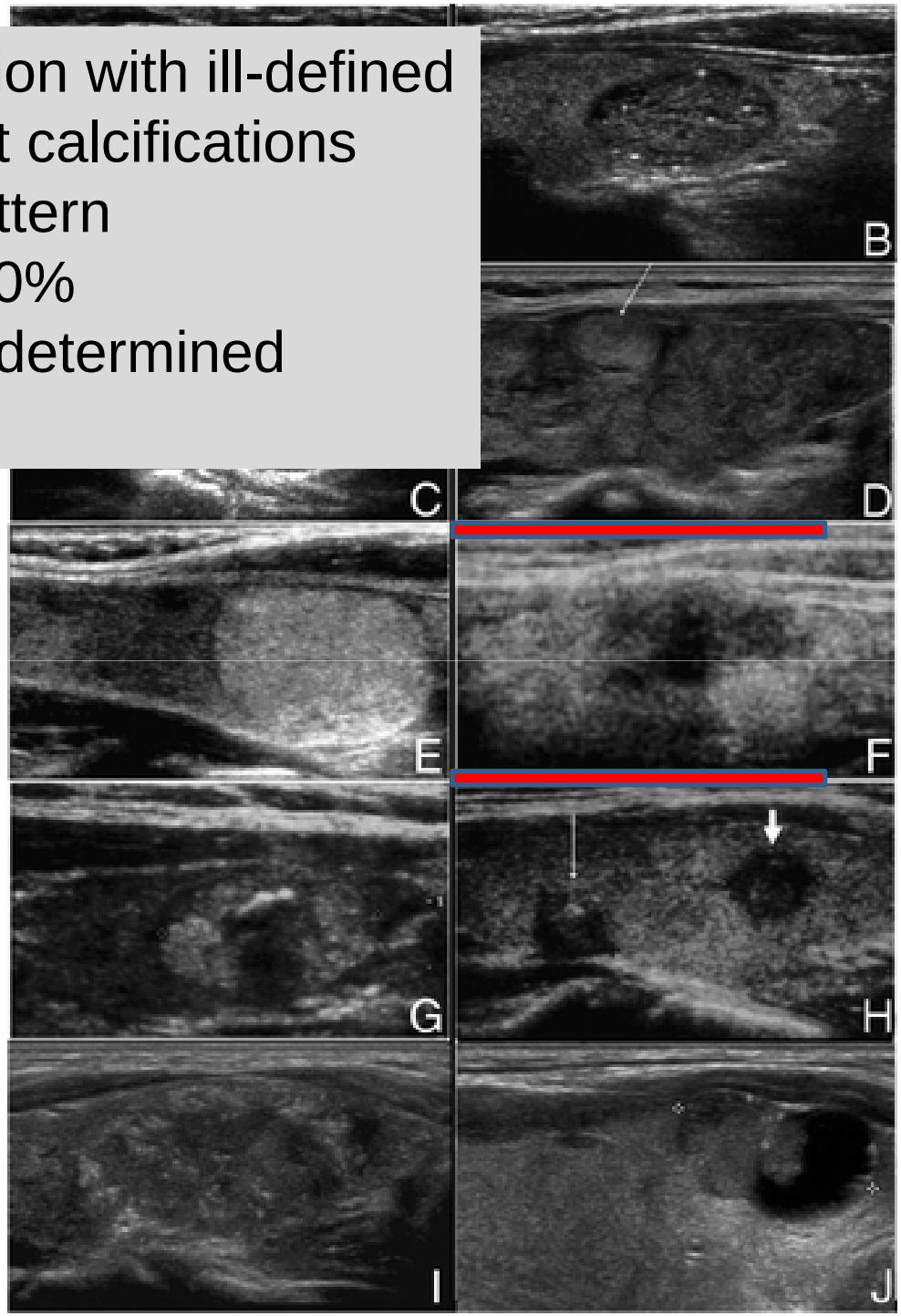

J Clin Endocrinol Metab 2009, 90 (5): 1748-1751

Zettinig 2014

ÖSTERREICHISCHE SCHILDDRÜSENGESELLSCHAFT
AUSTRIAN THYROID ASSOCIATION

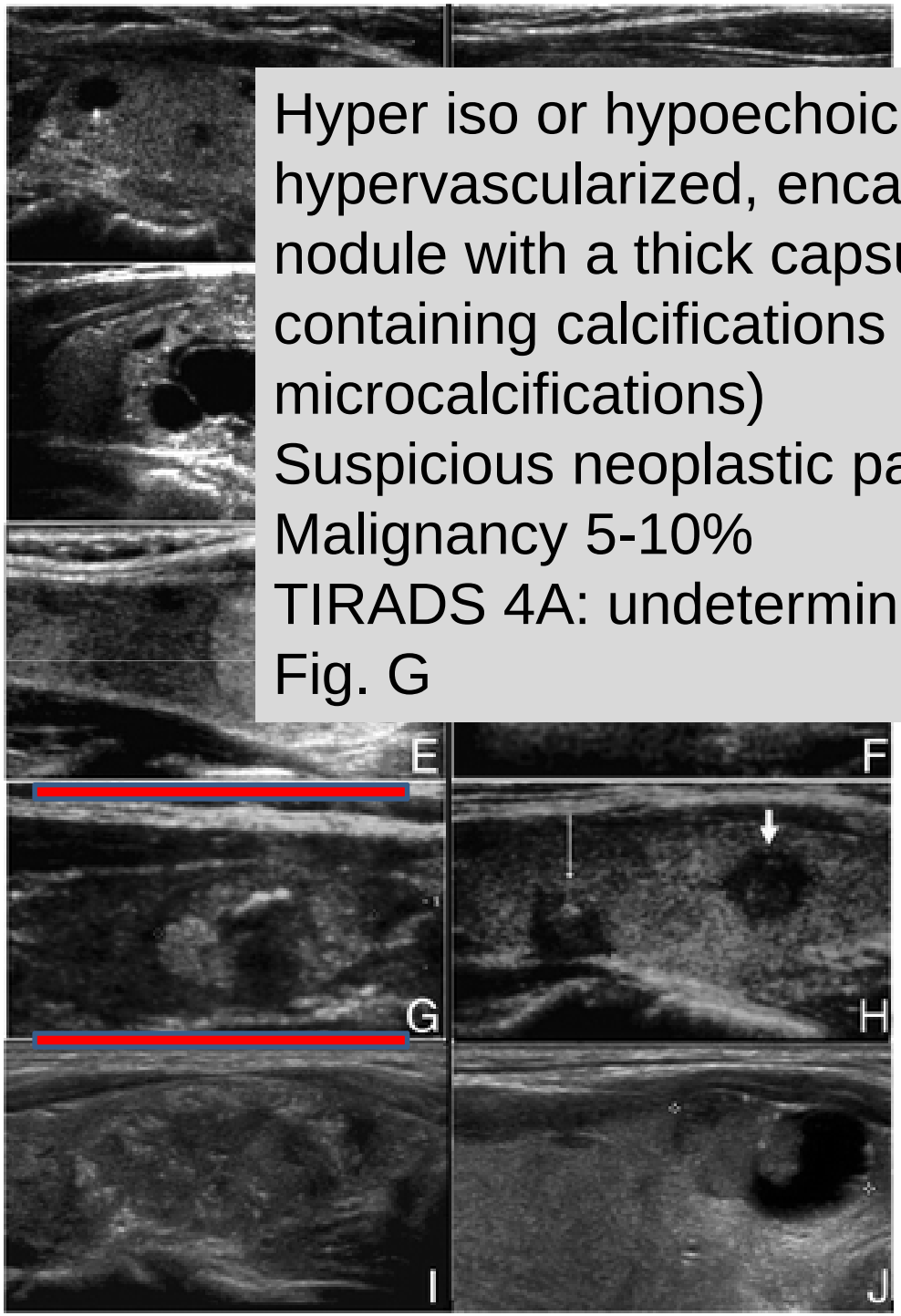

Hyper iso or hypoechoic, hypervascularized, encapsulated nodule with a thick capsule, containing calcifications (coarse or microcalcifications)
Suspicious neoplastic pattern
Malignancy 5-10%
TIRADS 4A: undetermined
Fig. G

J Clin Endocrinol Metab 2009, 90 (5): 1748-1751

Zettinig 2014

ÖSTERREICHISCHE SCHILDDRÜSENGESELLSCHAFT
AUSTRIAN THYROID ASSOCIATION

Hypoechoic, nonencapsulated nodule, with irregular shape and margins, penetrating vessels, with or without calcifications
Malignant pattern A
Malignancy 10-80%
TIRADS 4B: suspicious
Fig. H

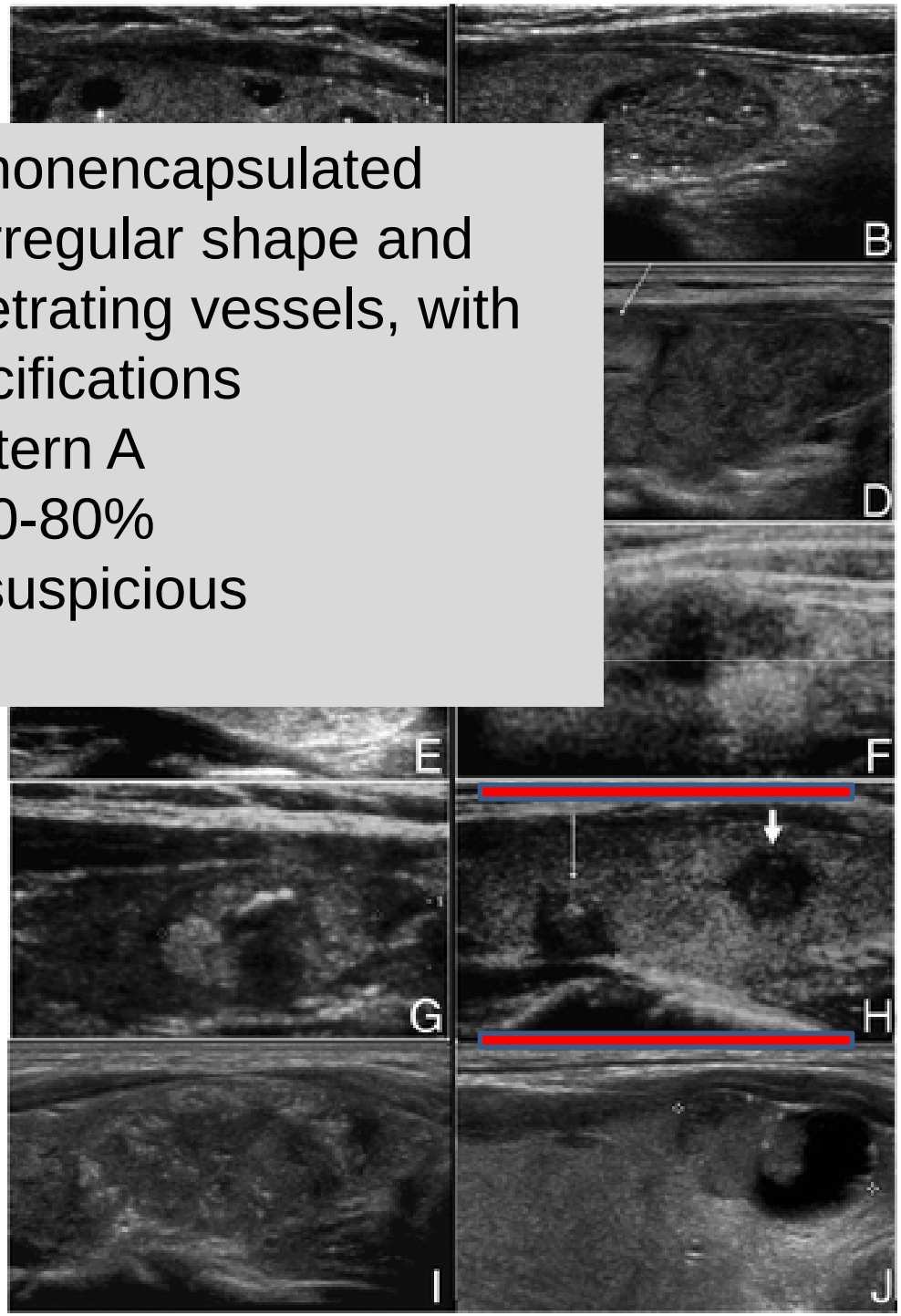

J Clin Endocrinol Metab 2009, 90 (5): 1748-1751

ÖSTERREICHISCHE SCHILDDRÜSENGESELLSCHAFT
AUSTRIAN THYROID ASSOCIATION

Zettinig 2014

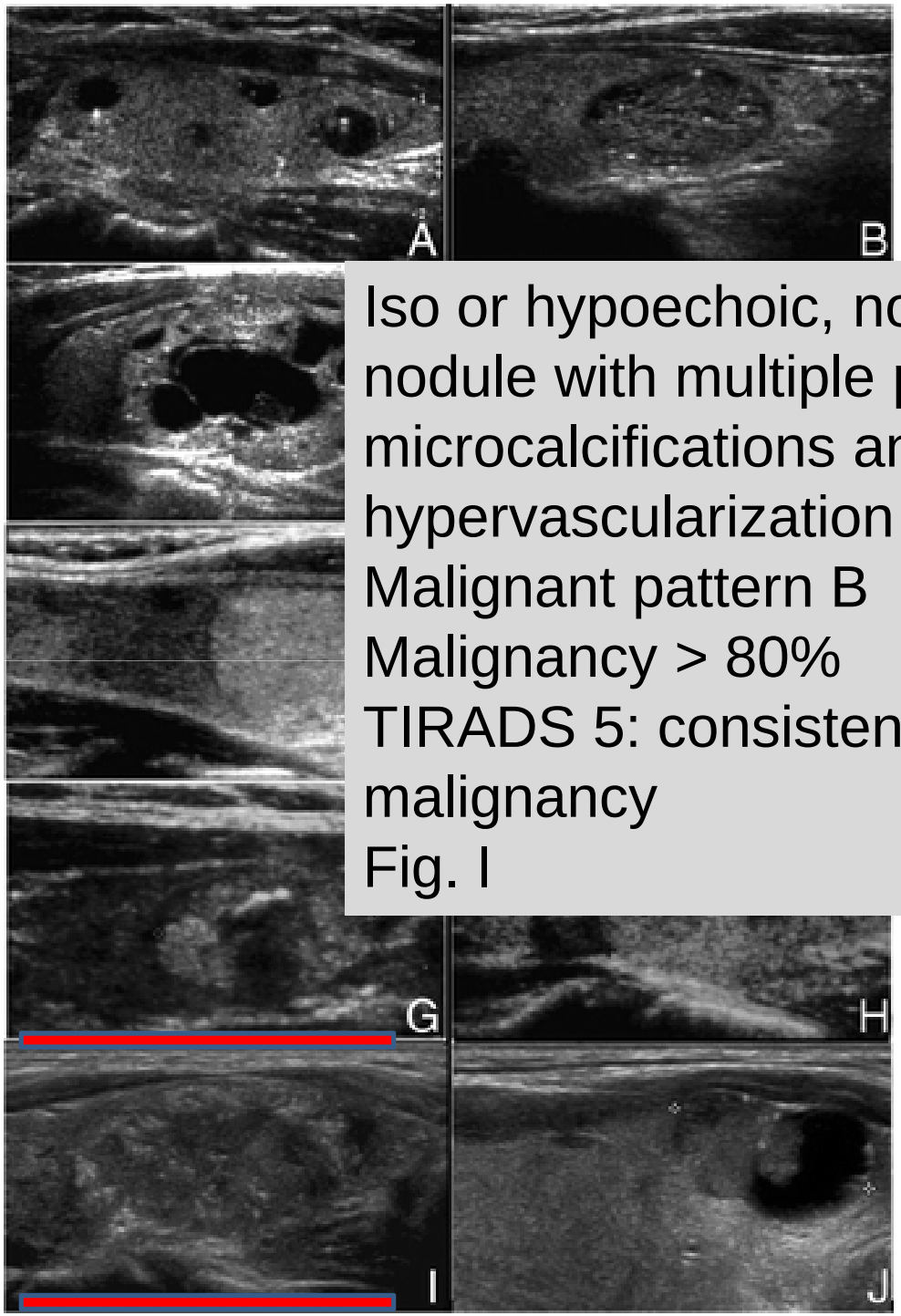

Iso or hypoechoic, nonencapsulated nodule with multiple peripheral microcalcifications and hypervascularization
Malignant pattern B
Malignancy > 80%
TIRADS 5: consistent with malignancy
Fig. I

J Clin Endocrinol Metab 2009, 90 (5): 1748-1751

Zettinig 2014

ÖSTERREICHISCHE SCHILDDRÜSENGESELLSCHAFT
AUSTRIAN THYROID ASSOCIATION

Nonencapsulated isoechoic mixed hypervascularized nodule with or without calcifications without hyperechoic spots.
Malignant pattern C: Cancer confirmed by previous biopsy
Malignancy 100%
TIRADS 6: malignant
Figure J

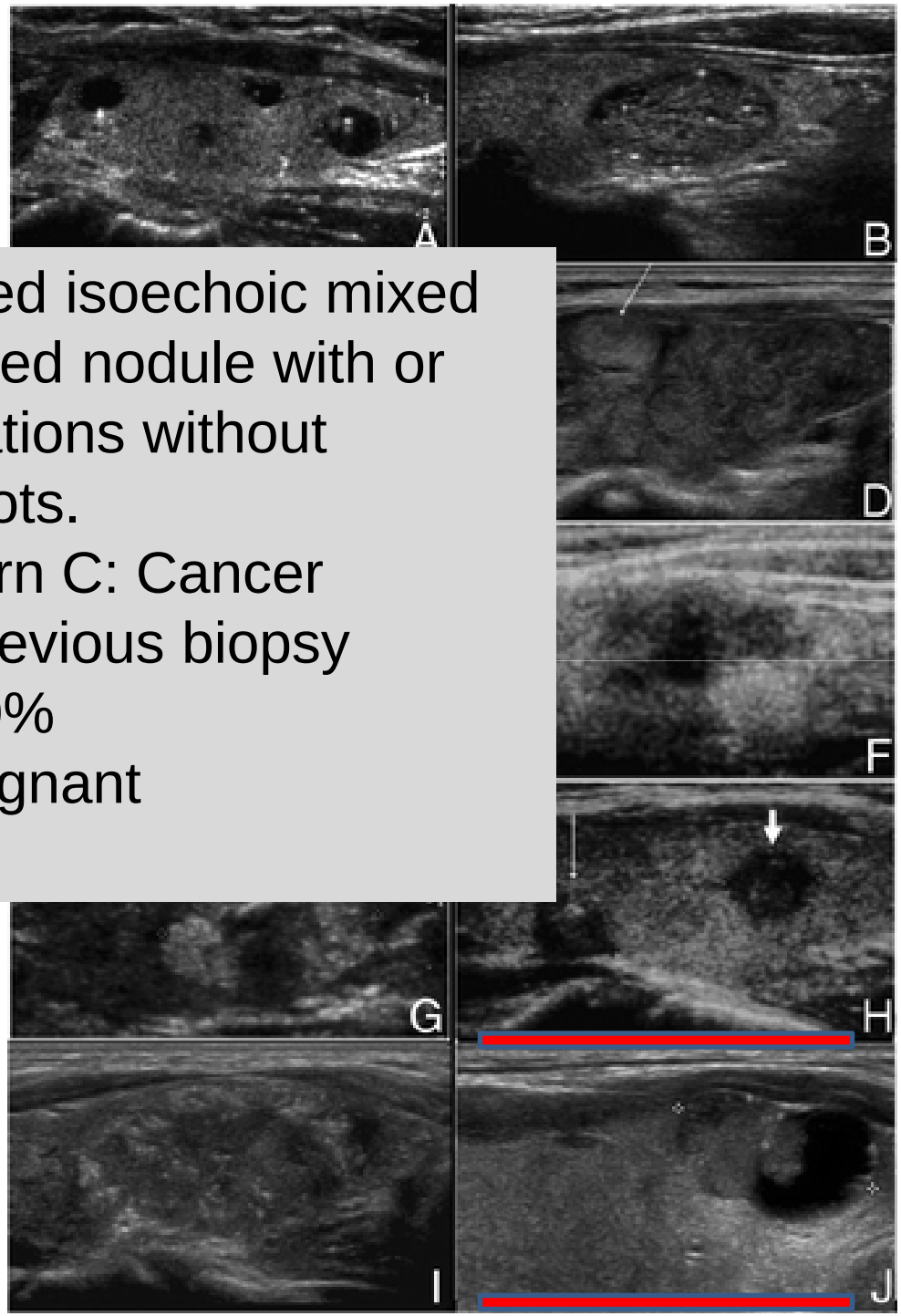

J Clin Endocrinol Metab 2009, 90 (5): 1748-1751

ÖSTERREICHISCHE SCHILDDRÜSENGESELLSCHAFT
AUSTRIAN THYROID ASSOCIATION

Zettinig 2014

ORIGINAL ARTICLE

Endocrine Care—Brief Report

An Ultrasonogram Reporting System for Thyroid Nodules Stratifying Cancer Risk for Clinical Management

Eleonora Horvath, Sergio Majlis, Rica
Alex Castro, and Miguel Dominguez

Thyroid Board (E.H., S.M., R.R., J.P.N., A.C., M.D
and Instituto de Anatomia Patologica (C.F.), Av.

Context: There is a high prevalence o
However, most of them are benign. US

Objective: Our objective was to develop a
of thyroid lesions for clinical managemer

Design: This was a prospective study usi
Imaging Reporting Data System of the

Materials: A correlation of the US finc
1959 lesions biopsied under US guid
was divided into three stages. In the
stage, four TIRADS groups were defi
defined in the Breast Imaging Report
lignancy), TIRADS 3 (<5% malignanc
malignancy).

Results: The TIRADS classification was e
nodules (benign: 703; follicular lesions
predictive value, negative predictive val
The ratio of benign to malignant or fo

Conclusions: The TIRADS has allowed u
avoiding unnecessary FNAB. In additio
radiologists and endocrinologists. (J Cl

THYROID
Volume 19, Number 11, 2009

DOI: 10.1089/thy.2008.0021

A Proposal for a Thyroid Imaging Reporting and Data System for Ultrasound Features of Thyroid Carcinoma

Ji-Young Park,[1] Hui Joong Lee,[2] Han Won Jang,[3] Ho Kyun Kim,[4] Jae Hyuck Yi,[2] Wonho Lee,[2] and Seong Hun Kim[5]

Background: Several thyroid ultrasound (TUS) findings have been associated with an increased risk for thyroid cancer; however, there is no consensus as to the format and style for reporting the results of TUS. The objective of this study was to discover the features indicative of malignancy in thyroid nodules based on TUS, generate an equation using these features that would be predictive of malignancy in thyroid nodules, and stratify the results of this equation into TUS categories reflecting the probability of malignancy.
Methods: We obtained odds ratios of TUS findings indicative of malignancy and probability of malignancy for each nodule as determined by logistic regression analysis of ultrasound (US) findings in 1694 patients who had US-guided fine-needle aspiration biopsy. We then generated an equation to predict the probability of malignancy based on TUS and developed categories ranging from lowest to highest probability of malignancy. We evaluated the reliability of this equation and the categories using cytology and histopathology information regarding malignancy in the thyroid nodules.
Results: We characterized 12 aspects of thyroid nodules as seen on TUS and developed an equation to predict P^{us}, the probability of a nodule being malignant based on these US findings. The equation was $P^{us} = 1/(1+e^{-z})$, where e is the mathematical constant 2.71828 and z is the logit of malignant thyroid nodule. P^{us} was stratified into five categories based on the probability of a nodule being malignant as indicated by the findings (TUS 1, benign; TUS 2, probably benign; TUS 3, indeterminate; TUS 4, probably malignant; TUS 5, malignant). There was a significant correlation between the cytological category and the TUS 1 through TUS 5 categories ($r = 0.491$, $p < 0.001$).
Conclusions: We propose an equation to predict the probability of malignancy in thyroid nodules based on 12 features of thyroid nodules as noted on TUS. This equation, and the stratification of its results into categories, should be useful in reporting the findings of US for thyroid nodules and in guiding management decisions.

Introduction

THE INCREASED USE OF HIGH-RESOLUTION ULTRASOUND (US) for thyroid disease has markedly increased the discovery of small nonpalpable thyroid nodules. These nodules present a clinical dilemma as there is uncertainty regarding how they should be managed (1–3). Although nodules less

US is useful in detecting a focal lesion, determining whether a lesion is cystic or solid, and guiding USG-FNAB. Several US findings are associated with an increased risk for thyroid cancer (6–8). These include calcifications, hypoechogenecity, irregular margins, absence of a halo, predominantly solid composition, and intranodule vascularity (6,7,9–13). However, the sensitivities, specificities, and negative and

ÖSTERREICHISCHE SCHILDDRÜSENGESELLSCHAFT
AUSTRIAN THYROID ASSOCIATION

Methoden

- Retrospektiv
- 5 1/2 Jahre
- 2679 Patienten

9 Kriterien für Univarianzanalyse

- Struma
- Tiefendurchmesser
- Form (Ratio a.p. zu transversal, Tallness>1)
- Rand (Halo, Begrenzung, Mikrolobuli, Infiltr.)
- Echogenität (an/deutlich hypo/hypo/iso/hyper)
- Echotextur (homogen/inhomogen)
- Zusammens. (vorw. solid, vorw. zystisch, solid)
- Kalk (Mikrokalk, Makrokalk, Eierschale)
- Lymphkoten (Lymphadenopathie)

9 Kriterien für Univarianzanalyse

- Struma
- Tiefendurchmesser
- Form (Ratio a.p. zu transversal, Tallness>1)
- Rand (Halo, Begrenzung, Mikrolobuli, Infiltr.)
- Echogenität (an/deutlich hypo/hypo/iso/hyper)
- Echotextur (homogen/inhomogen)
- Zusammens. (vorw. solid, vorw. zystisch, solid)
- Kalk (Mikrokalk, Makrokalk, Eierschale)
- Lymphkoten (Lymphadenopathie)

9 Kriterien für Univarianzanalyse

- Struma
- Tiefendurchmesser
- Form (Ratio a.p. zu transversal, Tallness>1)
- Rand (Halo, Begrenzung, Mikrolobuli, Infiltr.)
- Echogenität (an/deutlich hypo/hypo/iso/hyper)
- Echotextur (homogen/inhomogen)
- Zusammens. (vorw. solid, vorw. zystisch, solid)
- Kalk (Mikrokalk, Makrokalk, Eierschale)
- Lymphkoten (Lymphadenopathie)

12 Kriterien für Multivarianzanalyse

- Form wächst gegen die Architektur
- Halo
- Gut umschrieben
- Mikrolobuli
- Infiltration am Rand
- Hypoechogenität
- Deutliche Hypoechogenität
- Homogenes Echomuster
- Großteils zystisch
- Solid
- Mikrokalk
- Abnorme Lymphknoten

ÖSTERREICHISCHE SCHILDDRÜSENGESELLSCHAFT
AUSTRIAN THYROID ASSOCIATION

Zettinig 2014

Table 4. Proposed Categorization of Thyroid Nodules Based on Their Ultrasonographic Features and Cytology, and the Number and Percentage of Nodules Classified as Benign or Malignant According to Cytology and Histopathology

		Cytology[b]					Classification				
Category	*Probability*[a]	*THY1*	*THY2*	*THY3*	*THY4*	*THY5*	*Benign*	*Malignant*	*Definition*	*Example of US findings*	*Recommendation*
TUS 0									No nodule	Normal or diffuse enlargement of the thyroid gland	
TUS 1	0–7%	15	416	2	6	2	433 (98.2%)	8 (1.8%)	Highly suggestive of benign	Cystic predominant, peripheral halo	No additional US is recommanded if clinically not needed
TUS 2	8–23%	17	372	20	31	9	406 (90.4%)	48 (9.6%)	Probably benign	Circumscribed margin, solid predominant, heterogeneous echotexture, iso- to hyperechogenecity, eggshell or macrocalcification	Long-term US follow-up if clinicaly needed
TUS 3	24–50%	20	292	44	58	52	321 (68.9%)	145 (31.1%)	Indeterminate	Homogeneous echotexture, hypoechogenecity, circumscribed margin, solid, taller, without other US findings suggestive of malignacy	Aspiration and short-term (6 month) follow-up if nondiagnositic cytological result
TUS 4	51–90%	16	55	57	95	79	70 (23.2%)	231 (76.8%)	Probably malignant	One or two US findings suggestive of malignancy, such as markedly hypoechoic, microcalcification, not-circumscribed margin, and lymph node abnormality	Aspiration and immediate reaspiration if nondiagnostic FNAB result
TUS 5	91–100%	2	0	11	14	9	0 (0.0%)	36 (100.0%)	Highly suggestive of malignancy	More than three US findings suggestive of malignancy, such as markedly hypoechoic, microcalcification, not-circumscribed margin, and lymph node abnormality	Consider surgery regardless of FNAB results

[a]Probability is the range for P^{us}, the probability of a nodule being malignant based on an equation derived from US features.
[b]Cytology categories: THY1, inadequate; THY2, benign; THY3, indeterminate; THY4, suspiciously malignant; THY5, malignant.
TUS, thyroid ultrasound; US, ultrasound; FNAB, fine-needle aspiration biopsy.

ÖSTERREICHISCHE SCHILDDRÜSENGESELLSCHAFT
Austrian Thyroid Association

Zettinig 2014

Thyroid Imaging Reporting and Data System for US Features of Nodules: A Step in Establishing Better Stratification of Cancer Risk[1]

Radiology

Jin Young Kwak, MD
Kyung Hwa Han, MS
Jung Hyun Yoon, MD
Hee Jung Moon, MD
Eun Ju Son, MD
So Hee Park, MD
Hyun Kyung Jung, MD
Ji Soo Choi, MD
Bo Mi Kim, MD
Eun-Kyung Kim, MD

Purpose: To develop a practical thyroid imaging reporting and data system (TIRADS) with which to categorize thyroid nodules and stratify their malignant risk.

Materials and Methods: The institutional review board approved this retrospective study, and the requirement to obtain informed consent for the review of images and records was waived. From May to December 2008, ultrasonographically (US)-guided fine-needle aspiration biopsy (FNAB) was performed in 3674 focal thyroid nodules in 3414 consecutive patients. The study included the 1658 thyroid nodules (≥1 cm in maximum diameter at US) in 1638 patients (1373 women, 265 men) for which pathologic diagnosis or follow-up findings were available. Univariate and multivariate analyses with

ÖSTERREICHISCHE SCHILDDRÜSENGESELLSCHAFT
AUSTRIAN THYROID ASSOCIATION

Zettinig 2014

Methoden

- Prospektiv
- 8 Monate
- FNA in 3674 Knoten in 3414 Patienten

Identifikation von unabhängigen Faktoren

- Solide Komponente
- Hypoechogenität
- Deutliche Hypoechogenität
- Mikrolobuli bzw. unregelmäßiger Rand
- Mikrokalk
- More tall than wide

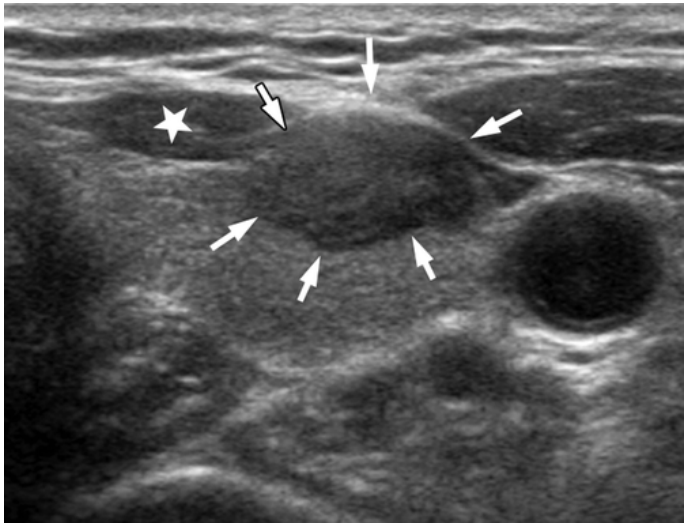

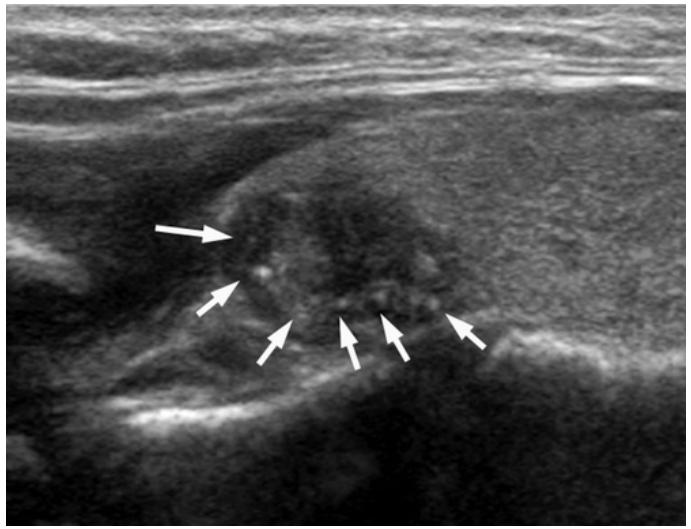

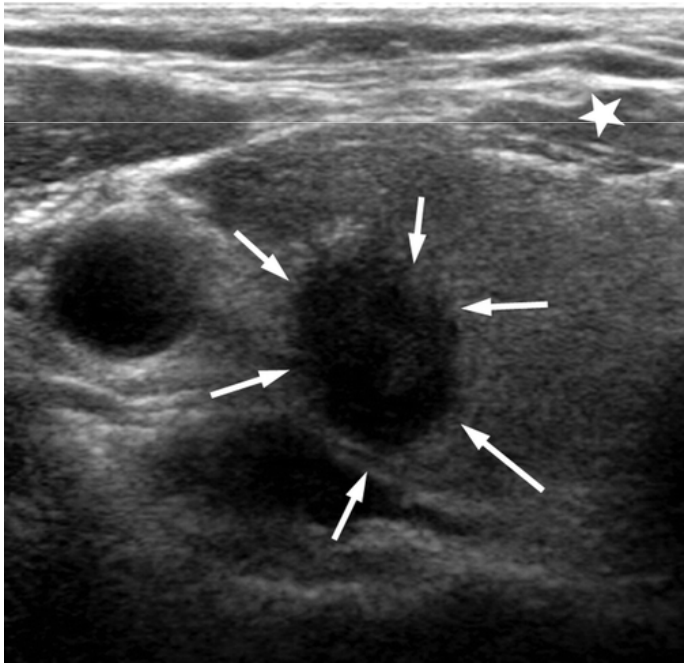

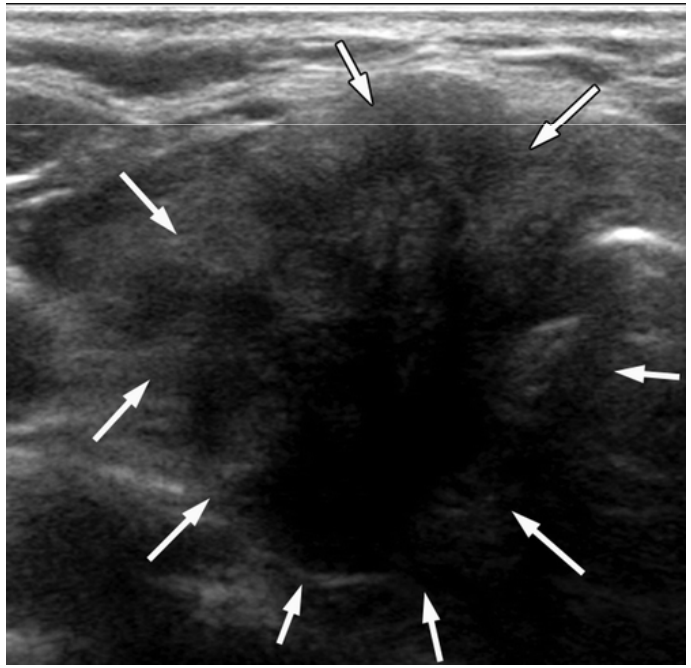

ÖSTERREICHISCHE SCHILDDRÜSENGESELLSCHAFT
AUSTRIAN THYROID ASSOCIATION

Published in: Jin Young Kwak; Kyung Hwa Han; Jung Hyun Yoon; Hee Jung Moon; Eun Ju Son; So Hee Park; Hyun Kyung Jung; Ji Soo Choi; Bo Mi Kim; Eun-Kyung Kim; *Radiology* **2011,** 260, 892-899.

Zettinig 2014

Study and Parameter	Category 1	2	3	4	5
Horvath et al (13)					
Definition	Benign	Benign	Probably benign	4a: undetermined; 4b: suspicious	Consistent with malignancy
Proposed risk of malignancy	0	0	<5	4a: 5–10; 4b: 10–80	>80
Risk of malignancy	0	0	14.1	45	89.6
Park et al (12)					
Definition	Highly suggestive of benignity	Probably benign	Indeterminate	Probably malignant	Highly suggestive of malignancy
Probability*	0–7	8–23	24–50	51–90	91–100
Risk of malignancy	1.8	9.6	31.1	76.8	100
BI-RADS (14)					
Definition	Negative	Benign	Probably benign	4a: low suspicion for malignancy; 4b: intermediate suspicion for malignancy; 4c: moderate concern but not classic for malignancy	Highly suggestive of malignancy
Risk of malignancy	0	0	<2	4a: 2–10; 4b: 10–50; 4c: 50–95	>95
Current study					
Definition	Negative	Benign	Probably benign (no suspicious US features)	4a: low suspicion for malignancy (one suspicious US feature); 4b: intermediate suspicion for malignancy (two suspicious US features); 4c: moderate concern but not classic for malignancy (three or four suspicious US features)	Highly suggestive of malignancy (five suspicious US features)
Fitted probability†	0	0	2–2.8	4a: 3.6–12.7; 4b: 6.8–37.8; 4c: 21–91.9	88.7–97.9
Risk of malignancy	0	0	1.7	4a: 3.3; 4b: 9.2; 4c: 44.4–72.4	87.5

ÖSTERREICHISCHE SCHILDDRÜSENGESELLSCHAFT
AUSTRIAN THYROID ASSOCIATION

Zettinig 2014

Brauchen wir TIRADS?

ÖSTERREICHISCHE SCHILDDRÜSENGESELLSCHAFT
AUSTRIAN THYROID ASSOCIATION

Zettinig 2014

Vieles ist noch offen

- Ein Scoring System ist prinzipiell nicht schlecht
- Für TIRADS Scoring je nach Autor unterschiedlich, verschiedenste "revised TIRADS" Scores, v. a. für Gruppe 4
- Chilenisches Patientenkollektiv von Horvath et al. hinsichtlich Jodversorgung völlig anders als in Mitteleuropa
- TIRADS sehr komplex, für den Befunder sehr kompliziert zu klassifizieren

SCHILDDRÜSENSONOGRAPHIE:

Kleine echoarme Schilddrüse. Das Echomuster inhomogen. Über dem Isthmus finden sich zwei Delphische Lymphknoten.

Ergebnis: Bild wie bei Autoimmunthyreopathie bzw. Autoimmunthyreoiditis Typ Hashimoto.
Bei fehlenden Voruntersuchung sonographische Verlaufskontrolle in 9 – 12 Monaten inkl. Labor empfehlenswert.
TIRADS 3.

Mit bestem Dank für die Zuweisung
und freundlichen Grüßen

TIRADS: Thyroid Imaging Reporting And Documentation System
TIRADS 0: Nicht beurteilbar, Untersuchung unzureichend. **TIRADS 1**: Normale Schilddrüsensonographie. **TIRADS 2**: Gutartiger Befund nahezu sicher benigen. **TIRADS 3**: Wahrscheinlich gutartiger Befund. Malignitätswahrscheinlichkeit unter 2%.
TIRADS 4a: Malignitätswahrscheinlichkeit 5 – 10%. **TIRADS 4b**: Malignitätswahrscheinlichkeit 10 – 50%
TIRADS 4c: Malignitätswahrscheinlichkeit 50 – 80%. **TIRADS 5**: Wahrscheinlich maligner Befund, Malignitätswahrscheinlichkeit über 80%. **TIRADS 6**: gesichertes Schilddrüsen-Karzinom.

ÖSTERREICHISCHE SCHILDDRÜSENGESELLSCHAFT
AUSTRIAN THYROID ASSOCIATION

Zettinig 2014

TI-RADS

Thyroid Imaging and Reporting Database System – Docteur Gilles Russ

Chercher

- Home
- ICONOGRAPHIE TI-RADS
- AUTRES SIGNES
- INDICATIONS DES PONCTIONS
- Contacts
- Où sommes-nous ?

ICONOGRAPHIE TI-RADS

AUTRES SIGNES

QU'EST CE QUE LE SYSTEME TI-RADS ?

TI-RADS est l'acronyme de Thyroid Imaging-Reporting and Database System.

Il s'agit d'un outil d'assurance qualité en échographie de la thyroïde qui inclut trois volets :

- un atlas lexical, définissant et illustrant l'ensemble des termes utilisés en échographie pour décrire les nodules thyroïdiens,
- un compte-rendu standardisé,
- des catégories d'évaluation de 1 à 5, pour normal à malin, et des recommandations d'action à entreprendre.

La version présentée est V5 développée de manière prospective sur plus de 4000 cas, intégrant l'élastographie dans l'arbre décisionnel.

SIGNIFICATION DU SCORE TI-RADS

SIGNIFICATION DU SCORE TI-RADS
STRATIFICATION DU RISQUE DE MALIGNITE

SCORE TI-RADS	SIGNIFICATION	RISQUE DE MALIGNITE (%)
1	EXAMEN NORMAL	
2	BENIN	≈ 0
3	TRES PROBABLEMENT BENIN	0.25
4A	FAIBLE SUSPICION DE MALIGNITE	6
4B	FORTE SUSPICION DE MALIGNITE	69
5	PRATIQUEMENT CERTAINEMENT MALIN	≈ 100

Quelle:
www.tirads.com

ÖSTERREICHISCHE SCHILDDRÜSENGESELLSCHAFT
AUSTRIAN THYROID ASSOCIATION

Zettinig 2014

ÖSTERREICHISCHE SCHILDDRÜSENGESELLSCHAFT

AUSTRIAN THYROID ASSOCIATION

www.schilddruesengesellschaft.at