ÖSTERREICHISCHE SCHILDDRÜSENGESELLSCHAFT
AUSTRIAN THYROID ASSOCIATION

HAUPTPROGRAMM

1. ÖSTERREICHISCHER SCHILDDRÜSEN-DIALOG

Seefeld, Tirol - Hotel St. Peter
20.-22. März 2014

www.osdg.at
www.schilddruesengesellschaft.at

Postoperativer Hypoparathyreoidismus

Michael Hermann, Wien

2. Chirurgische Abteilung
„Kaiserin Elisabeth" in der
Rudolfstiftung

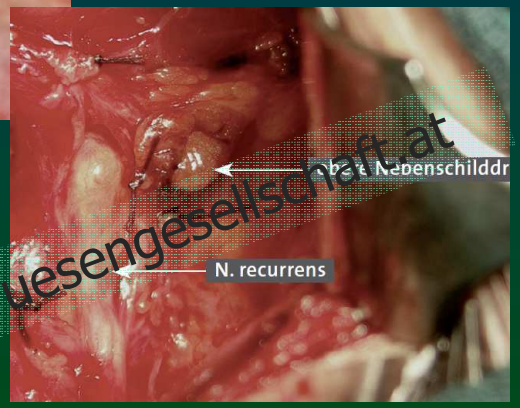

[redacted]

Klin. Abteilung für Nephrologie und Dialyse
Nierenambulanz

[redacted]

[redacted]

[redacted]

Zuweisungsgrund Vorstellung über den niedergelassenen Bereich bei erhöhtem Serumkreatinin

Diagnosen
-Chronische Niereninsuffizienz im CKD-Stadium 1-2G0 auf Basis einer Nephrokalzinose bei sekundärem Hypoparathyreoidismus
-St.p. Thyreoidektomie und Parathyreoidektomie bei papillärem Schilddrüsenkarzinom T2N1bM0 + Radiojod-Therapie 1999

Allergien keine bekannt

Heimmedikation

Thyrex 160 µg	Mo-Fr 1-0-0, Sa+So 1,5-0-0
Rocaltrol 0,5 µg	2-0-0
Maxi-Kalz 1.000	1-0-1

Laborwerte

Serumkreatinin	1,36-1,04 mg/dl
Harnsediment	unauffällig
Serumkalzium	extern 3,0 mmol/l, hierorts 2,6 mmol/l

Zusammenfassung
Der Patient wird zugewiesen seitens der Urologie/Allgemeinmedizin bei erhöhten Nierenretentionsparametern und erhöhtem Serumkalzium. Sonographisch imponiert die Niere bds. zystisch degeneriert mit multiplen Zysten und partiellen Markverkalkungen. Der Patient steht unter höchstdosierter Vitamin D-Therapie sowie Kalziumtherapie seit seiner Thyreoidektomie und Parathyreoidektomie, unter anderem deshalb da er auch sehr zu hypokalziämischen Muskelkrämpfen neigt. Im Labor zeigt sich ein sekundärer Hypoparathyreoidismus mit einem PTH unter der Nachweisbarkeitsgrenze, eine reguläre Schilddrüsenfunktion sowie ein geringgradiger Vitamin D-Mangel

[redacted]

(25 (OH) D von 42,5 nmol/l). Im Sediment bzw. immunologisch kein Hinweis auf eine immunologisch getriggerte Eigennierenerkrankung, 24h-Blutdruck und HbA1c unauffällig.

Aufgrund der Befundkonstellation wird die Diagnose einer Nephrokalzinose gestellt. Aus nephrologischer Sicht besteht bei Nephrokalzinose im Rahmen eines sekundärem Hypoparathyreoidismus und Hyperkalziurie unter der derzeitigen Medikaton mit Hochdosis-Rocaltrol und Maxi-Kalz ein deutlich erhöhtes Risiko zur Progression einer terminalen Nierenerkrankung. Um dieses Risiko zu minimieren besteht aus nephrologischer Sicht eine einzige Therapieoption, nämlich die Gabe eines synthetischen Parathormonpräparates (Forsteo). Da die jährlichen Kosten für diese Medikation weit unter unter den Gesamtkosten einer Nierenersatztherapie liegen erscheint diese Alternative in Anbetracht einer hohen Wahrscheinlichkeit einer terminalen Niereninsuffizienz unter der Beibehaltung der derzeitigen Therapie als die beste Option.

Wir befürworten deshalb die Genehmigung einer Dauertherapie mit Forsteo für den o.a. Patienten. Des Weiteren wurden weitere therapeutischen Maßnahmen bei Nephrokalzinose mit dem Patienten besprochen. Regelmäßige Kontrolle hierorts sind indiziert.

Therapieempfehlung

Thyrex 160 µg	Mo-Fr 1-0-0, Sa+So 1,5-0-0
Forsteo 20 µg	1-0-0
Maxi-Kalz 1.000	1-0-1

Mit freundlichen Grüßen

Complications to thyroid surgery: results as reported in a database from a multicenter audit comprising 3,660 patients

A. Bergenfelz · S. Jansson · A. Kristoffersson · H. Mårtensson · E. Reihnér · G. Wallin · I. Lausen

At 6 months postoperatively, 4.4% of the patients still medicated with vitamin D. However, data are still missing for 4.5% of the patients who were treated at the first follow-up, and therefore, the risk for medically treated hypocalcaemia is most certainly higher. The finding of a high incidence of long-term medication with vitamin D is alarming and needs to be further investigated and addressed.

Conclusion Complications to thyroid surgery are not uncommon. The high frequency of hypocalcaemia treated with vitamin D after 6 months is a cause of concern.

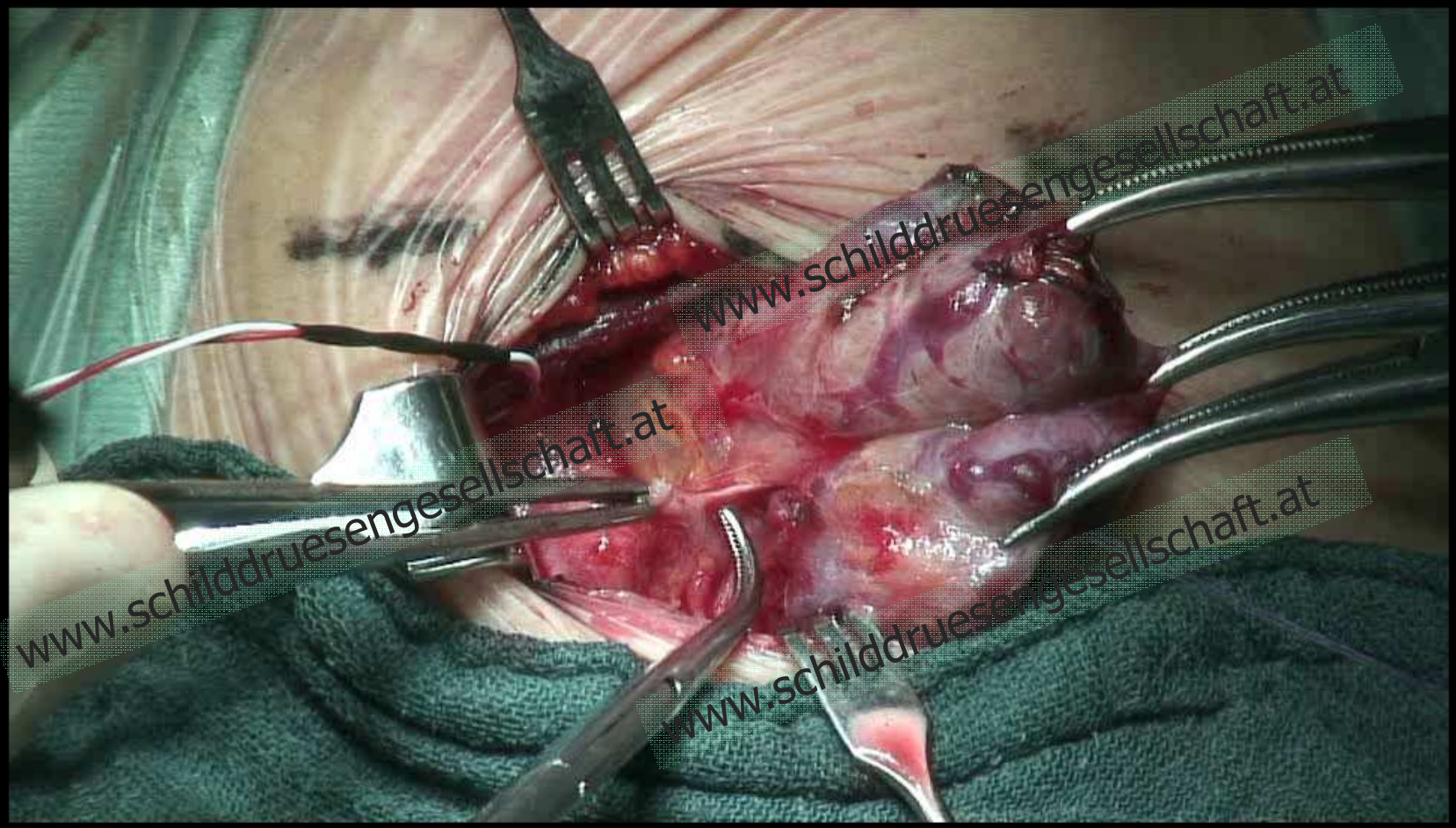

Kaiserin Elisabeth Spital
In guten Händen

kav wiener krankenanstalten verbund
Unternehmen Gesundheit

Schilddrüse

Postoperativer Hypoparathyreoidismus
M. Hermann (Wien)
2. Chirurgie „Kaiserin Elisabeth“ Rudolfstiftung

StaDt Wien
Wien ist anders.

Kinetics of serum parathyroid hormone during and after thyroid surgery

M. Hermann[1], J. Ott[1], R. Promberger[1], F. Kober[1], M. Karik[1] and M. Freissmuth[2]

[1]Department of Surgery, Kaiserin-Elisabeth-Spital
University of Vienna, Vienna, Austria
Correspondence to: Dr M. Freissmuth, Institute of
Waehringer Strasse 13a, A-1090 Vienna, Austria (

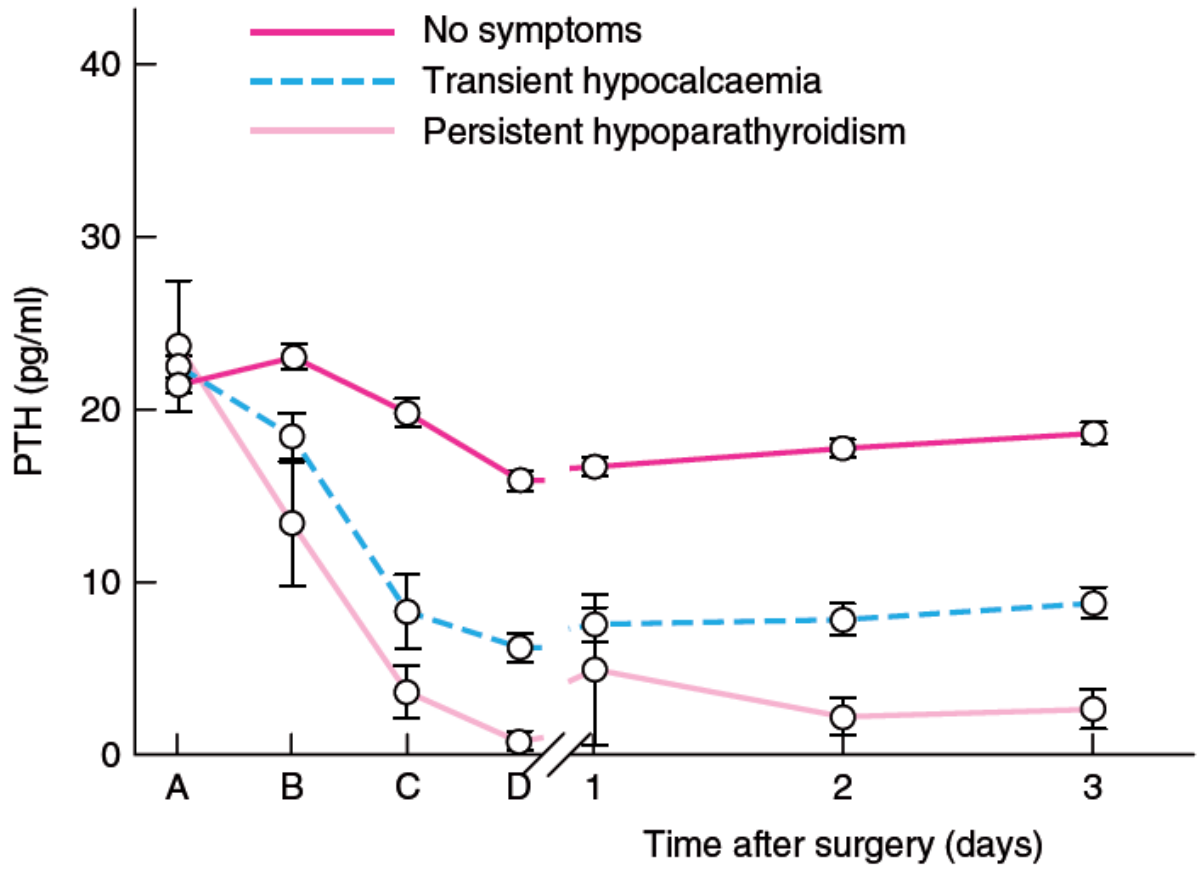

British Journal of Surgery 2008; **95**: 1480–1487

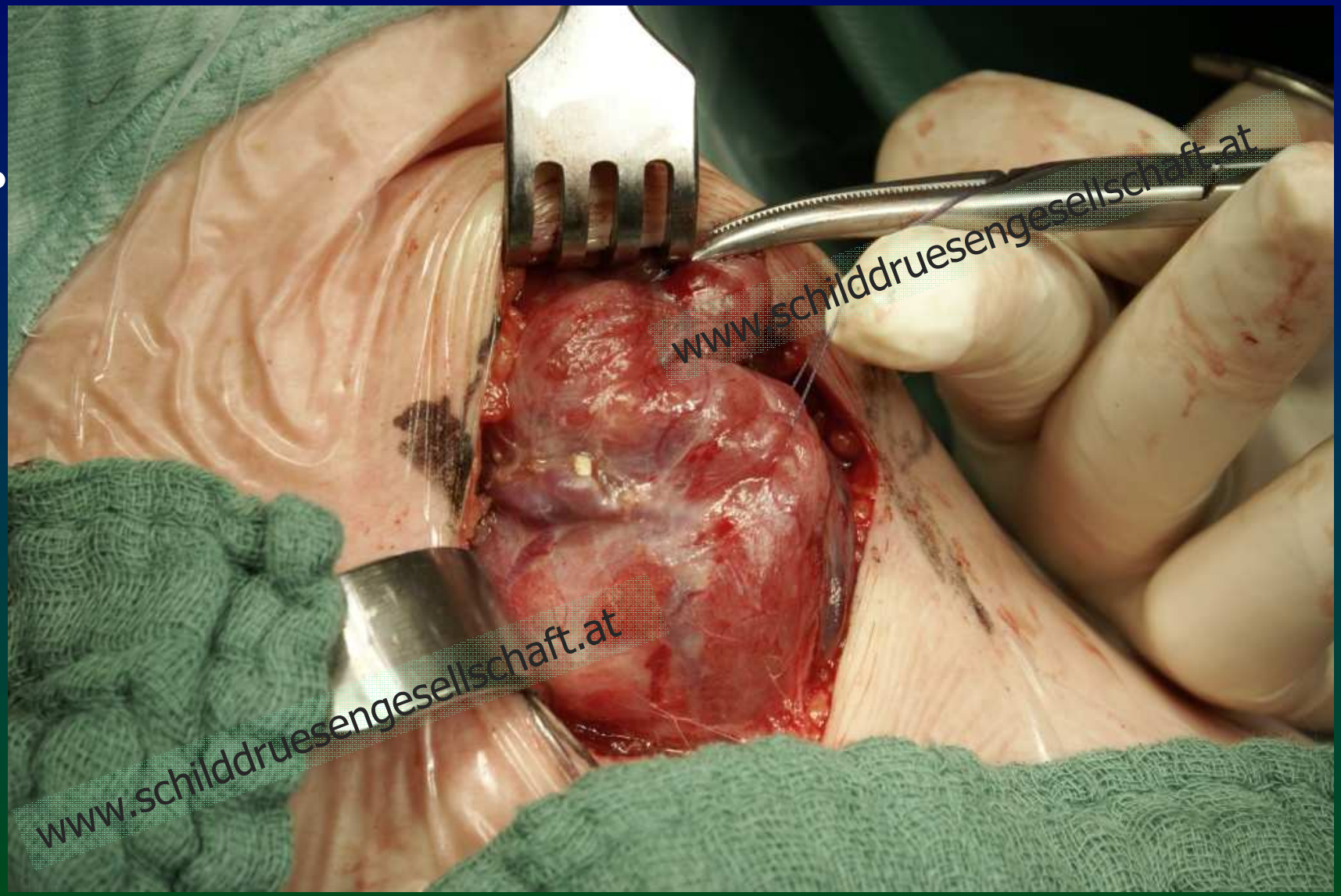
www.schilddruesengesellschaft.at
www.schilddruesengesellschaft.at

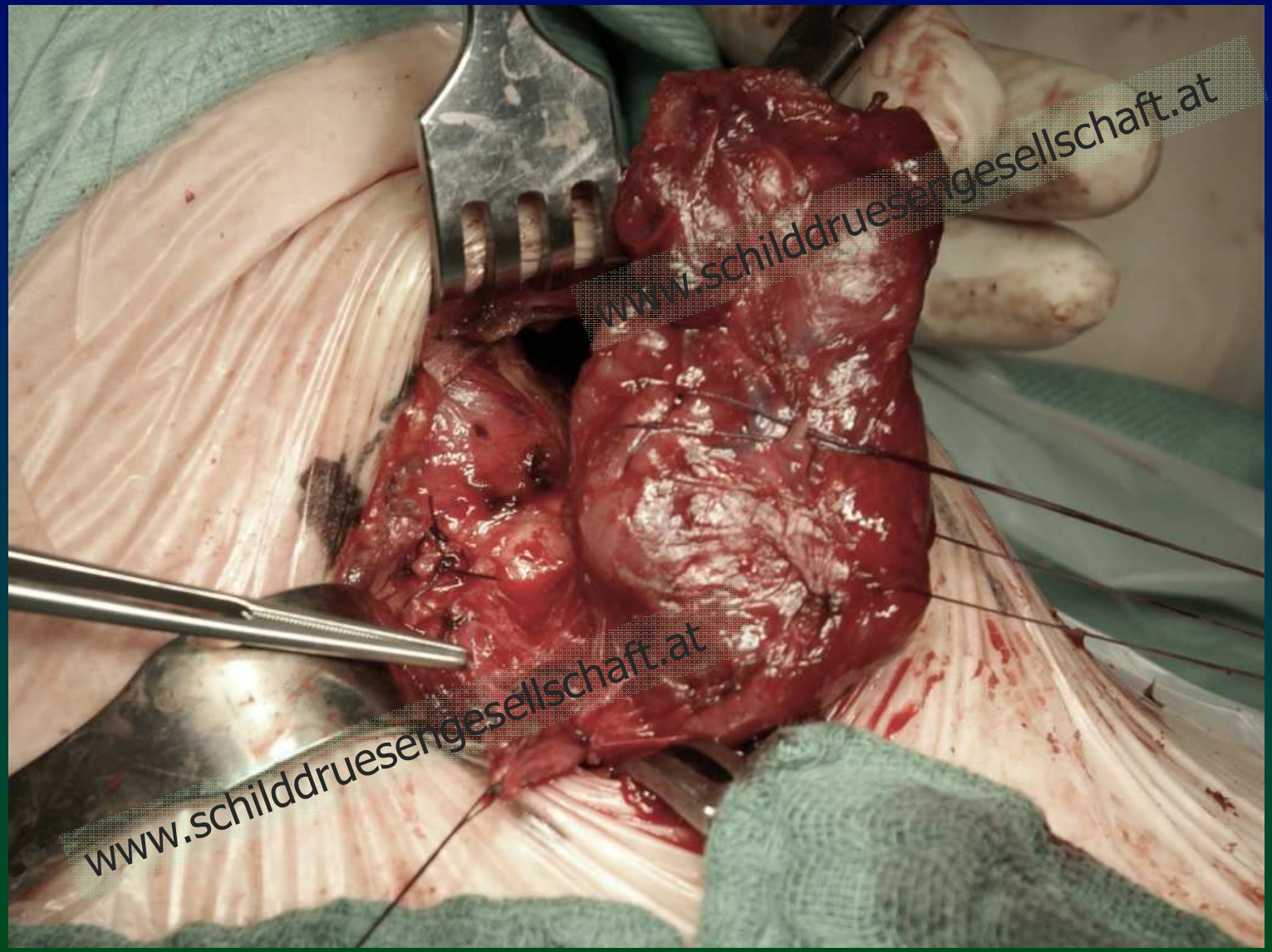

Kaiserin Elisabeth Spital
In guten Händen

kav wiener krankenanstalten verbund
Unternehmen Gesundheit

Schilddrüse

Postoperativer Hypoparathyreoidismus
M. Hermann (Wien)
2. Chirurgie „Kaiserin Elisabeth“ Rudolfstiftung

Stadt Wien
Wien ist anders.

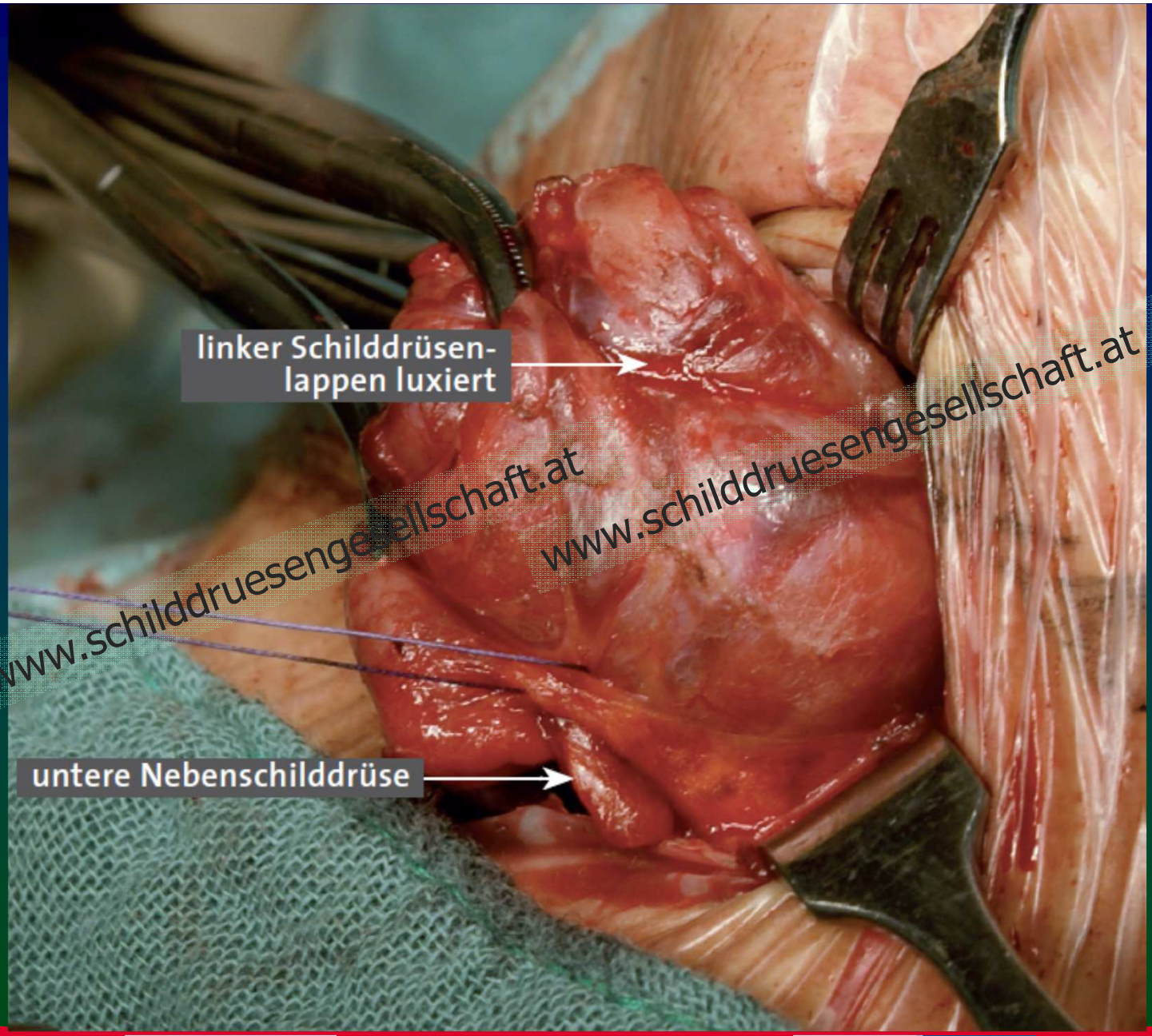

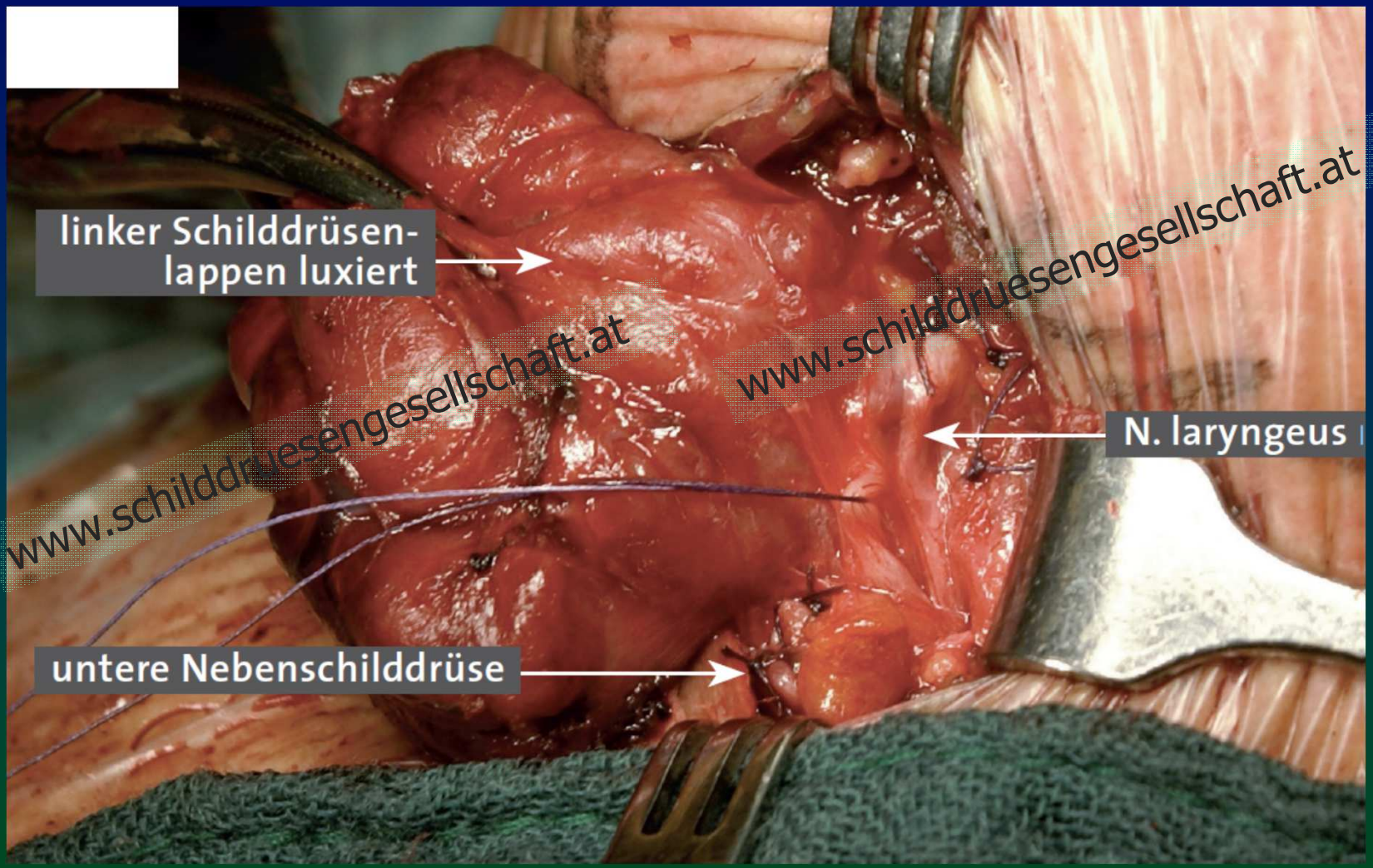
linker Schilddrüsen-
lappen luxiert
N. laryngeus
untere Nebenschilddrüse
www.schilddruesengesellschaft.at
www.schilddruesengesellschaft.at

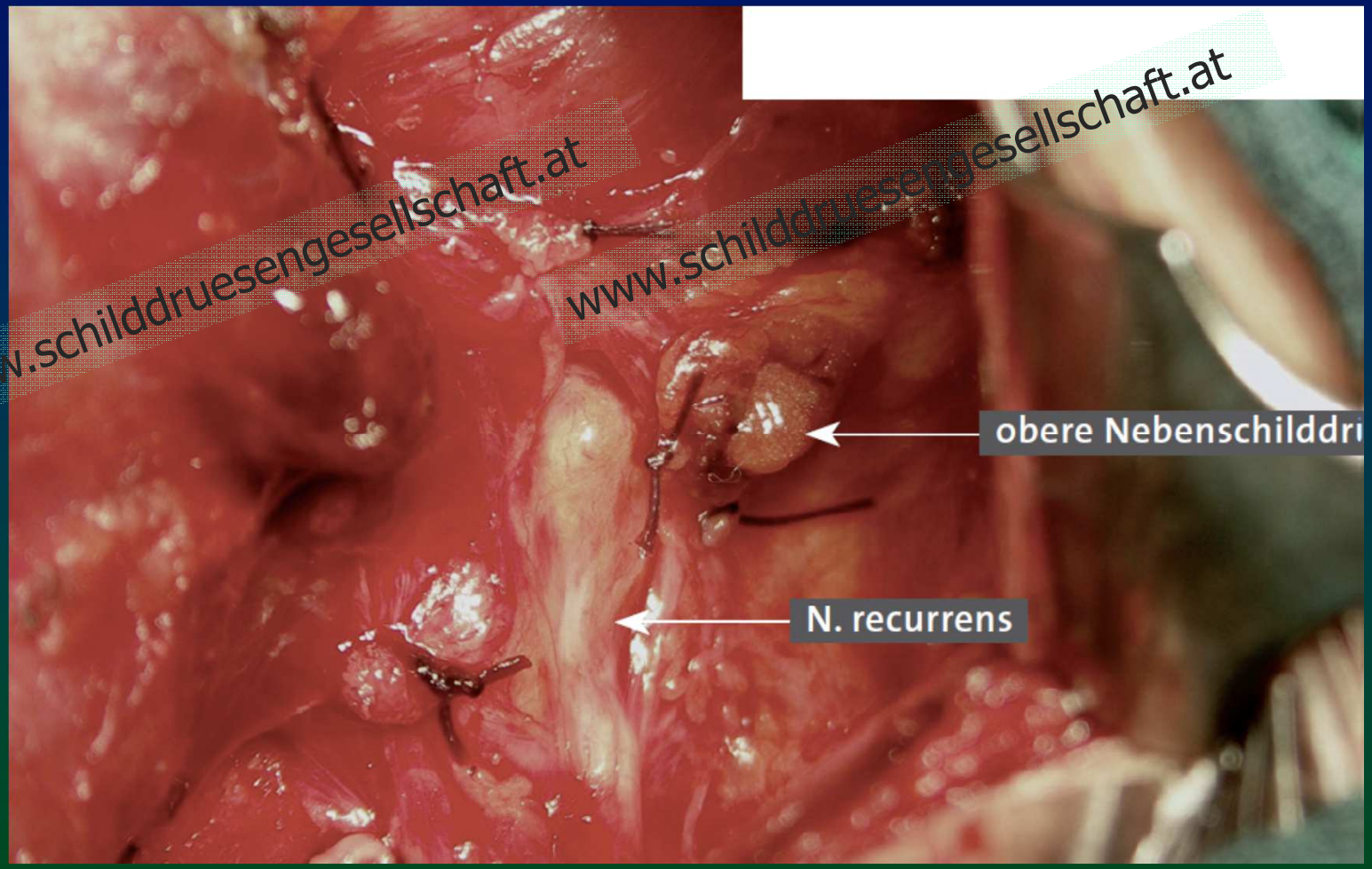

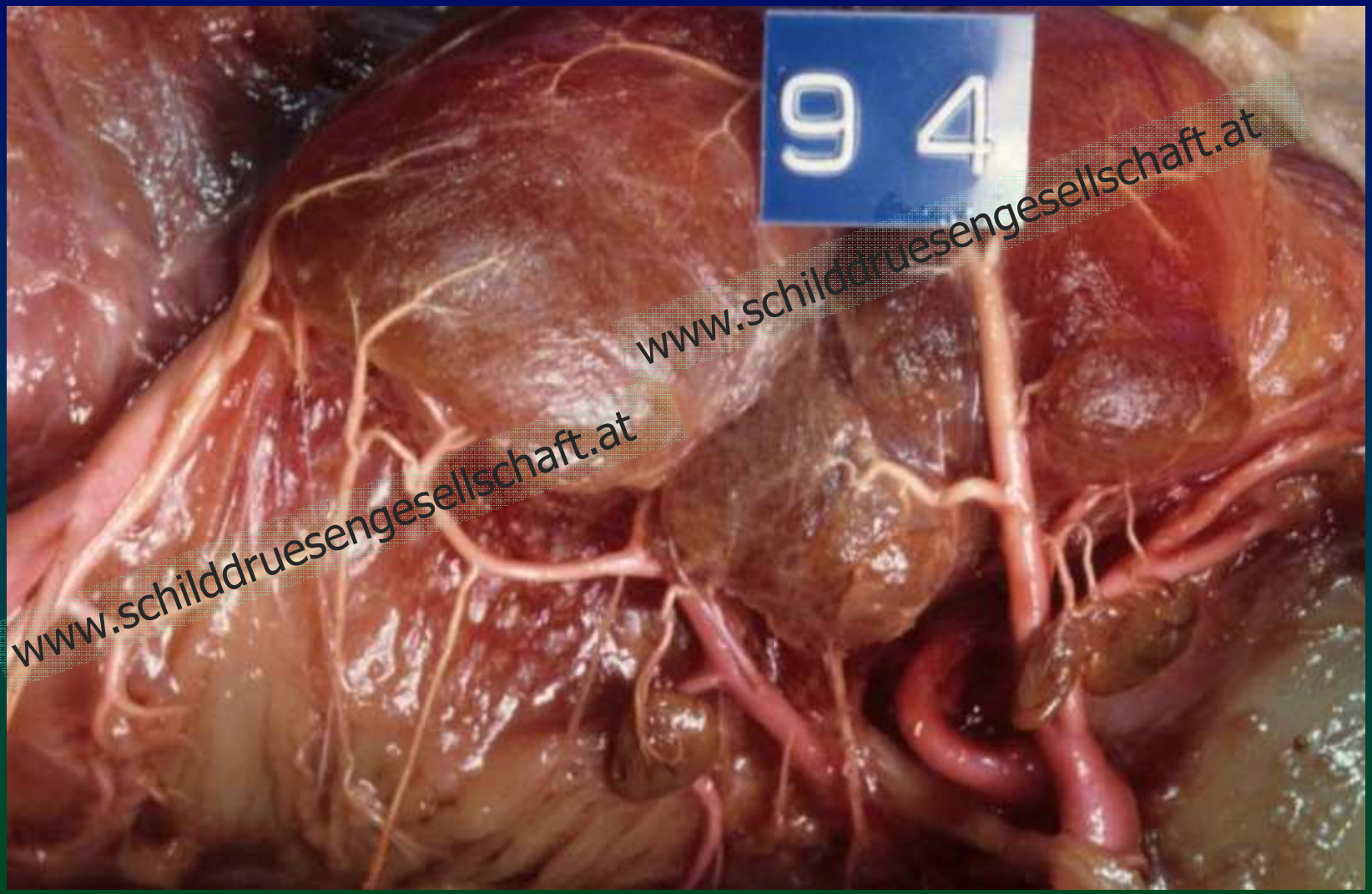

Delattre JF, J Chir 1982

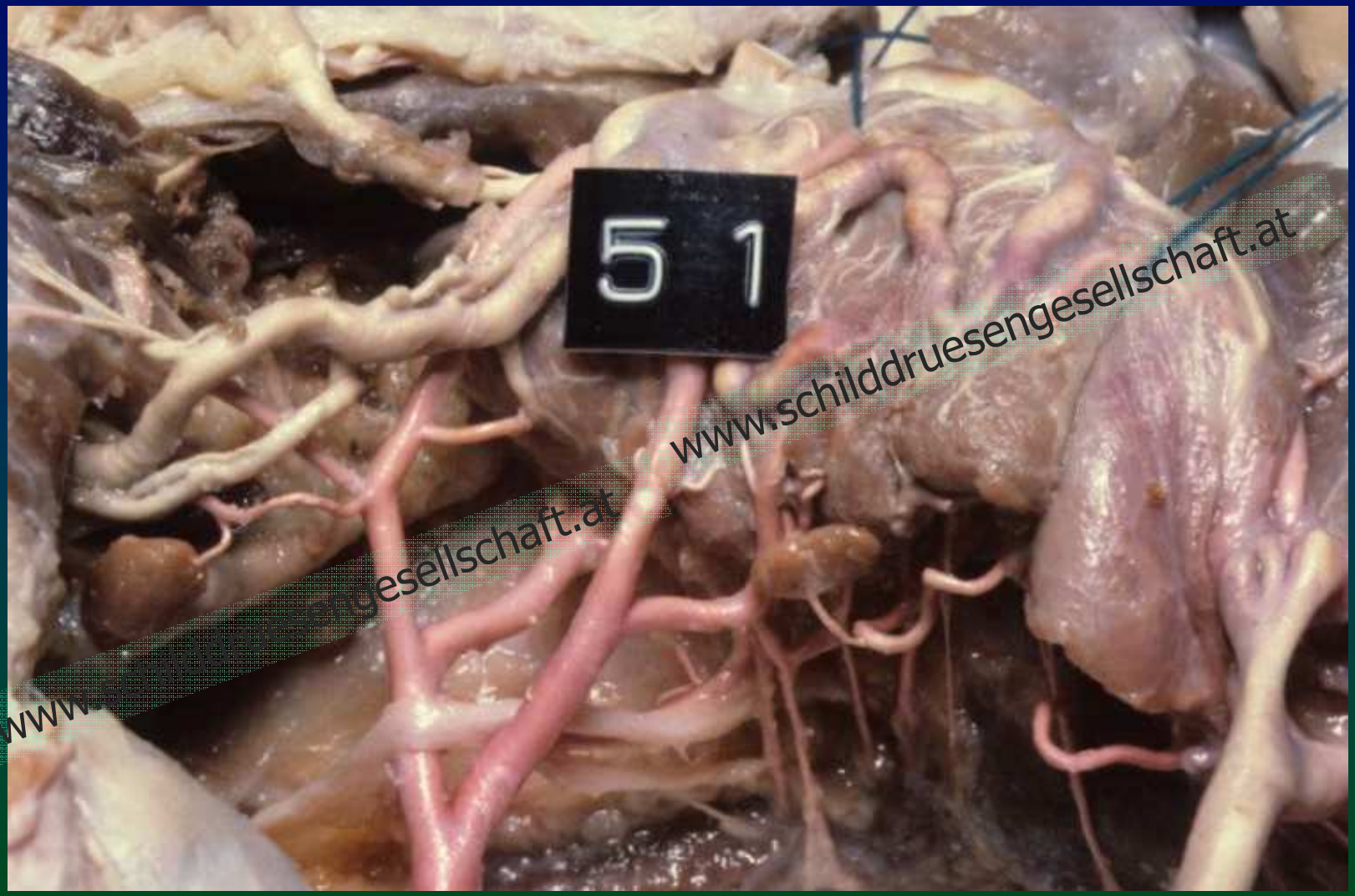

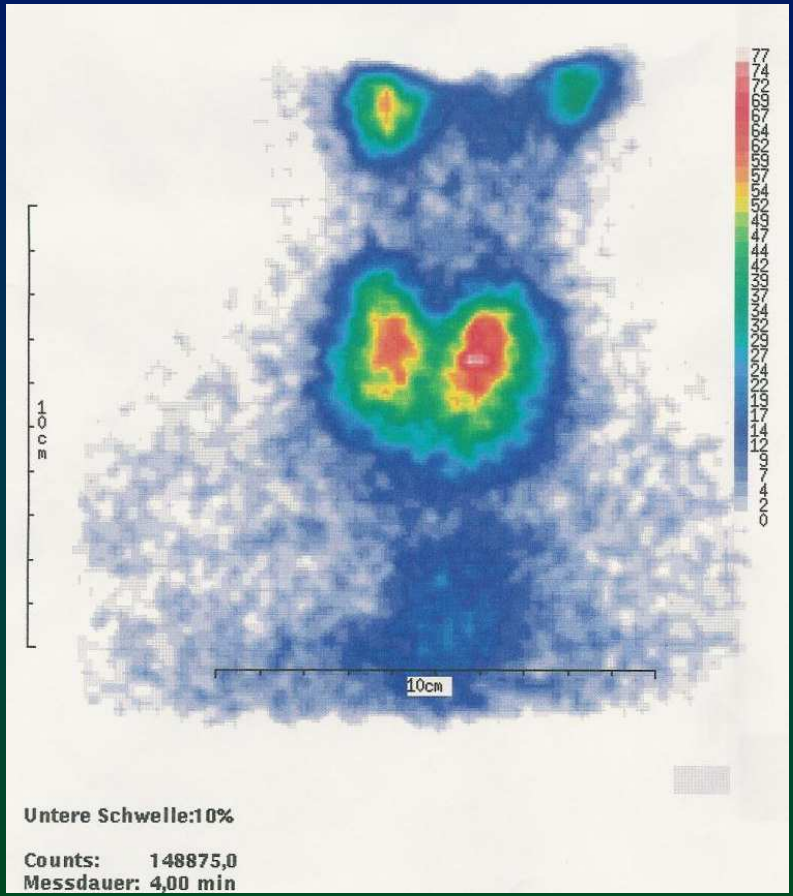
10cm
10cm
Untere Schwelle:10%
Counts: 148875,0
Messdauer: 4,00 min

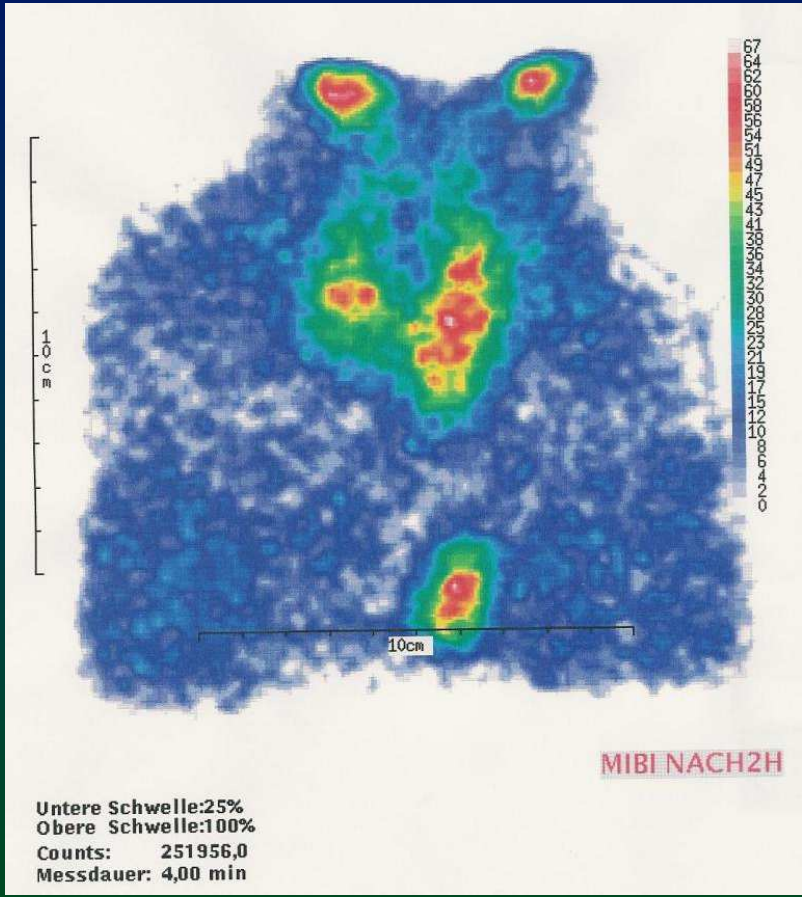
67
64
62
60
58
56
54
51
49
47
45
43
41
38
36
34
32
30
28
25
23
21
19
17
15
12
10
8
6
4
2
0
10cm
10cm
MIBI NACH2H
Untere Schwelle:25%
Obere Schwelle:100%
Counts: 251956,0
Messdauer: 4,00 min

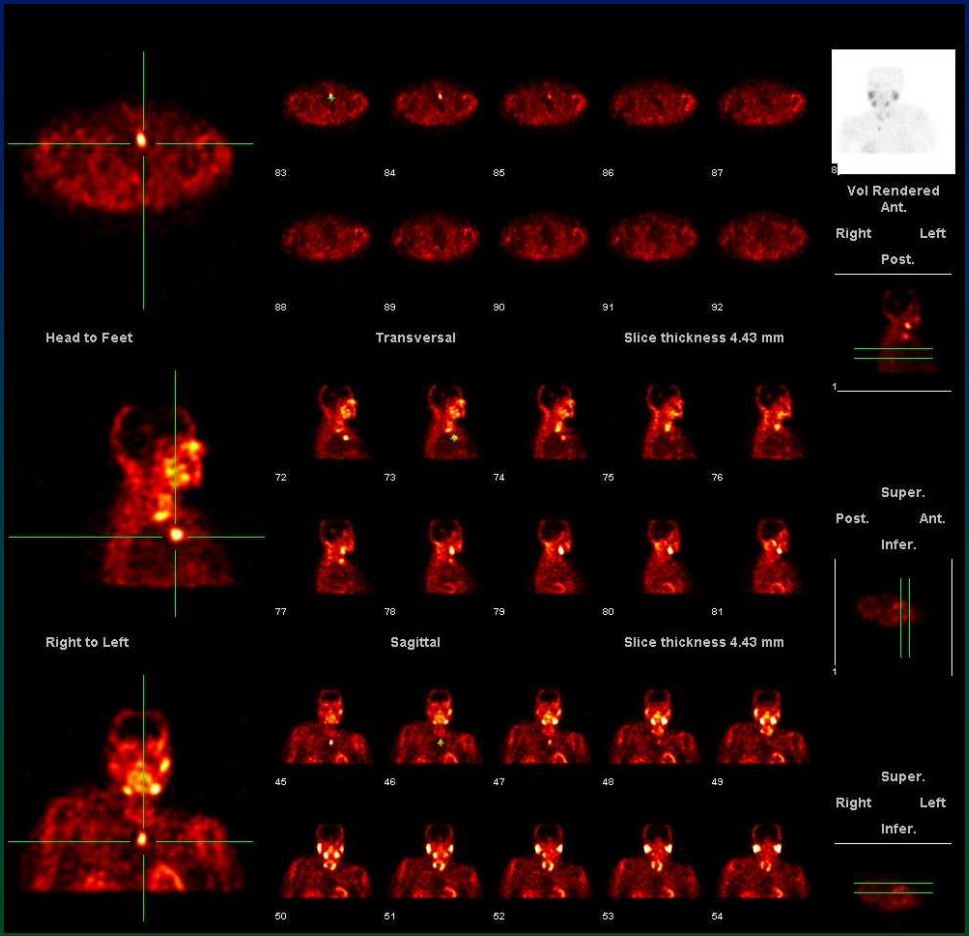
Head to Feet
Transversal
Slice thickness 4.43 mm
Vol Rendered
Ant.
Right
Left
Post.
Right to Left
Sagittal
Slice thickness 4.43 mm
Super.
Post.
Ant.
Infer.
Super.
Right
Left
Infer.

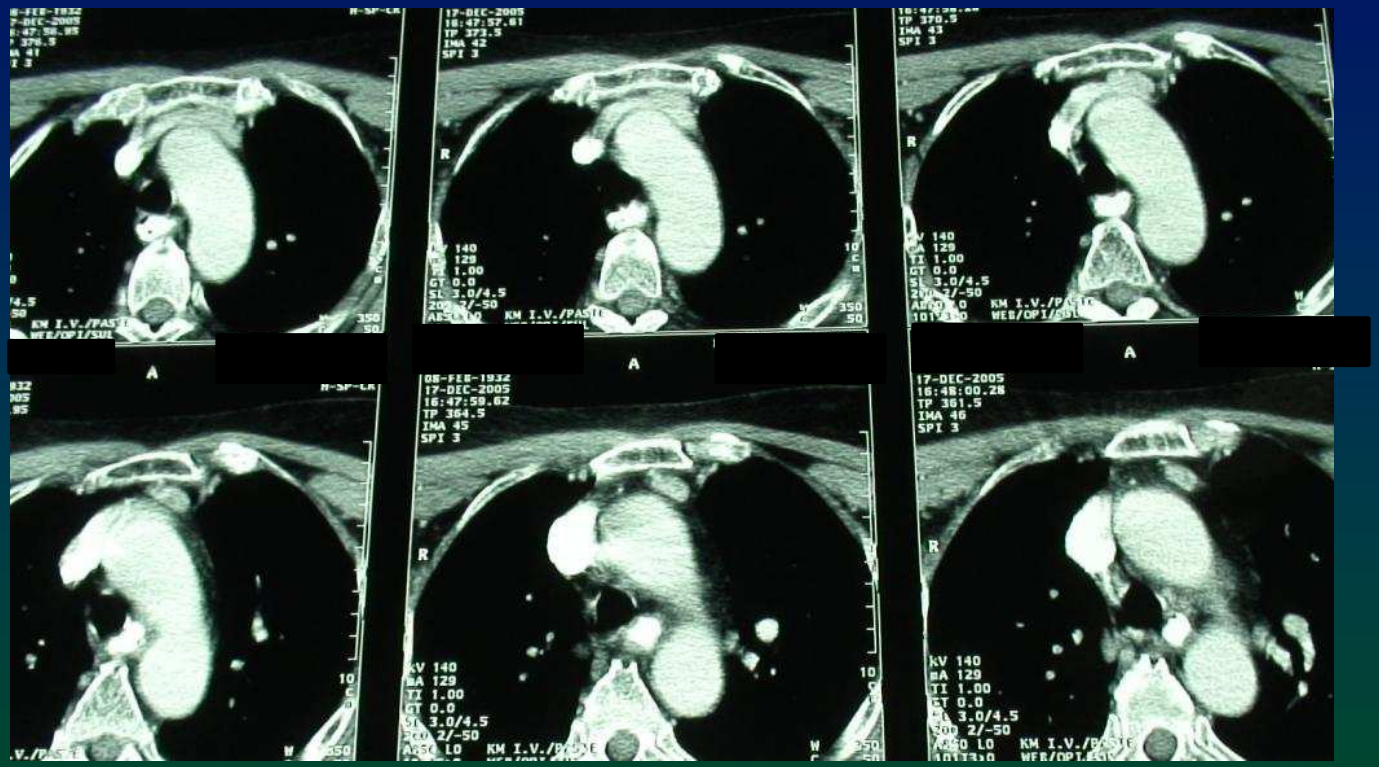
17-DEC-2005
16:47:57.61
TP 373.5
IMA 42
SPI 3
R
A
08-FEB-1932
17-DEC-2005
16:47:59.62
TP 364.5
IMA 45
SPI 3
17-DEC-2005
16:48:00.28
TP 361.5
IMA 46
SPI 3
kV 140
mA 129
TI 1.00
GT 0.0
SL 3.0/4.5
2/-50
KM I.V./PASTE

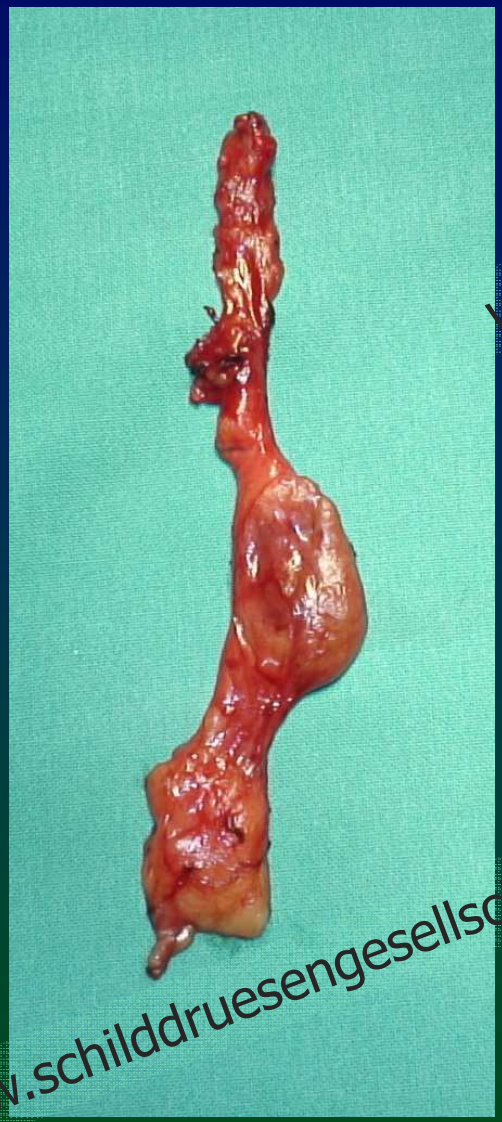

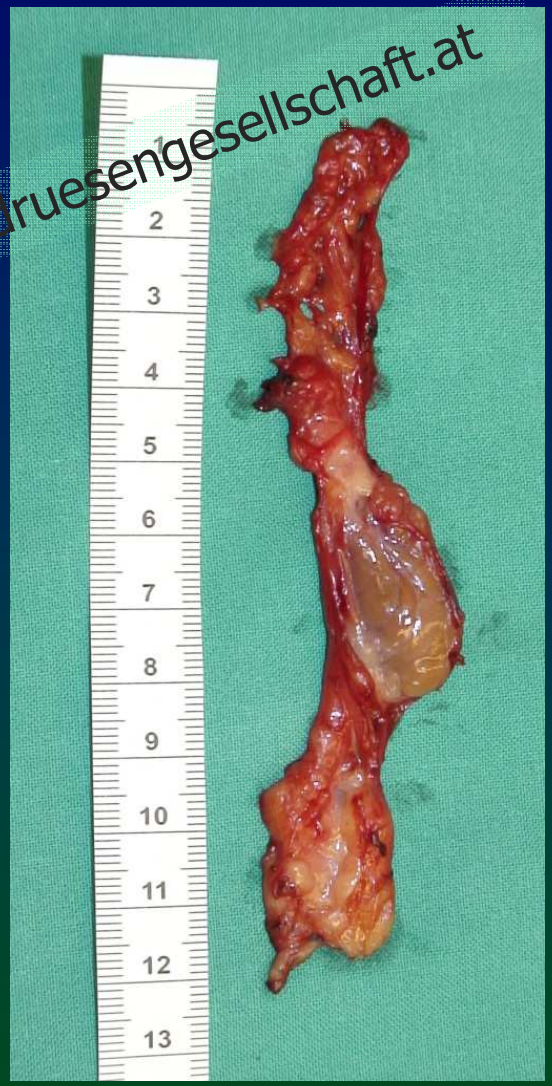

Lagevarianten der oberen und unteren Nebenschilddrüse

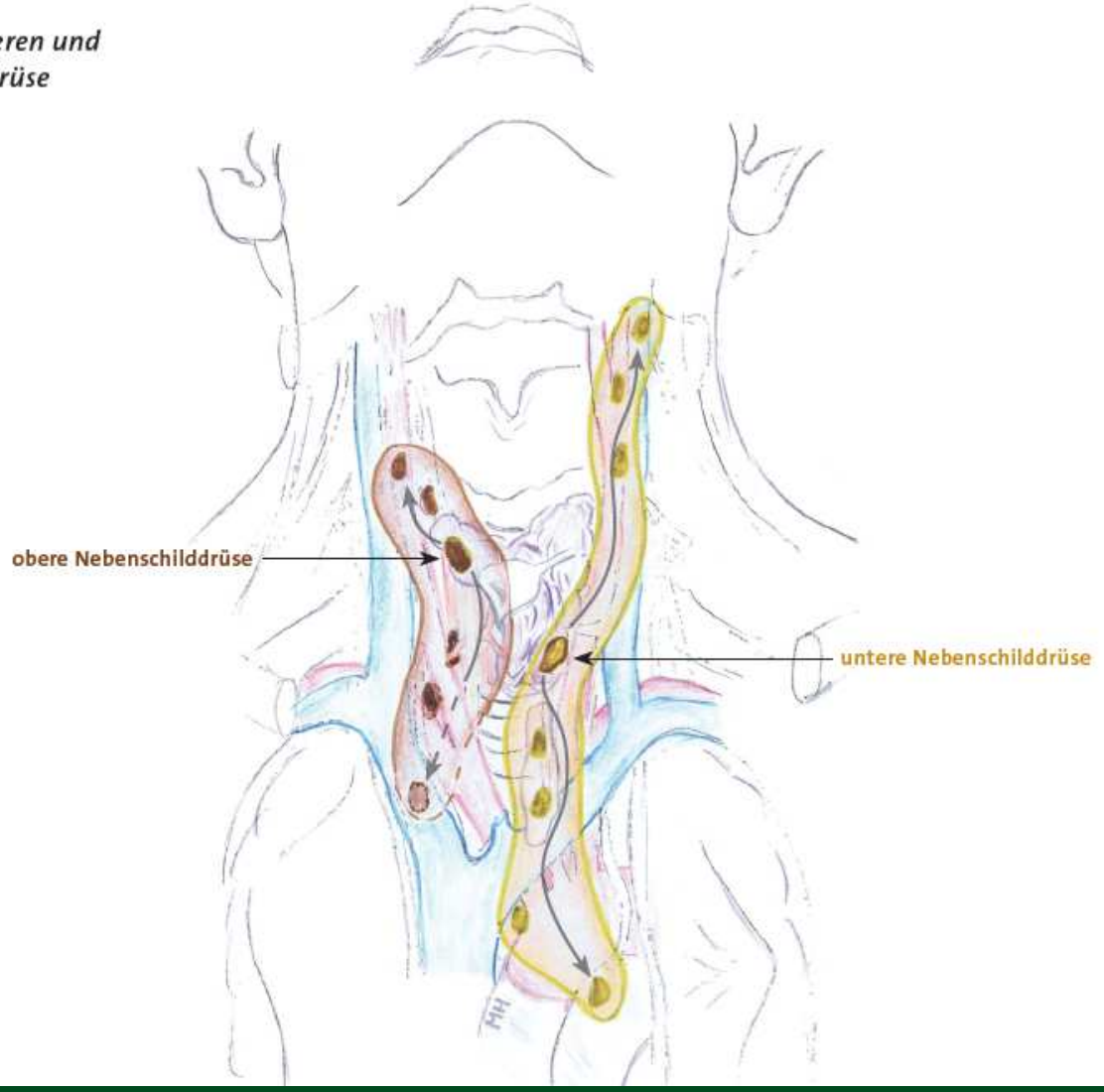

Anzahl der dargestellten Nebenschilddrüsen bei normaler Nebenschilddrüsenfunktion und permanentem postoperativen Hypoparathyreoidismus ist gleich

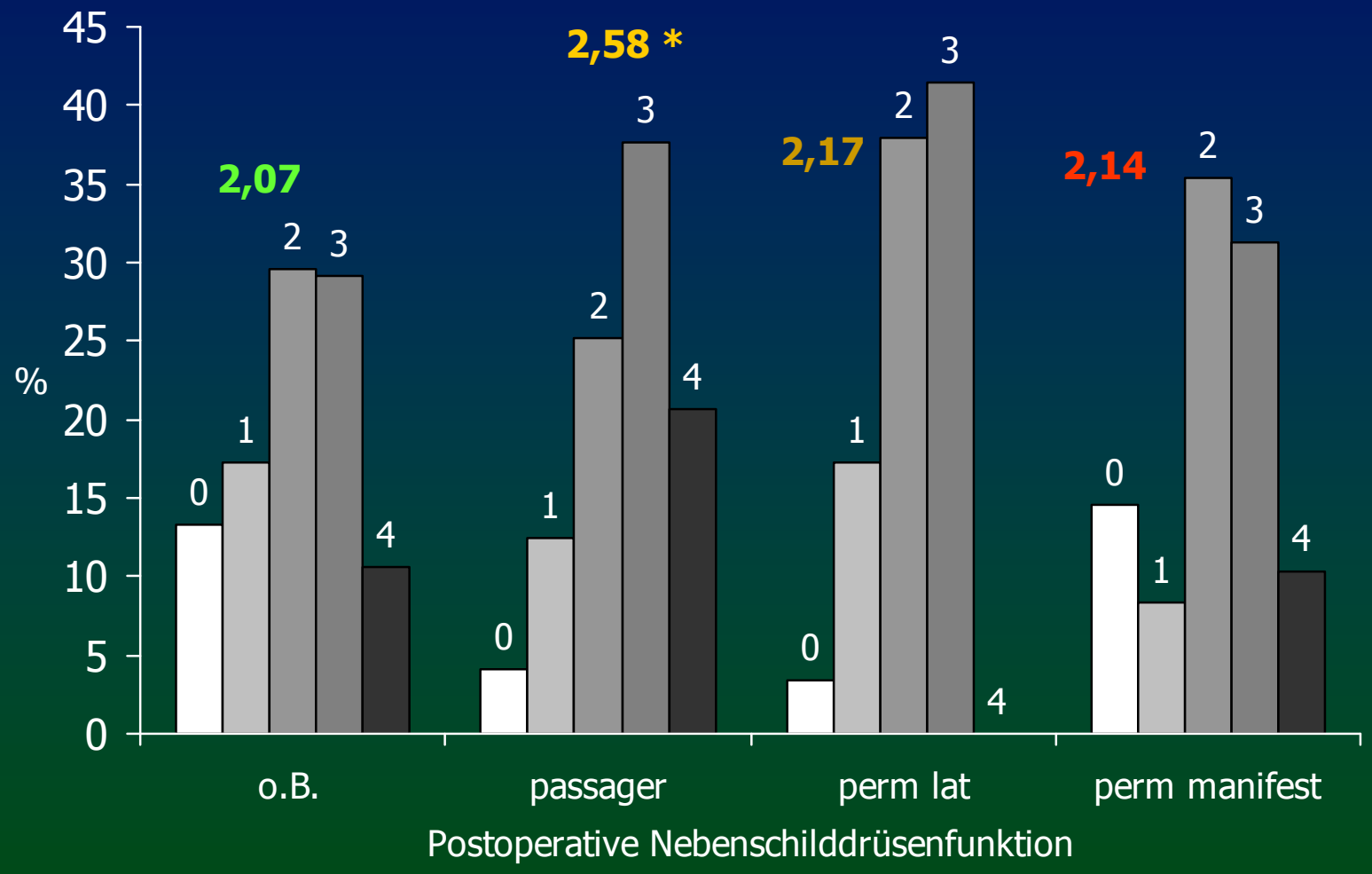

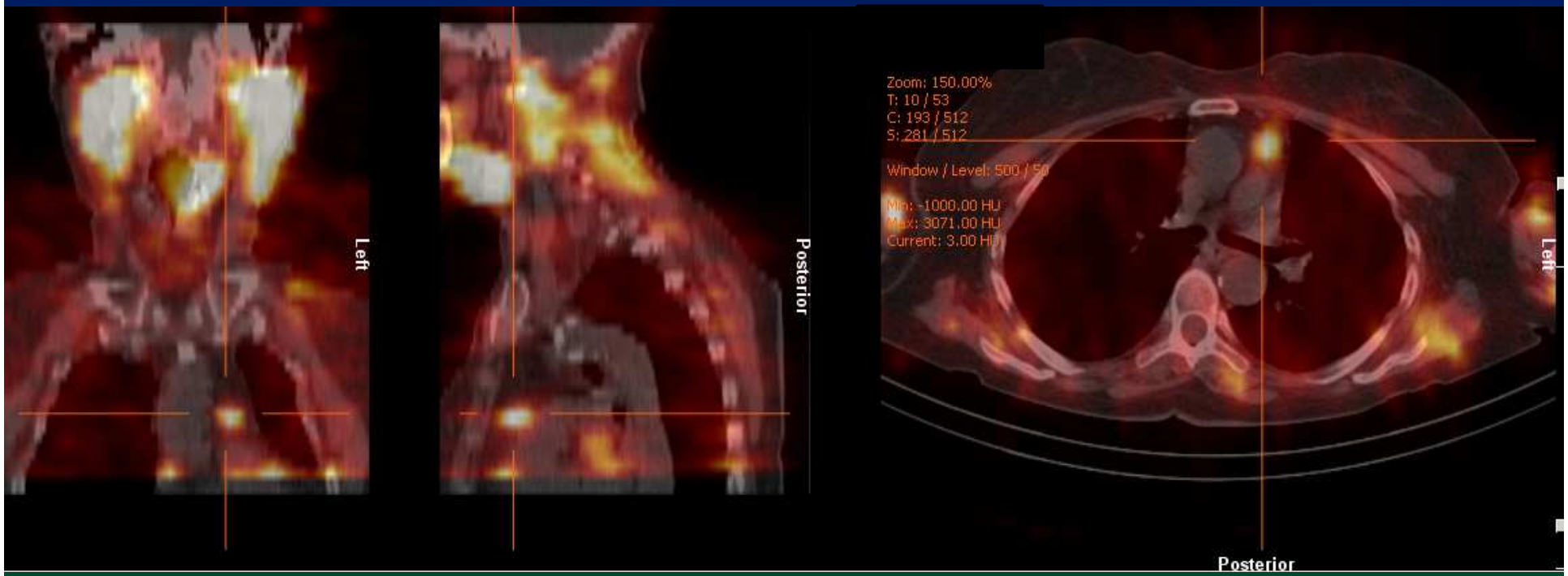
Left
Posterior
Zoom: 150.00%
T: 10 / 53
C: 193 / 512
S: 281 / 512
Window / Level: 500 / 50
Min: -1000.00 HU
Max: 3071.00 HU
Current: 3.00 HU
Left
Posterior

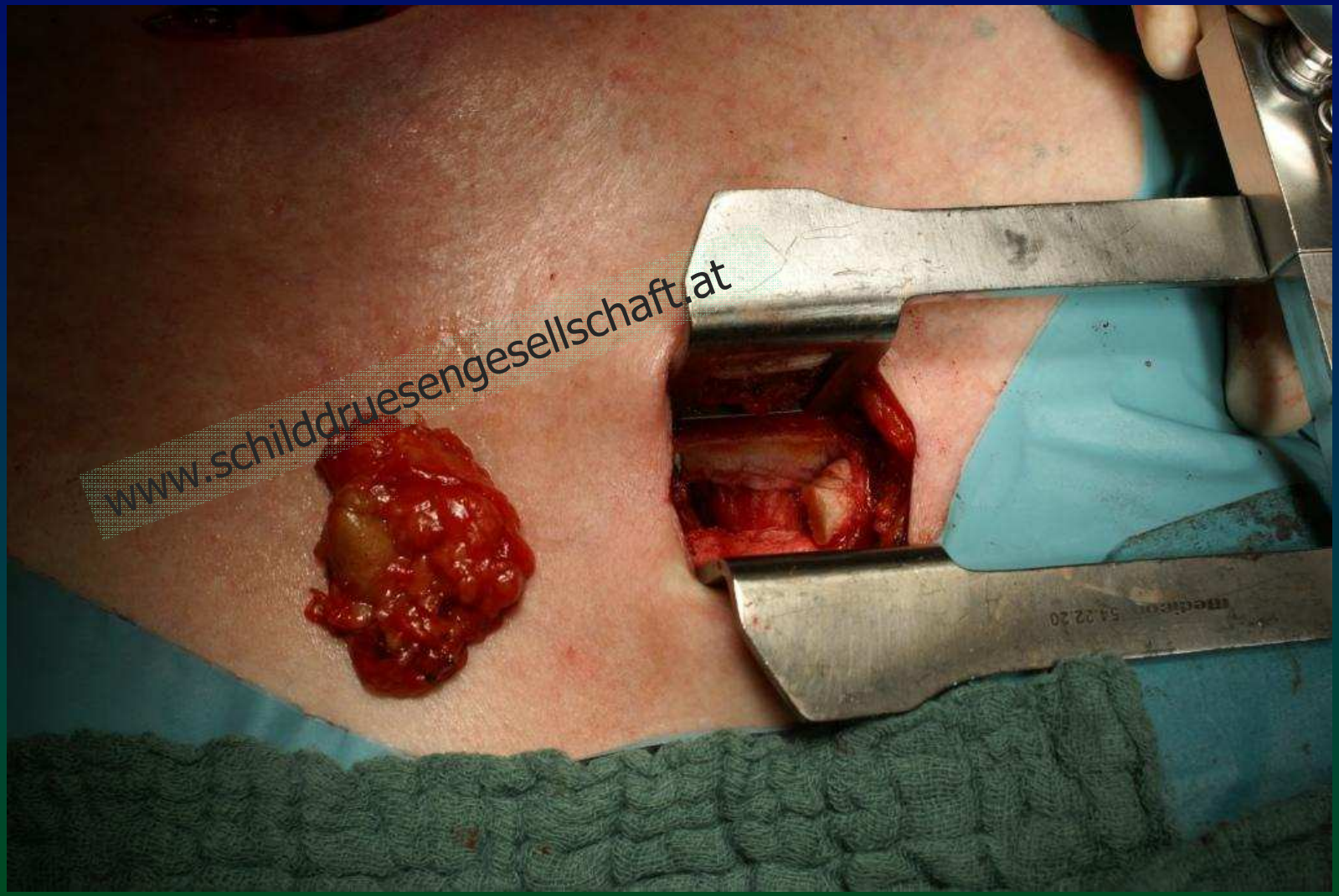

Postoperativer Hypoparathyreoidismus
M. Hermann (Wien)
2. Chirurgie „Kaiserin Elisabeth“ Rudolfstiftung

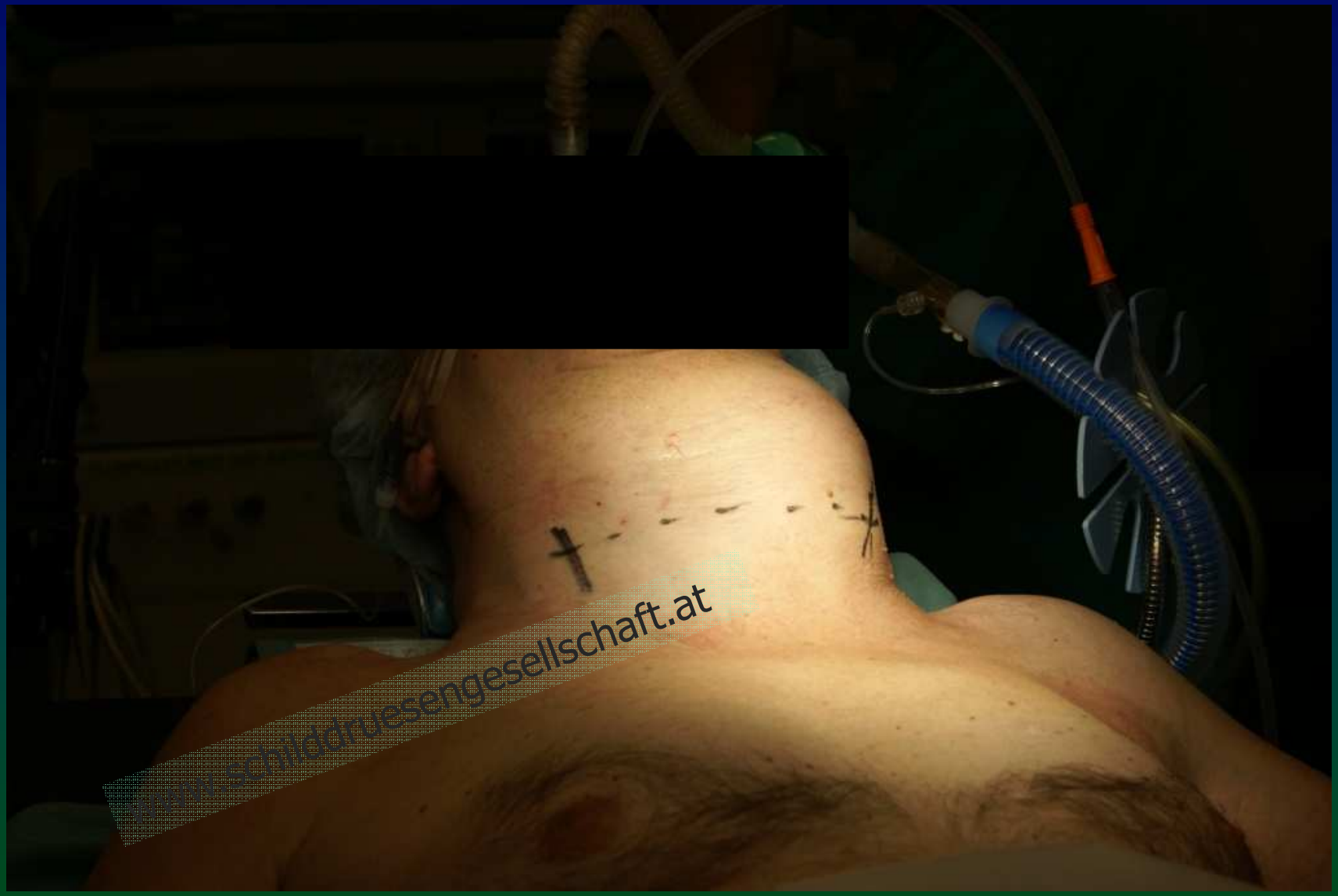

Postoperativer Hypoparathyreoidismus
M. Hermann (Wien)
2. Chirurgie „Kaiserin Elisabeth“ Rudolfstiftung


www.schilddruesengesellschaft.at

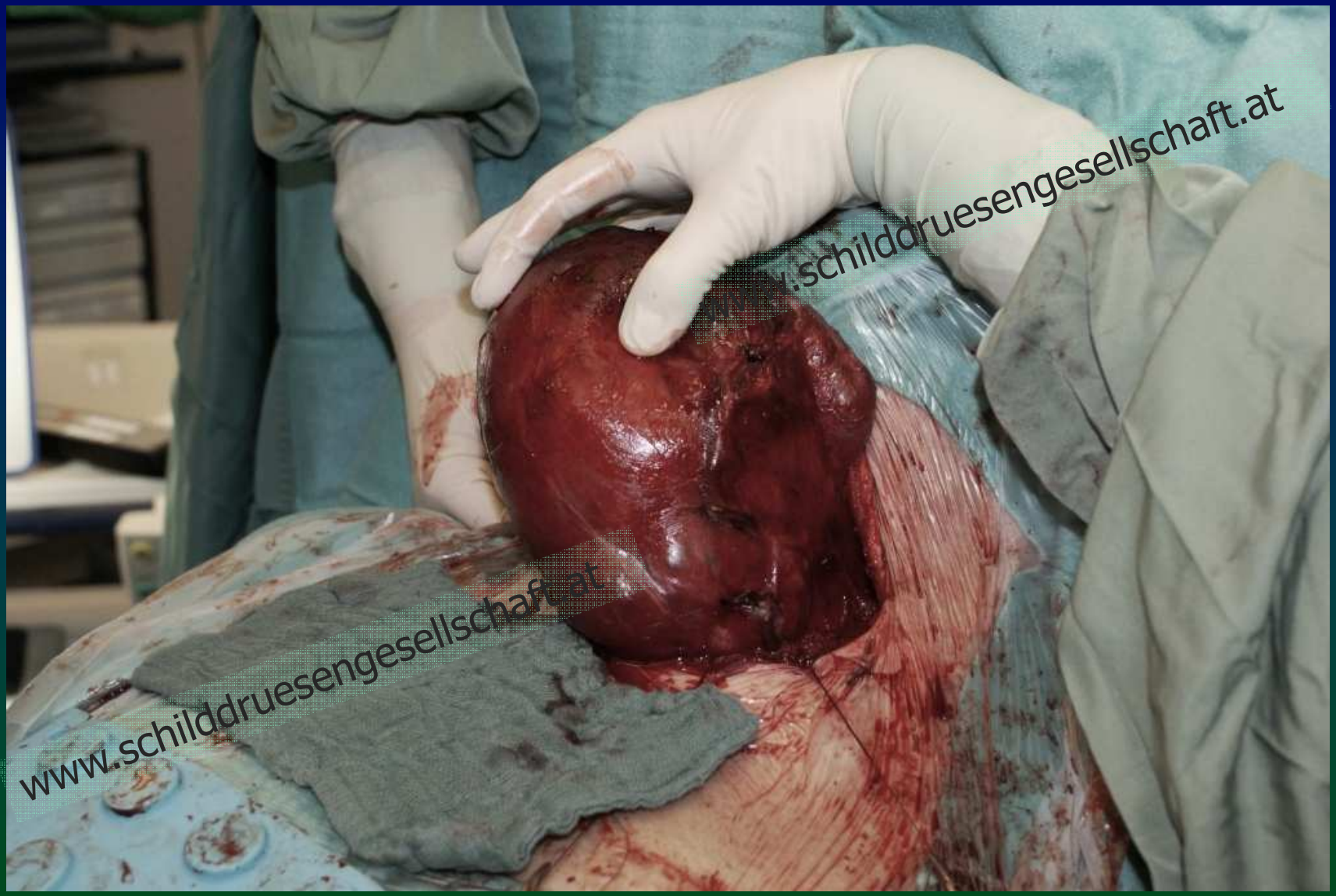

Kaiserin Elisabeth Spital
In guten Händen

kav wiener krankenanstalten verbund
Unternehmen Gesundheit

Schilddrüse

Postoperativer Hypoparathyreoidismus
M. Hermann (Wien)
2. Chirurgie „Kaiserin Elisabeth“ Rudolfstiftung

Stadt Wien
Wien ist anders.

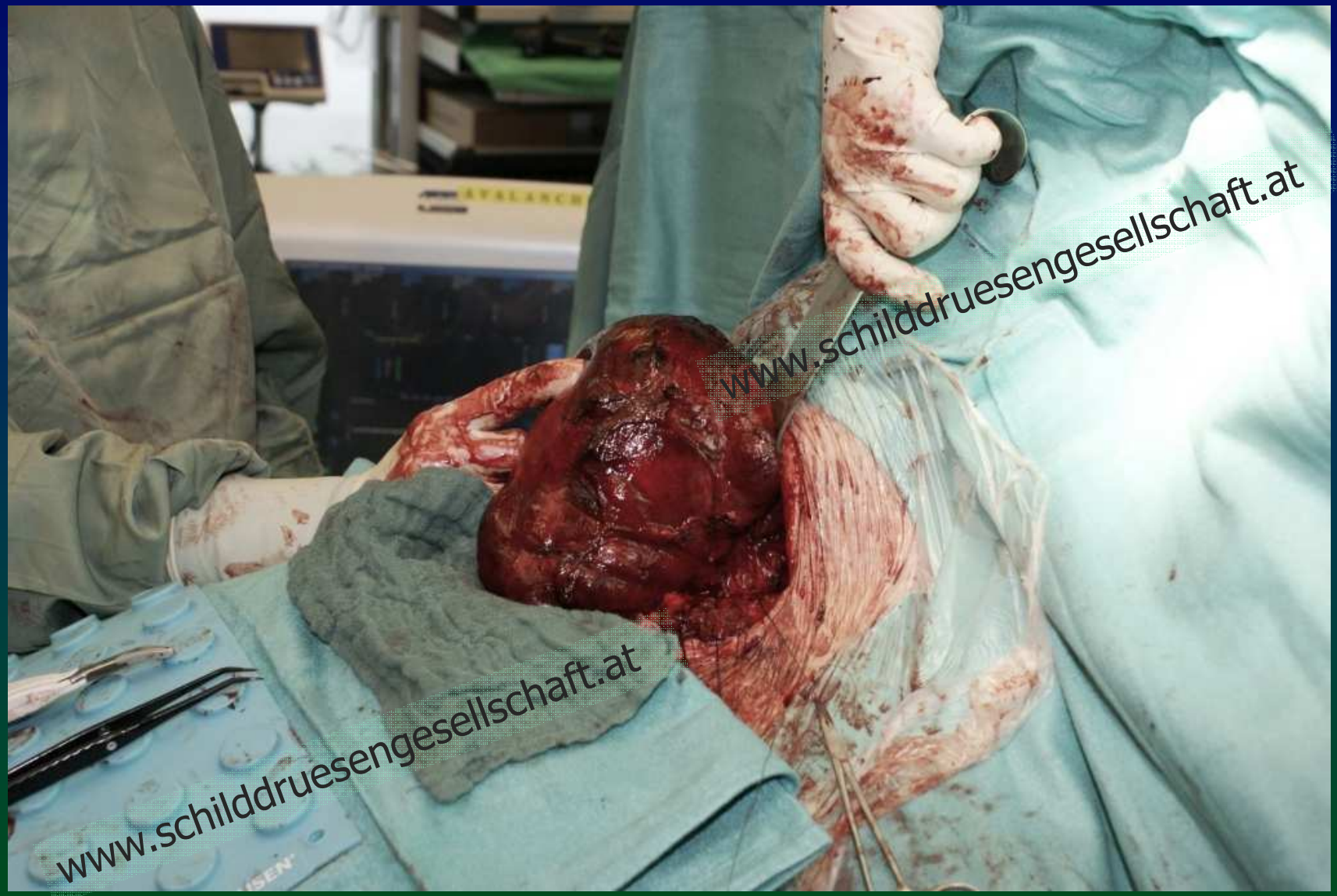
www.schilddruesengesellschaft.at
www.schilddruesengesellschaft.at

Struma intrathoracalis falsa et vera

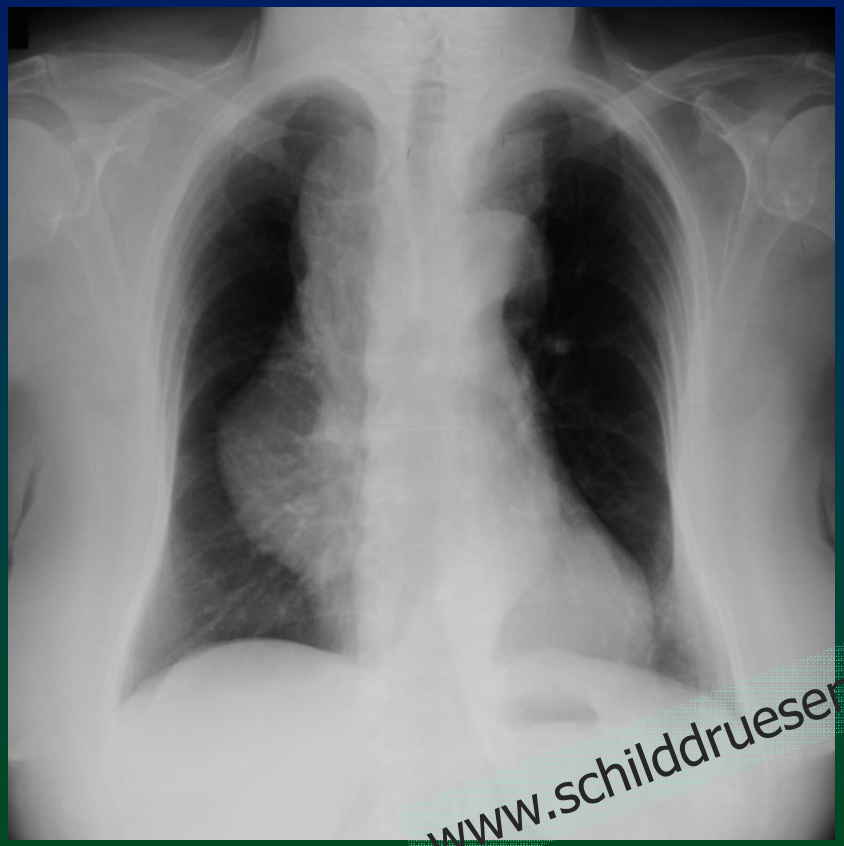

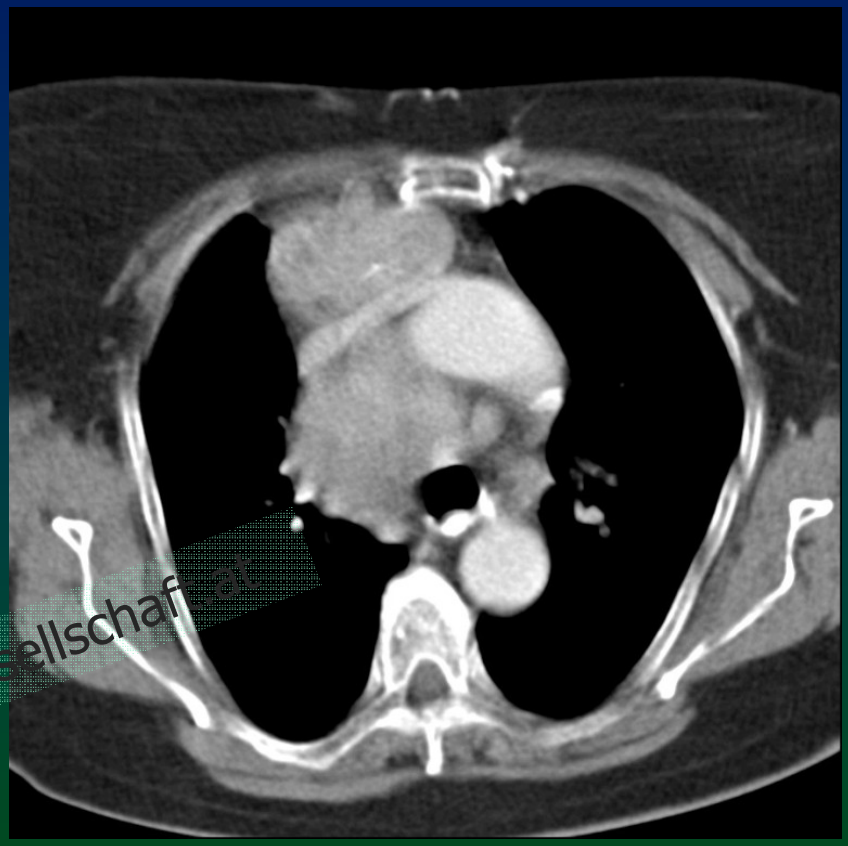

Struma intrathoracalis falsa et vera

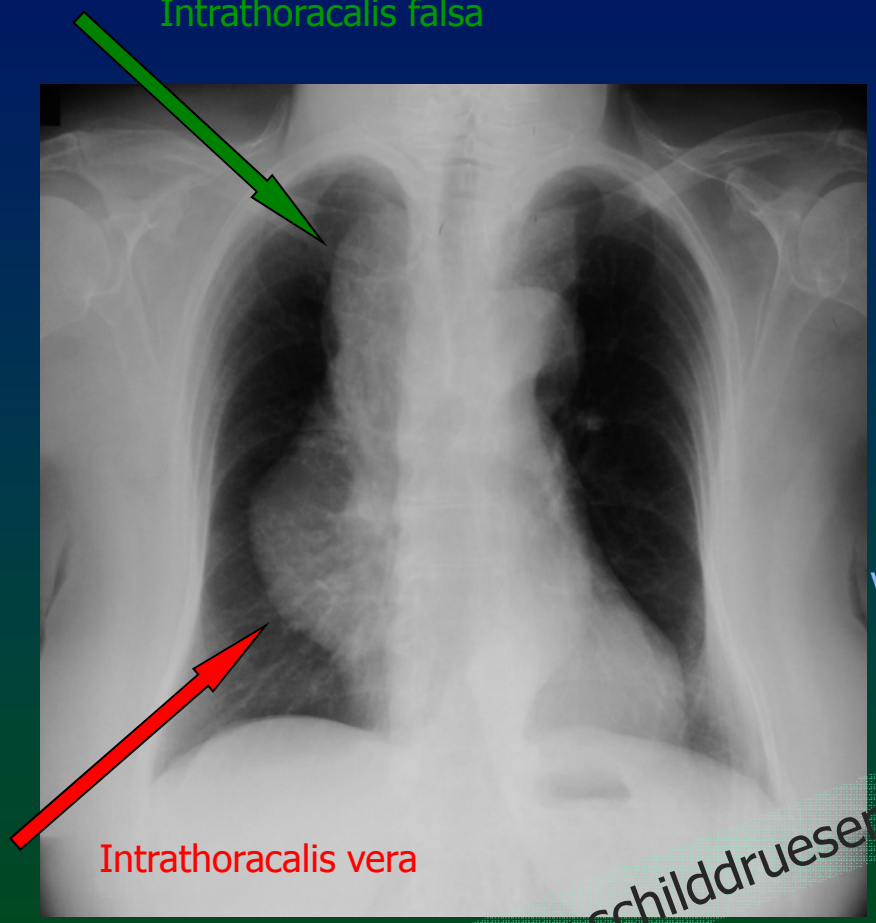

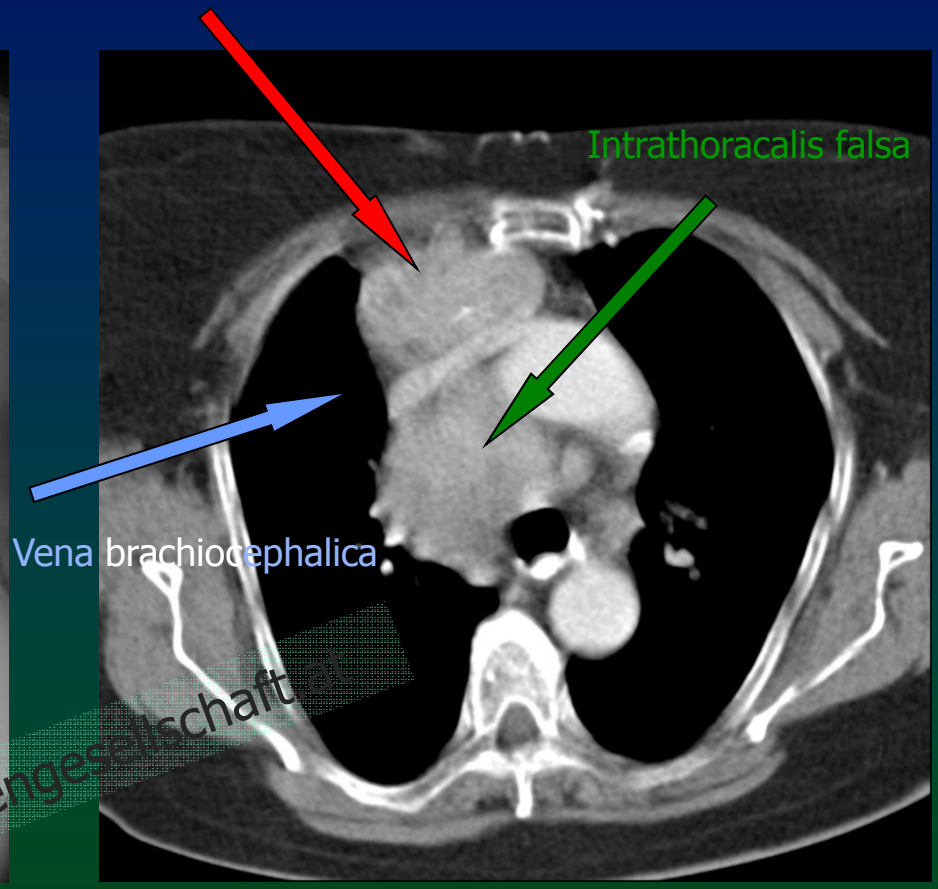

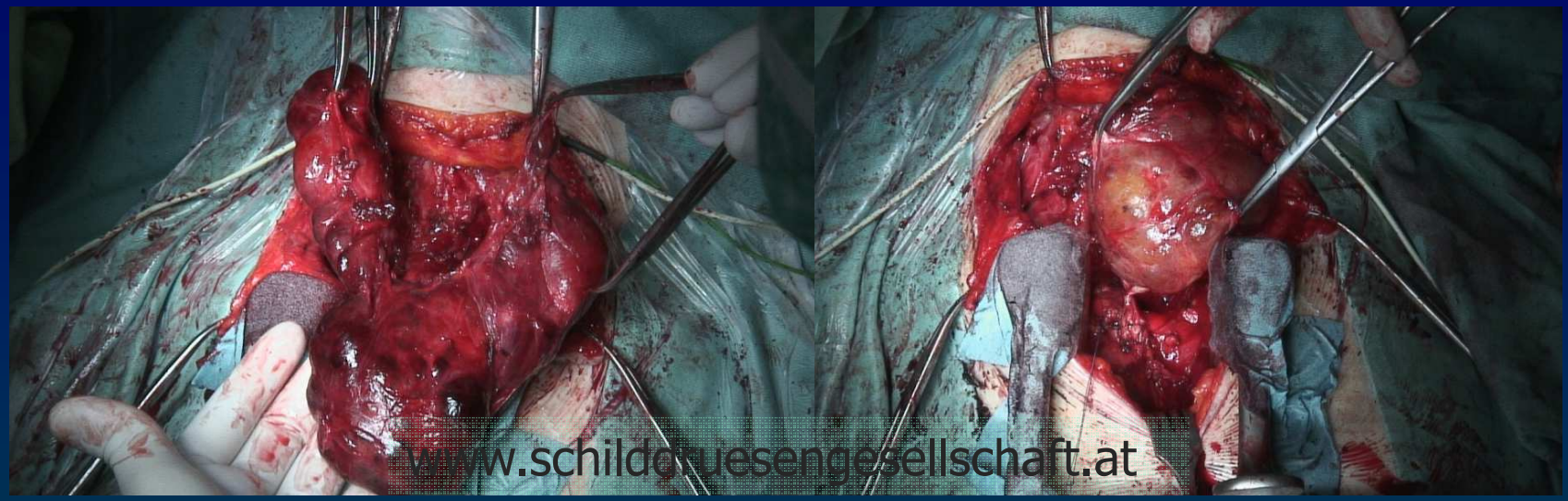

Kaiserin Elisabeth Spital
In guten Händen

kav wiener krankenanstalten verbund
Unternehmen Gesundheit

Schilddrüse

Postoperativer Hypoparathyreoidismus
M. Hermann (Wien)
2. Chirurgie „Kaiserin Elisabeth“ Rudolfstiftung

Stadt Wien
Wien ist anders.

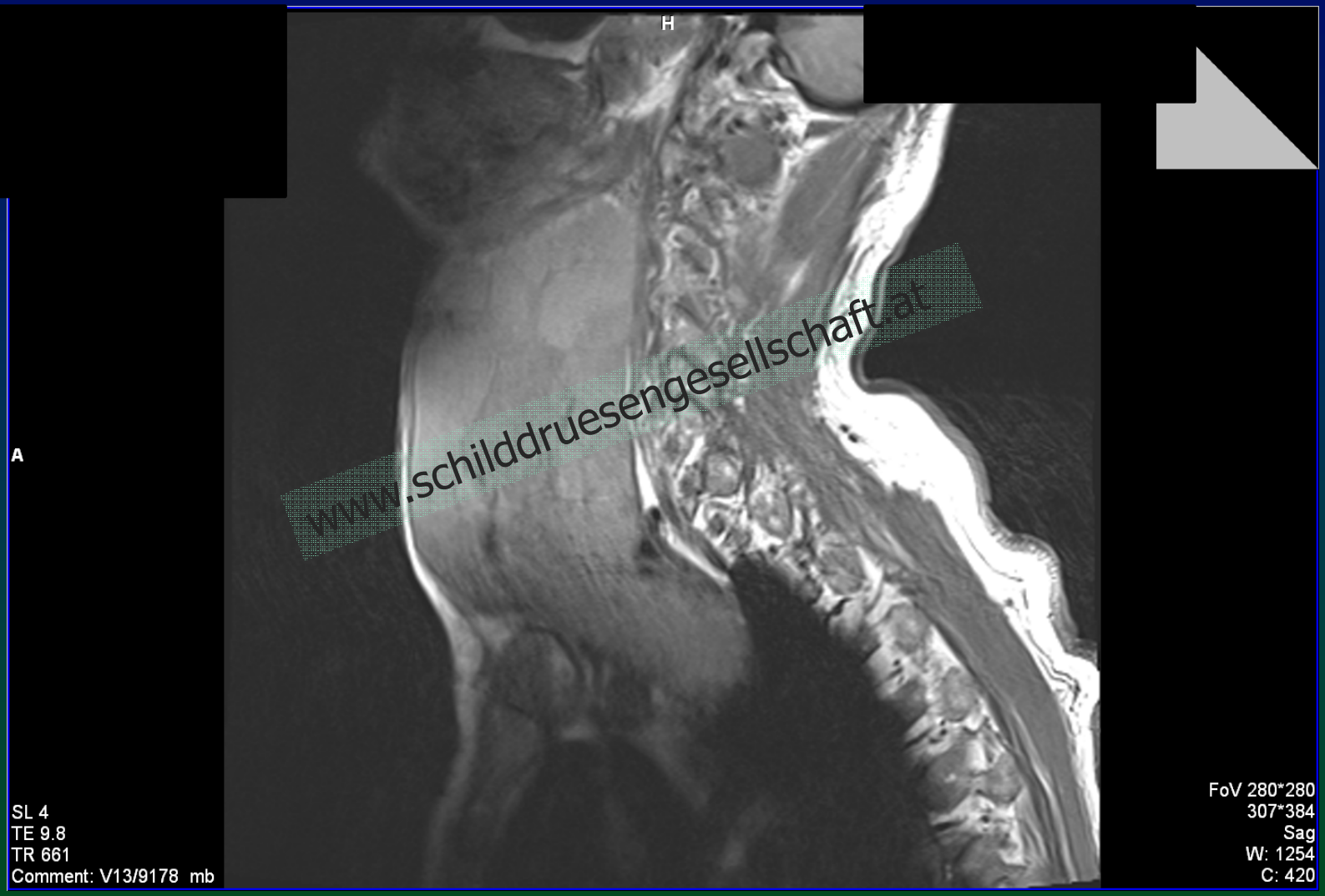

Kaiserin Elisabeth Spital
In guten Händen

kav wiener krankenanstalten verbund
Unternehmen Gesundheit

Schilddrüse

Postoperativer Hypoparathyreoidismus
M. Hermann (Wien)
2. Chirurgie „Kaiserin Elisabeth“ Rudolfstiftung

Stadt Wien
Wien ist anders.

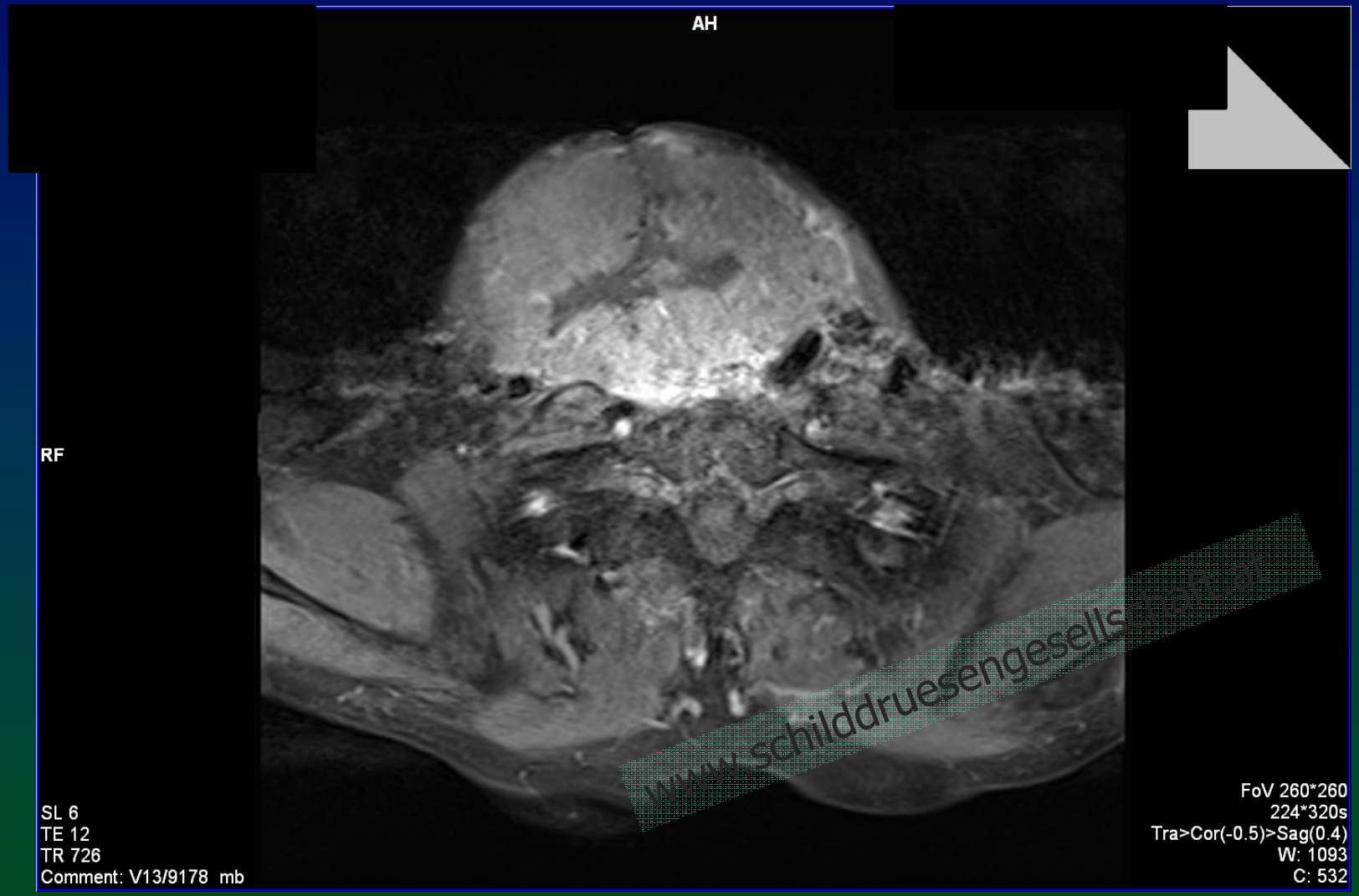

Kaiserin Elisabeth Spital
In guten Händen

kav wiener krankenanstalten verbund
Unternehmen Gesundheit

Schilddrüse

Postoperativer Hypoparathyreoidismus
M. Hermann (Wien)
2. Chirurgie „Kaiserin Elisabeth“ Rudolfstiftung

StaDt Wien
Wien ist anders.


www.schilddruesengesellschaft.at

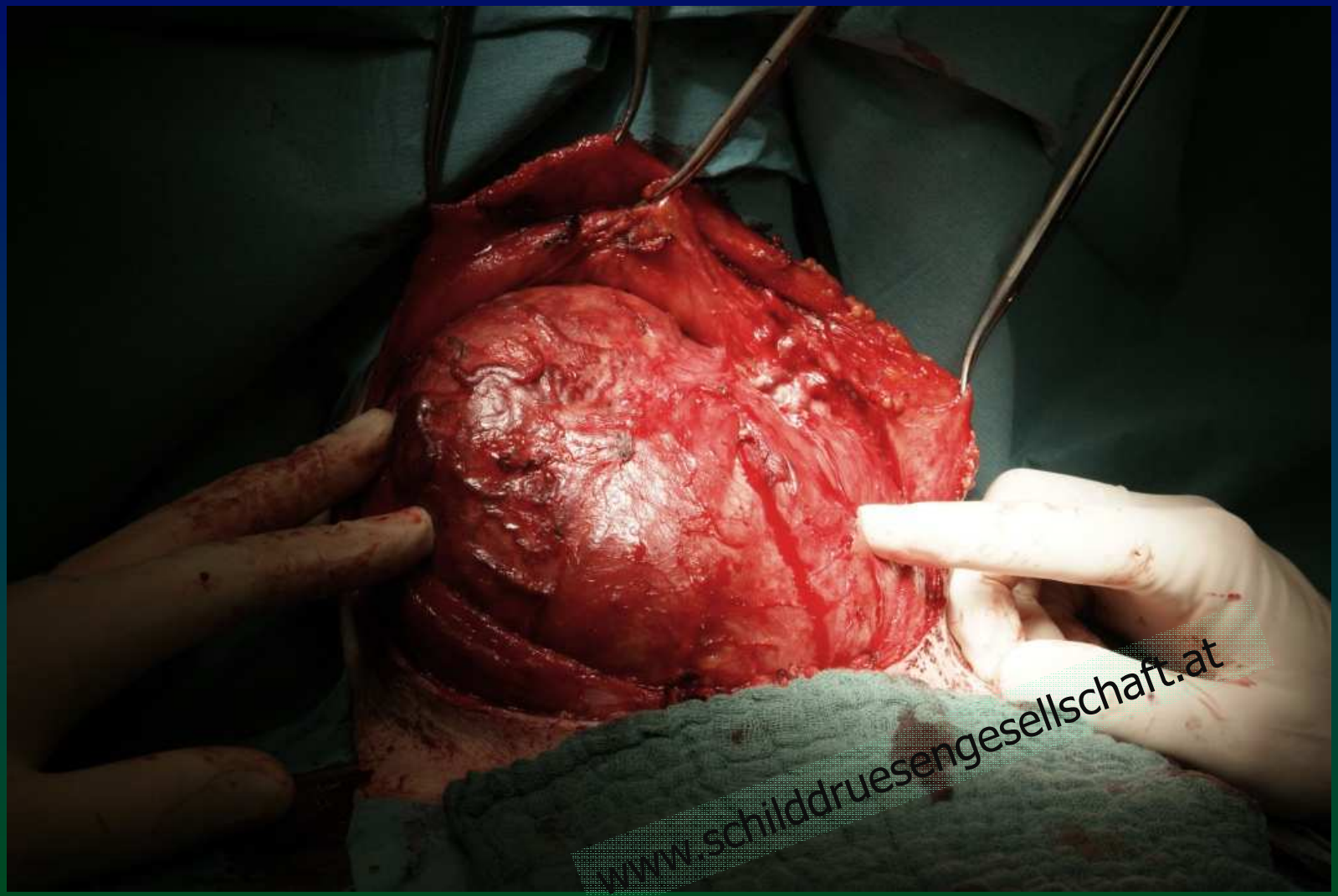
www.schilddruesengesellschaft.at

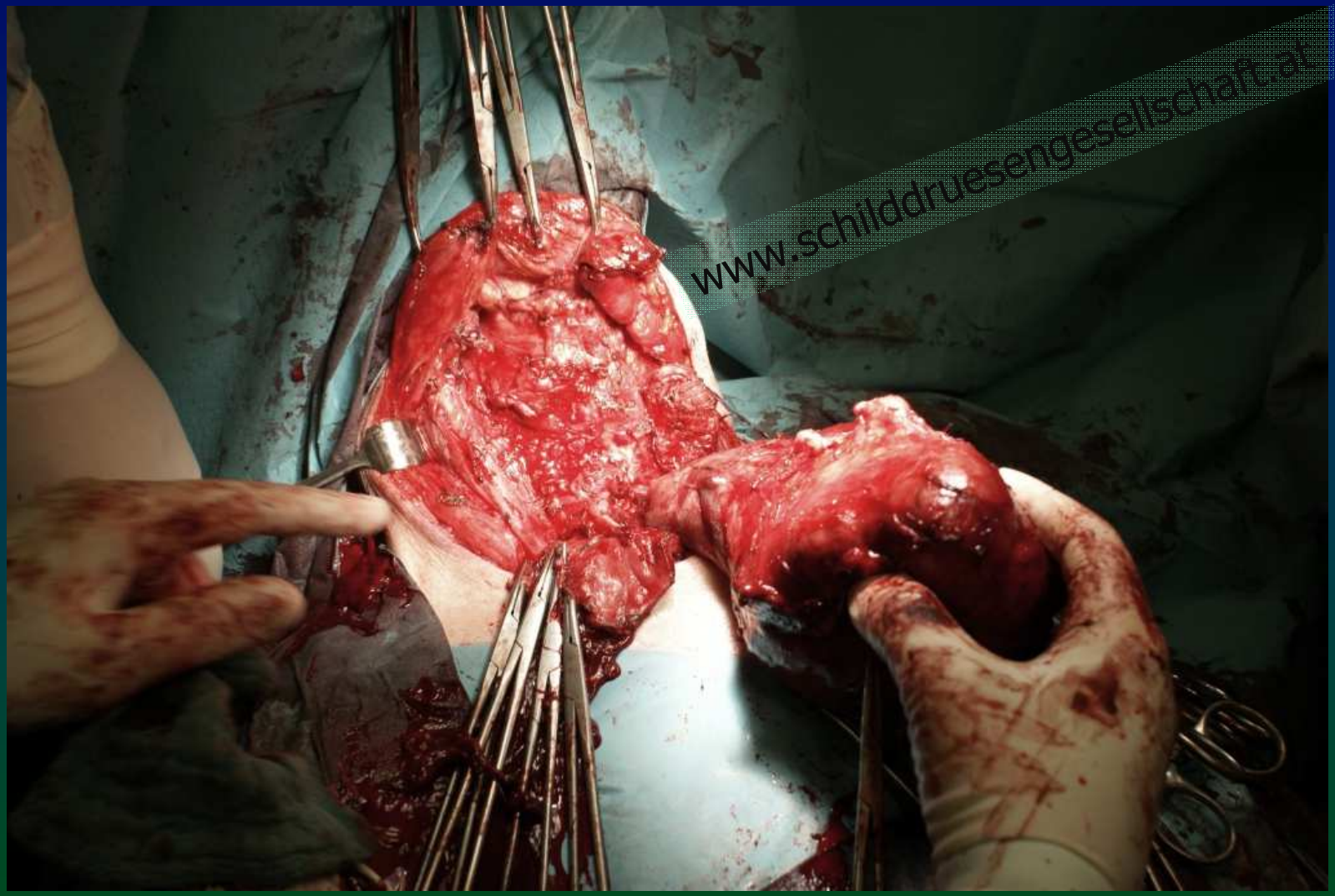

Postoperativer Hypoparathyreoidismus
M. Hermann (Wien)
2. Chirurgie „Kaiserin Elisabeth“ Rudolfstiftung

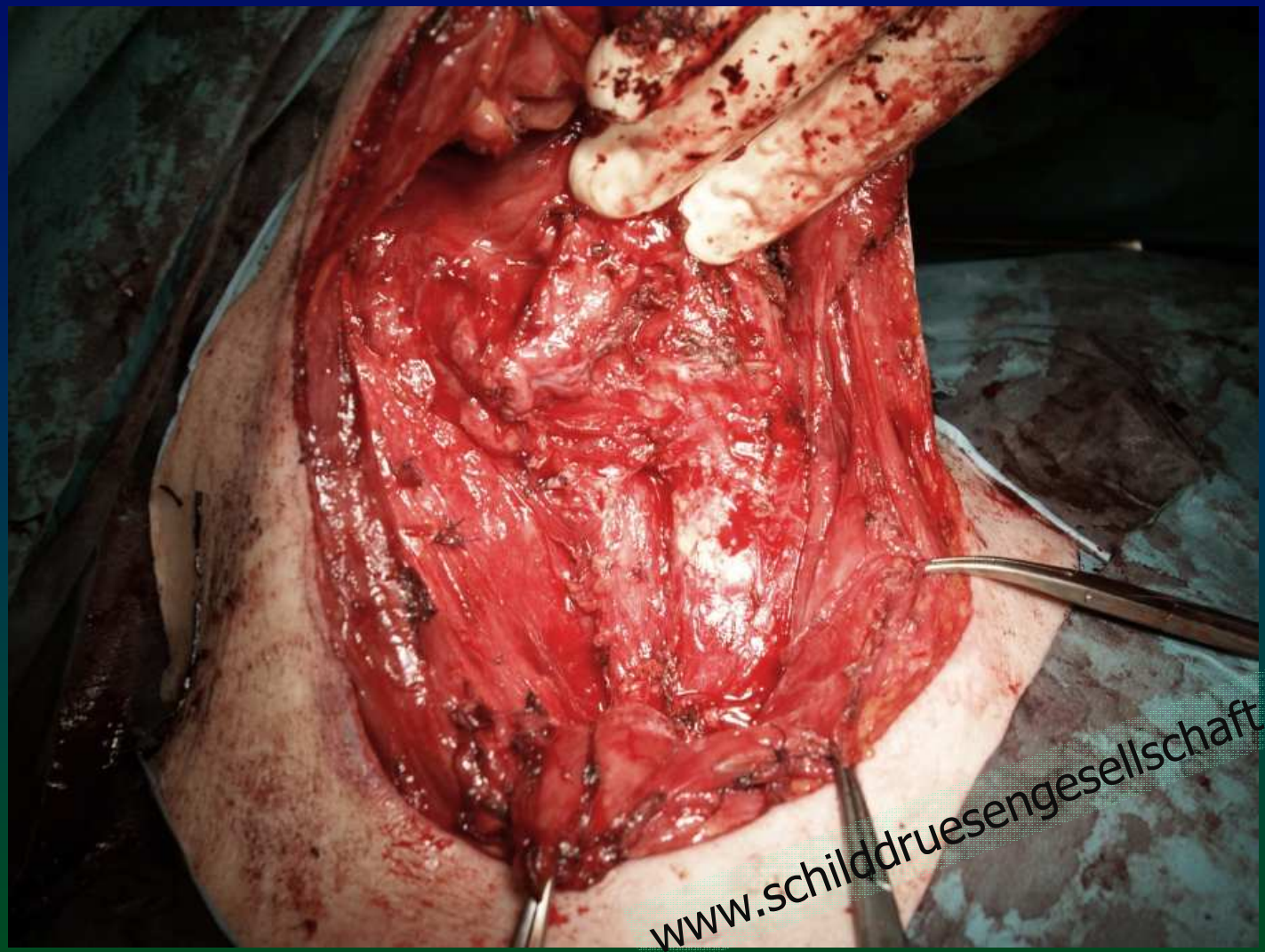
www.schilddruesengesellschaft.at

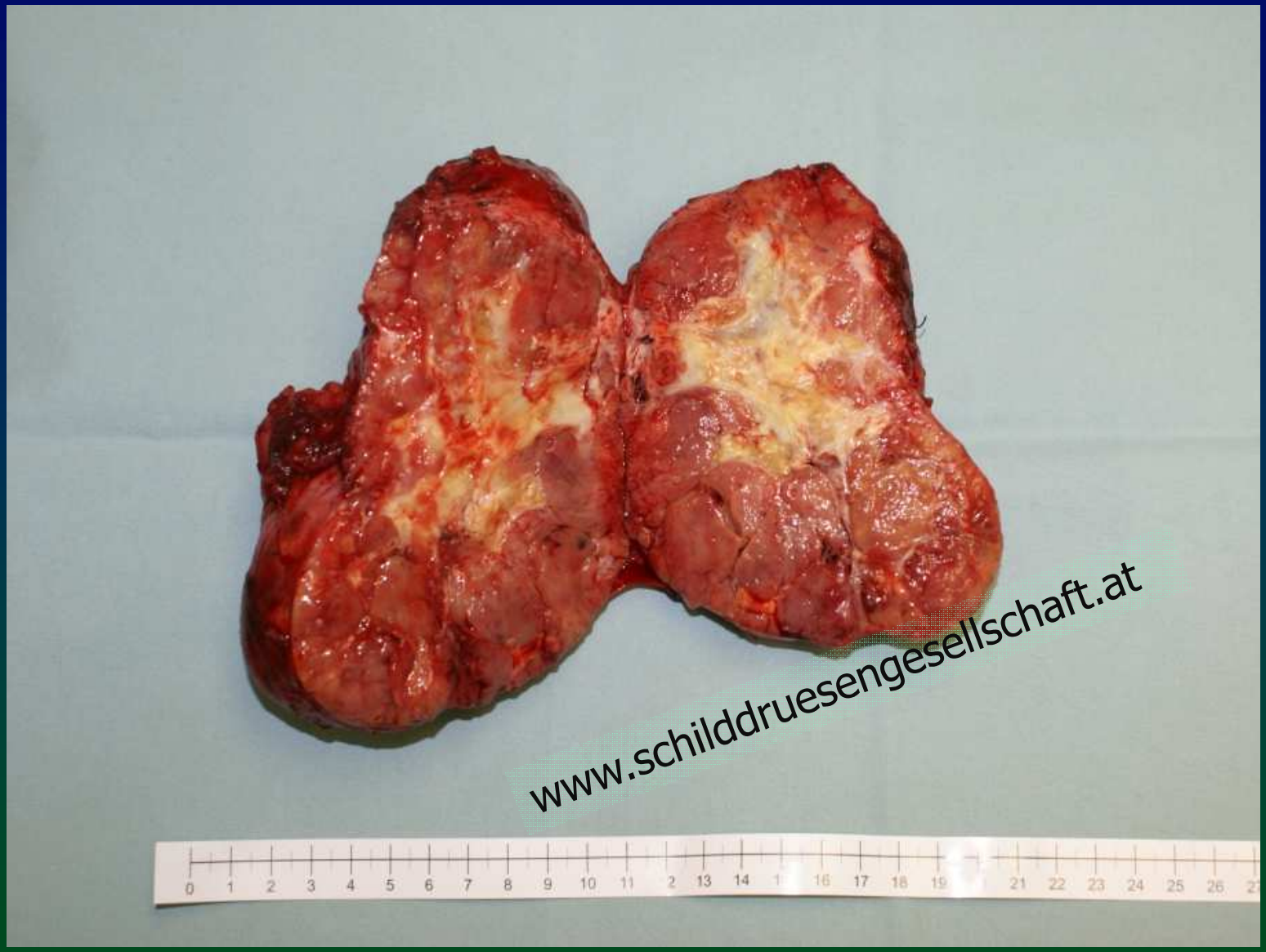
www.schilddruesengesellschaft.at

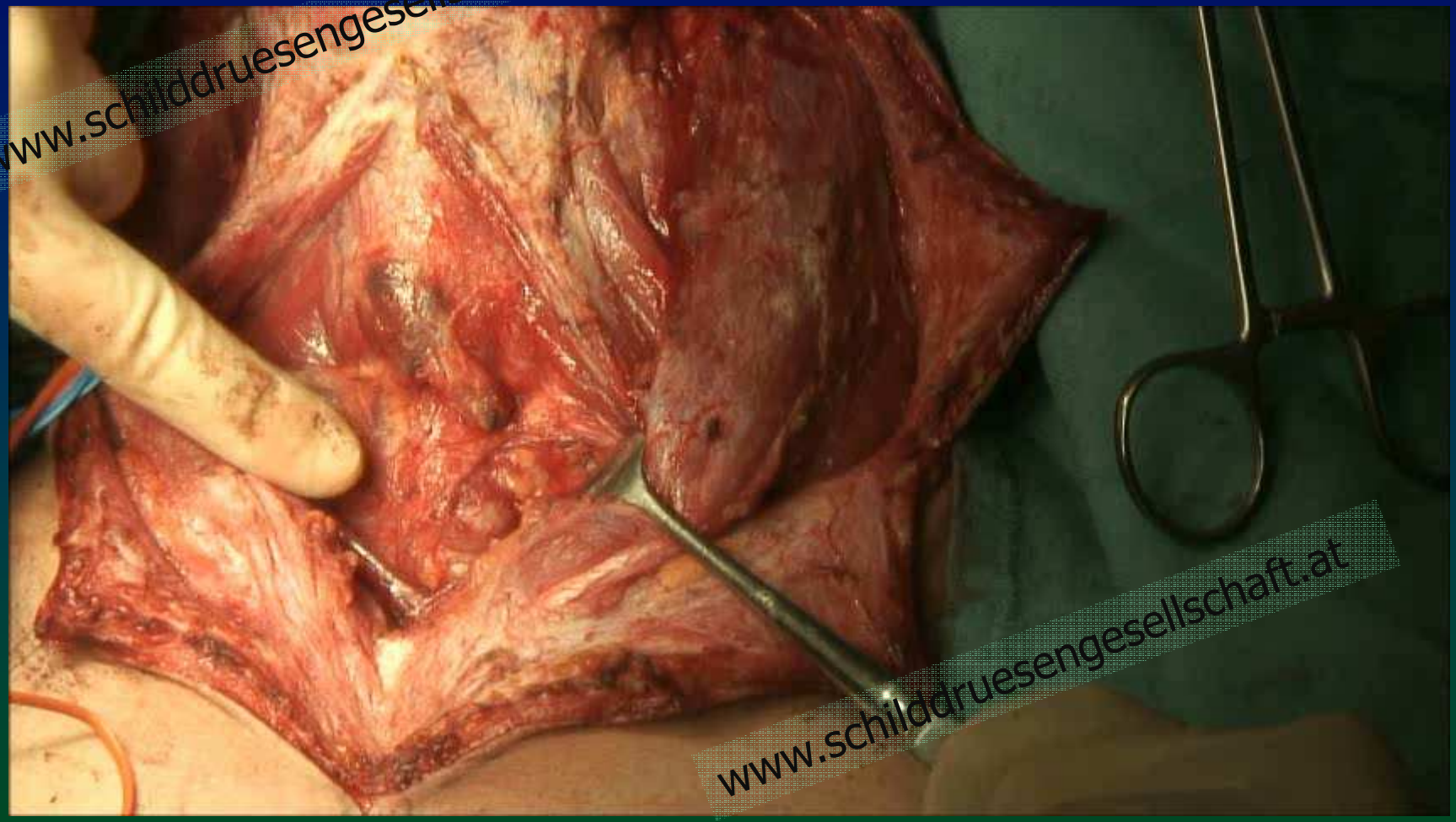
www.schilddruesengesellschaft.at
www.schilddruesengesellschaft.at

Definition des Hypoparathyreoidismus

Blind 2004, CAEK Wien

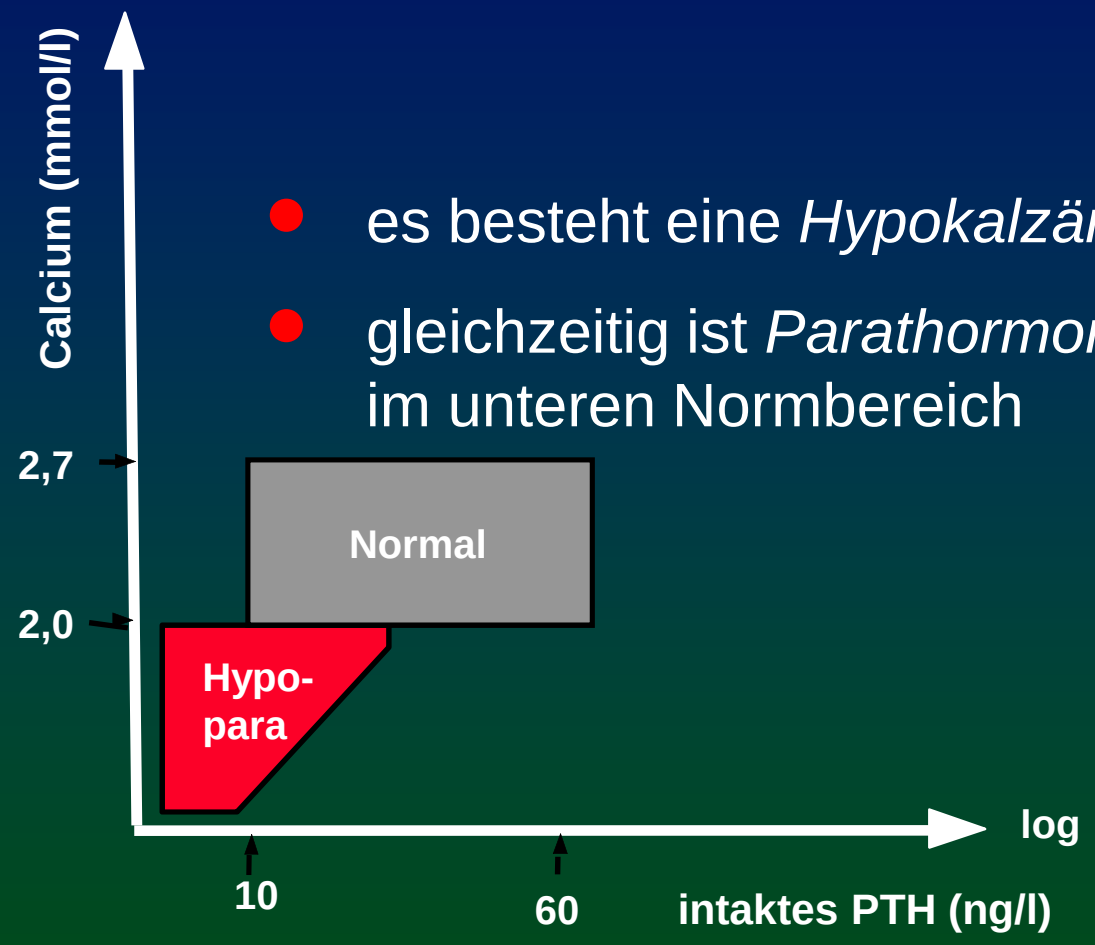

- es besteht eine *Hypokalzämie*
- gleichzeitig ist *Parathormon* erniedrigt oder im unteren Normbereich

THYROID
Volume 21, Number 2, 2010

DOI: 10.1089/thy.2010.0067

Normal Parathyroid Hormone Levels Do Not Exclude Permanent Hypoparathyroidism After Thyroidectomy

Regina Promberger,[1,2] Johannes Ott,[1,3] Friedrich Kober,[1] Michael Karik,[1]
Michael Freissmuth,[4] and Michael Hermann[1]

Background: Permanent hypoparathyroidism has become the most common and the most severe complication after thyroid surgery. In our experience, some patients suffer from permanent hypocalcemia and related symptoms despite normal parathyroid hormone (PTH) values after thyroid surgery. The aim of this work was to present a series of such patients with long-term hypocalcemia and normal PTH values to evaluate to what extent parathyroid function was impaired by thyroidectomy, and determine whether irregularities of bone and calcium metabolism were associated with this phenomenon.
Methods: We present a series of eight patients with normal PTH and subnormal calcium levels at follow-up 2 months after thyroid surgery. Outcome parameters were intra- and postoperative PTH and calcium kinetics, and the following markers of calcium and bone metabolism at long-term follow-up: serum calcium, total serum albumin, ionized calcium, magnesium, PTH, 25-hydroxyvitamin D, 1,25-dihydroxyvitamin D, urinary calcium, urinary creatinine, osteocalcin, c-terminal telopeptide of type I collagen, and alkaline phosphatase.
Results: All patients had normal calcium and PTH levels at the start of the operation. The intraoperative decline in PTH was >90%; the trough (3.3% of preoperative value) was reached 3 hours after surgery. Patients underwent complete determination of bone metabolism parameters during long-term follow-up 13.8 ± 2.4 months after surgery. Hypocalcemia was found in all eight patients, as well as PTH levels within the normal range. In three patients ($3/8 = 37.5\%$), none of the other parameters was altered. In the remaining five patients, only isolated abnormalities in bone and calcium metabolism parameters were found (i.e., alterations in urinary calcium, thyrotropin, 25-hydroxyvitamin D, osteocalcin, and c-terminal telopeptide of type I collagen).
Conclusions: An intraoperative injury to the parathyroid glands or their vascularization is the likely contributing factor to the development of permanent hypocalcemia with normal PTH values after thyroid surgery. The remaining parathyroid tissue is subject to a maximum stimulus by hypocalcemia and, therefore, is able to maintain PTH values in the normal range. These are still too low to re-establish normal serum calcium levels. In these patients, the term "hypoparathyroidism" might be replaced with "parathyroid insufficiency."

Original Article

Eur Surg (2014) 46:38–47
DOI 10.1007/s10353-013-0247-3

european surgery
ACA Acta Chirurgica Austriaca

Guidelines for complications after thyroid surgery: pitfalls in diagnosis and advices for continuous quality improvement

C. Bures · T. Klatte · G. Friedrich · F. Kober · M. Hermann

Received: 25 October 2013 / Accepted: 2

(range: 0–3.2 %, $p<0.001$). Postoperative hypoparathyroidism was diagnosed in 487 patients (35.2 %), of whom full recovery was noted in 93.0 %. There were 26 postoperative bleedings (1.9 %) requiring reoperation. Three patients (0.2 %) developed superficial SSI with *Staphylococcus aureus* after a postoperative interval of 2, 6, and 7 days, respectively.

Table 4 Different definitions for hypoparathyroidism

Reference	Calcium	PTH (pg/ml)	Symptoms	Transient/ permanent (months)
Sitges-Serra et al. [39]	<2 mmol/l	<13	+	12
Barczynski et al. [40]	<2 mmol/l	–	+/–	12
Youngwirth et al. [41]	Calcium supplementation	<10	+	6
Wilhelm et al. [42]	<2.1 mmol/l	–	+/–	6
Digonnet et al. [43]	Calcium supplementation	<15	+	12
Lee et al. [44]	Calcium supplementation	–	+	6
Efremidou et al. [45]	<2 mmol/l	–	+	6
Asari et al. [46]	<1.9 mmol/l	–	+/–	6
Harris et al. [47]	Calcium supplementation	–	+	6
Emre et al. [48]	<2 mmol/l	–	+	6
Palazzo et al. [49]	<2 mmol/l	–	+	6
Rosato et al. [50]	Calcium supplementation	–	+	12
Thomusch et al. [51]	Calcium or vitamin D supplementation	–	+	12
Trupka et al. [52]	<2.12 mmol/l	<15	+	6
Thomusch et al. [53]	Calcium or vitamin D supplementation	–	+	12

PTH parathormone

Table 1 Age-specific calcium reference values from our laboratory

Age (years)	Reference range (mmol/l)[a]
2–12	2.2–2.7
12–18	2.1–2.55
18–59	2.15–2.50
59–90	2.20–2.55
>90	2.05–2.40

[a]For conversion to mg/dl, the values should be multiplied by 4.01

It remains unclear whether the necessity of postoperative vitamin D supplementation in patients with preoperative vitamin D deficiency should be judged as a complication, i.e., as hypoparathyroidism. Vitamin D deficiency is common in Austria [54], and supplementation in patients with low calcium levels is common practice. Using our strict criteria, we included these patients as having hypoparathyroidism. Other authors and research groups, however, may judge this issue dif-

Ergebnisqualität – permanente Nebenschilddrüsenunterfunktion (Hypoparathyreoidismus)
Outcome nach beidseitigen Resektionsverfahren mit unterschiedlichem Resektionsausmaß (2004 bis 2008)

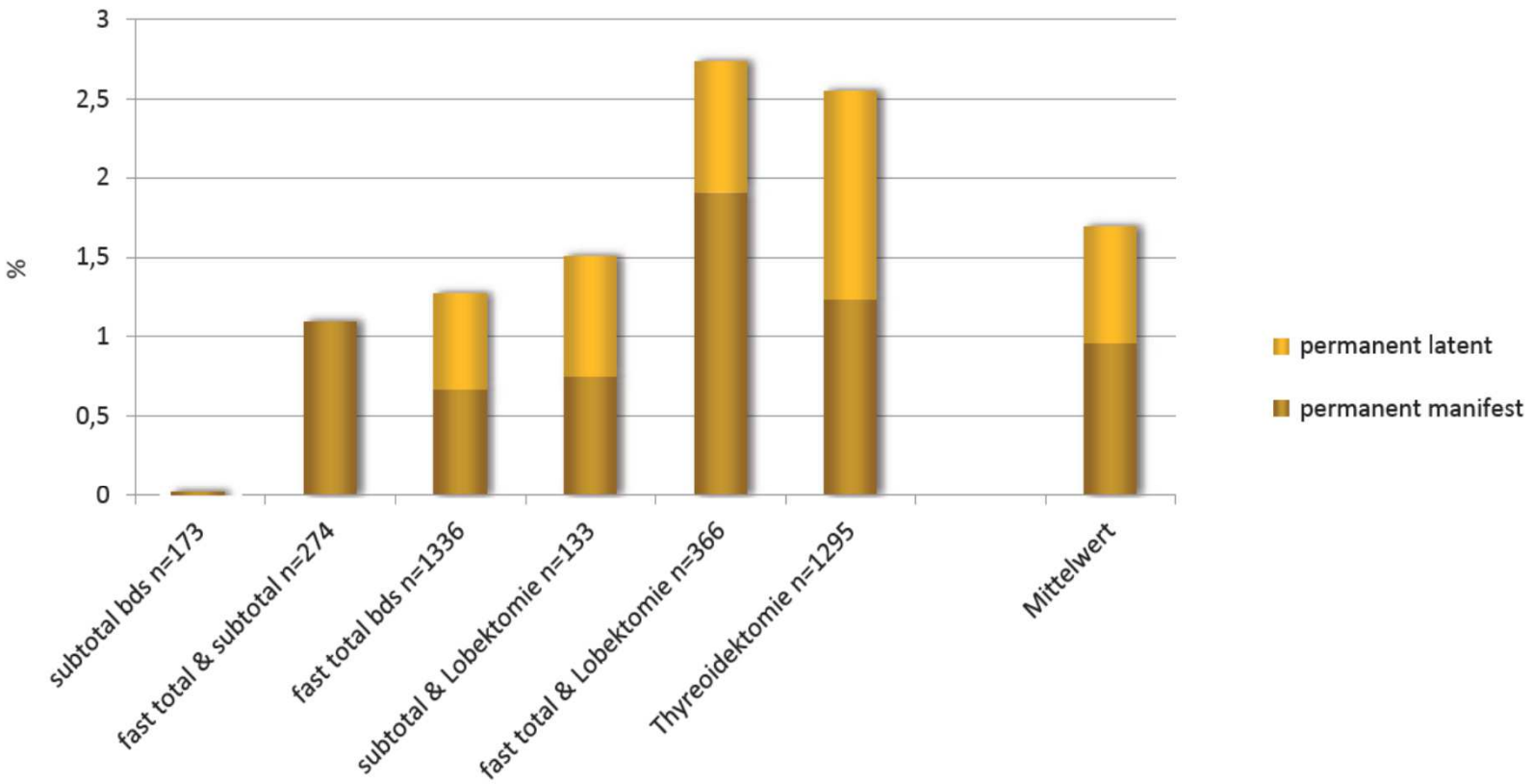

Internationales Benchmarking (Externe Qualitätssicherung)

Leistung der chirurgischen Abteilung (Kaiserin Elisabeth Spital) im Vergleich zu international publizierten Daten

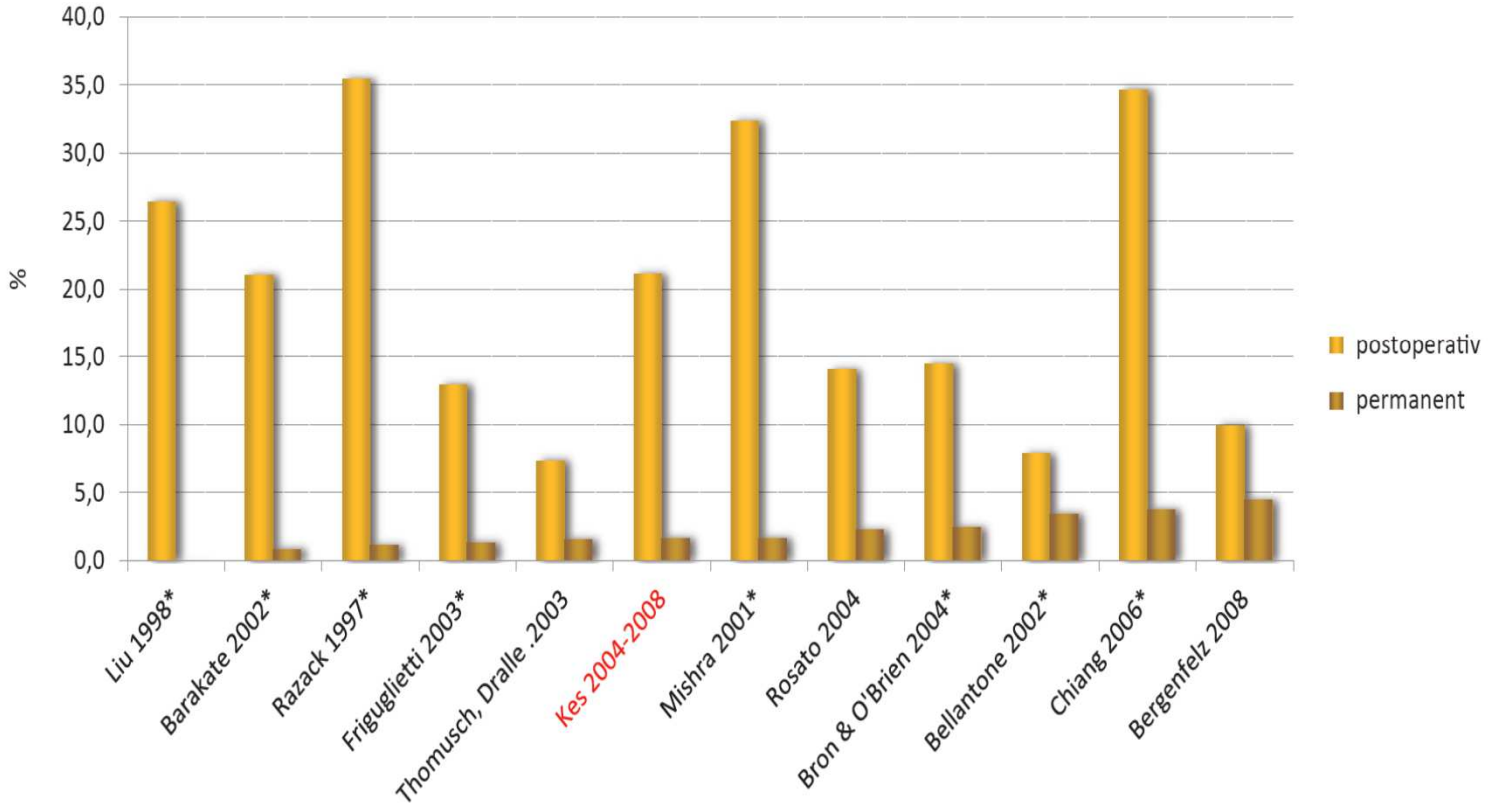


Michael Hermann
Schilddrüsenchirurgie
Qualitätsindikatoren und Ergebnisqualität
Diagnosen und Operationsstrategie im Wandel der Zeit
Komplikationsmanagement, aktuelle Standards und Leitlinien
an über 30.000 Operationen der Jahre 1979 bis 2008
aus dem Kaiserin Elisabeth Spital der Stadt Wien
SpringerWienNewYork
Hermann
Schilddrüsenchirurgie

Die obere Nebenschilddrüse

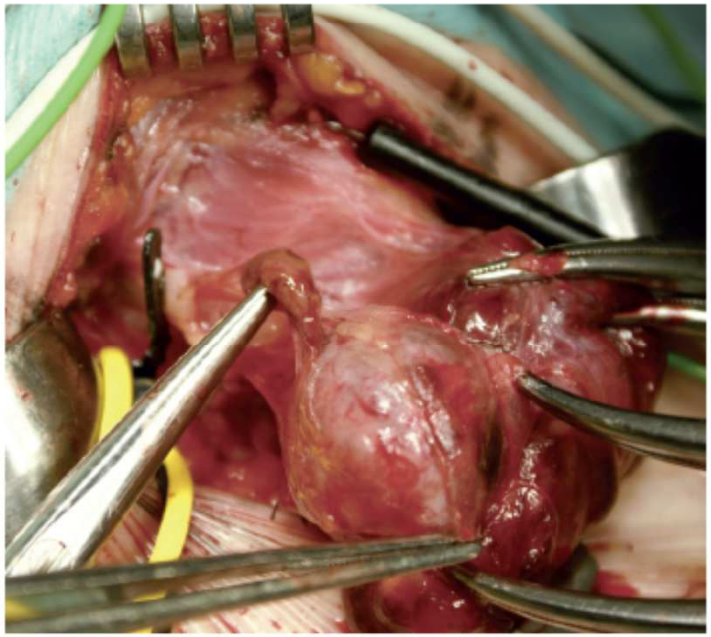

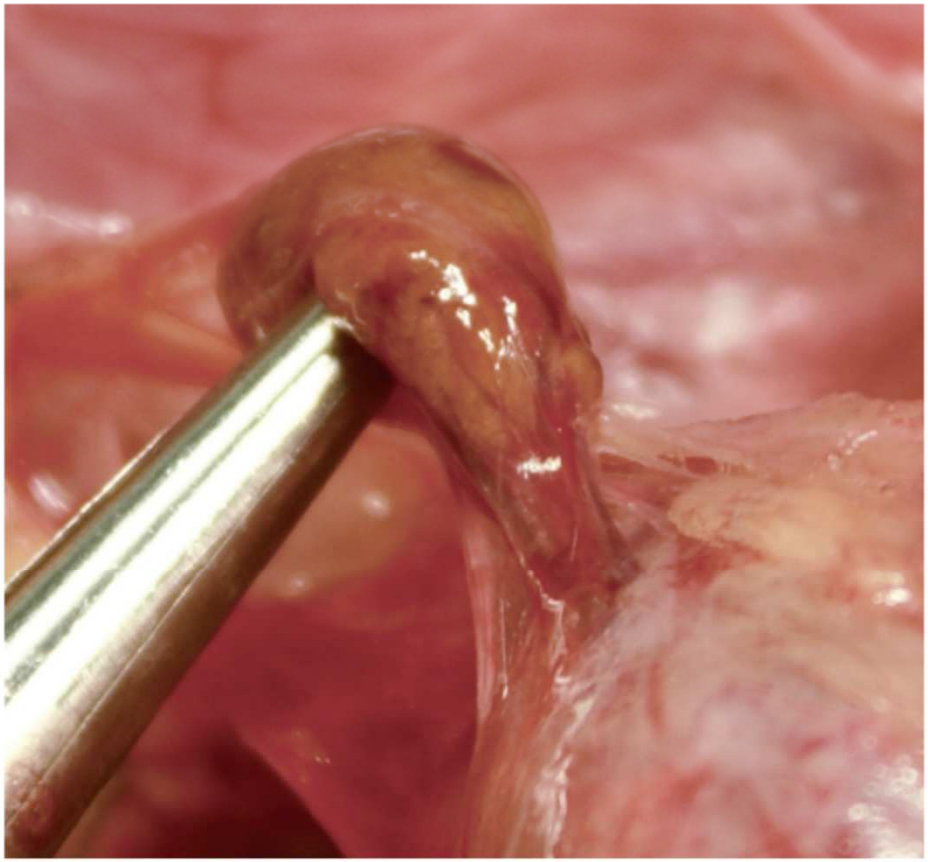

Die untere Nebenschilddrüse

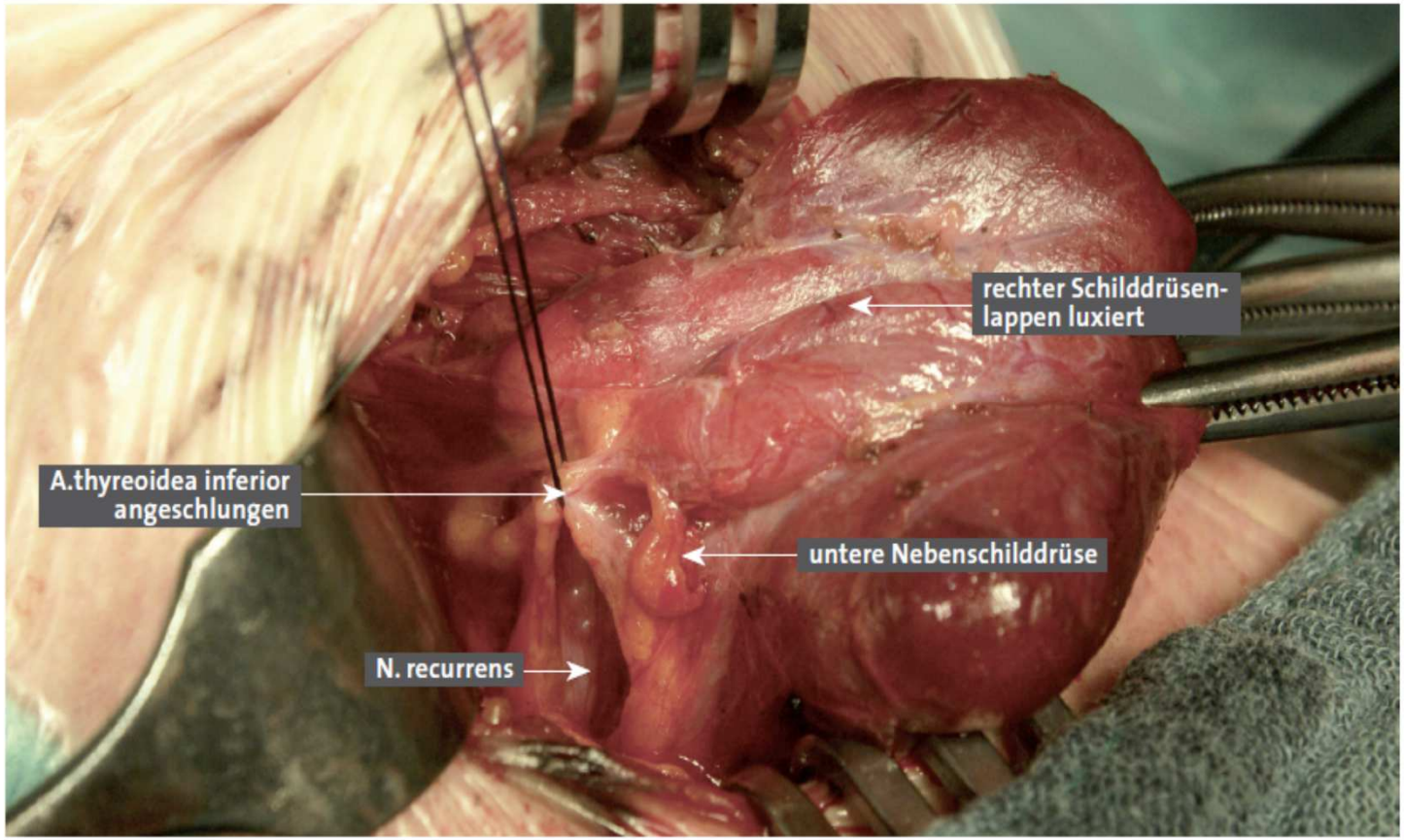

Langenbecks Arch Surg (2011) 396:1137–1143
DOI 10.1007/s00423-011-0809-4

REVIEW ARTICLE

State of the art: surgery for endemic goiter—a plea for individualizing the extent of resection instead of heading for routine total thyroidectomy

Henning Dralle · Kerstin Lorenz · Andreas Machens

Conclusion The higher surgical morbidity associated with total thyroidectomy, notably recurrent laryngeal nerve palsy and hypoparathyroidism, calls for individualizing the extent of resection for endemic goiter as a new standard of care instead of heading for routine total thyroidectomy.

personal experience.
Discussion The following arguments favor total thyroidectomy: (a) Endemic goiter involves the entire thyroid gland; (b) Increasing standardization and specialization supported by better visualization, surgical devices, and intraoperative

Keywords Nodular goiter · Retrosternal goiter · Recurrent goiter · Recurrent laryngeal nerve palsy · Postoperative hypoparathyroidism

Danke für Ihre Aufmerksamkeit