Konzepte zur sonografischen Dignitätsbeurteilung

Georg Zettinig

Bösartige Neubildungen der Schilddrüse im Zeitverlauf
altersstandardisierte Raten auf 100.000 Personen
(WHO-Weltbevölkerung, 2001)

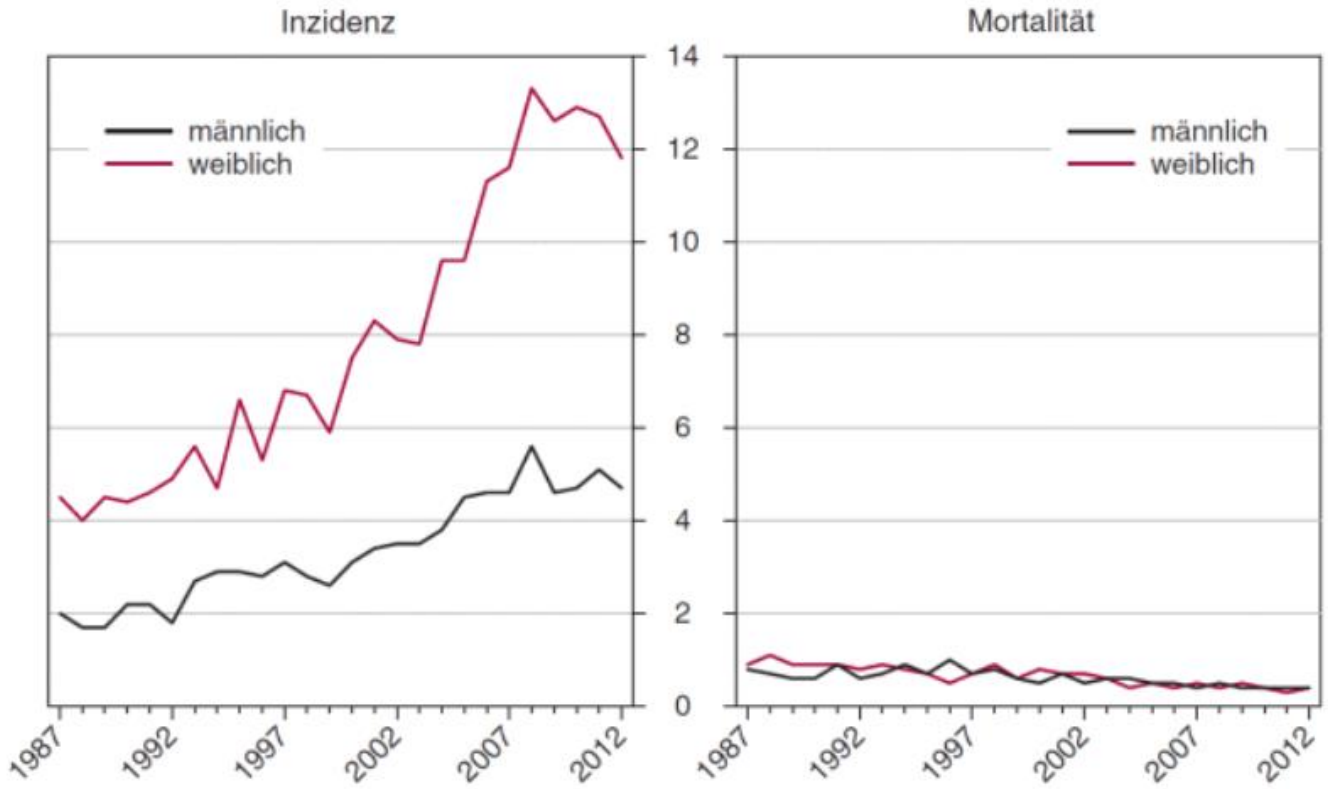

Q: STATISTIK AUSTRIA, Österreichisches Krebsregister (Stand 02.10.2015) und Todesursachenstatistik.
Erstellt am 14.10.2015.

THYROID
Volume 26, Number 11, 2016

DOI: 10.1089/thy.2016.0075

Thyroid Cancer Screening in South Korea Increases Detection of Papillary Cancers with No Impact on Other Subtypes or Thyroid Cancer Mortality

Hyeong Sik Ahn,[1,*] Hyun Jung Kim,[1,*] Kyoung Hoon Kim,[2] Young Sung Lee,[3]
Seung Jin Han,[2] Yuri Kim,[2] Min Ji Ko,[4] and Juan P. Brito[5]

Background: The incidence of thyroid cancer has increased worldwide. The country where th increased most is South Korea. The goal of this study is to understand the magnitude of asso opportunistic thyroid cancer screening and thyroid cancer incidence, thyroid cancer subtype, and mortality.

Methods: We used the 2010 Korea Community Health Survey, which queried 226,873 individuals screened for thyroid cancer in the last two years. Thyroid cancer incidence data from 2008 to 201 from the Korea Cancer registry data, and mortality data from 2007–2010 were obtained from the database. The ecological association between thyroid screening and thyroid cancer incidence and r and sex were examined across Korea's 16 administrative regions by general linear regression mod

Results: Between 2008 and 2010, the incidence of thyroid cancer was 64.1 per 100,000 individuals: females was 107.3 and in males was 21.1. There was a strong positive correlation between regiona screening and regional thyroid cancer incidence ($r=0.77$, [95% confidence interval 0.70–0.82]). T correlation was higher for females ($r=0.88$ [CI 0.83–0.92]) than in males ($r=0.76$ [CI 0.67–0. group. Thyroid screening was only associated with increased detection of papillary thyroid cancer (r 0.88]); and not associated with mortality ($r=-0.08$ [CI –0.59–0.63]) due to thyroid cancer.

Conclusions: The magnitude of association between thyroid cancer screening in South Korea and thyroid cancer strongly suggests that screening is the most important driver of the epidemic of particularly among females. Thyroid cancer screening, however, was only associated with the increase of one tumor histology, papillary thyroid cancer, and it did not have any association with thyroid cancer mortality. The extent to which opportunistic thyroid cancer screening is converting thousands of asymptomatic persons to cancer patients without any known benefit to them needs to be examined carefully.

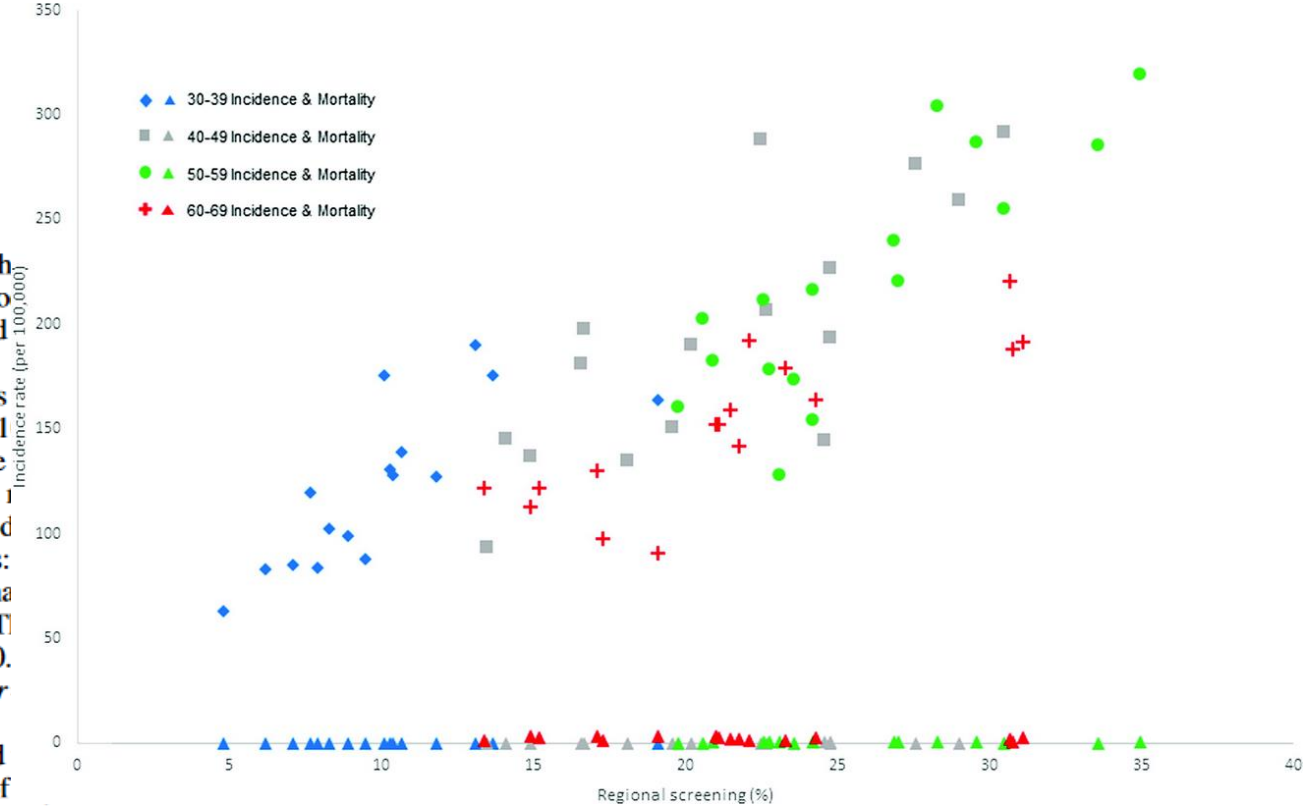

Zettinig 2018

Frage

- Wird dieser Knoten die Gesundheit meines Patienten beeinträchtigen oder sogar sein Leben verkürzen?
  - Ist der Knoten bösartig?
  - Kann der Knoten funktionell autonom Schilddrüsenhormon produzieren?

- Profitiert der Patient von einer Intervention?

- Es gibt kein typisches sonografisches Muster eines Schilddrüsenkarzinoms

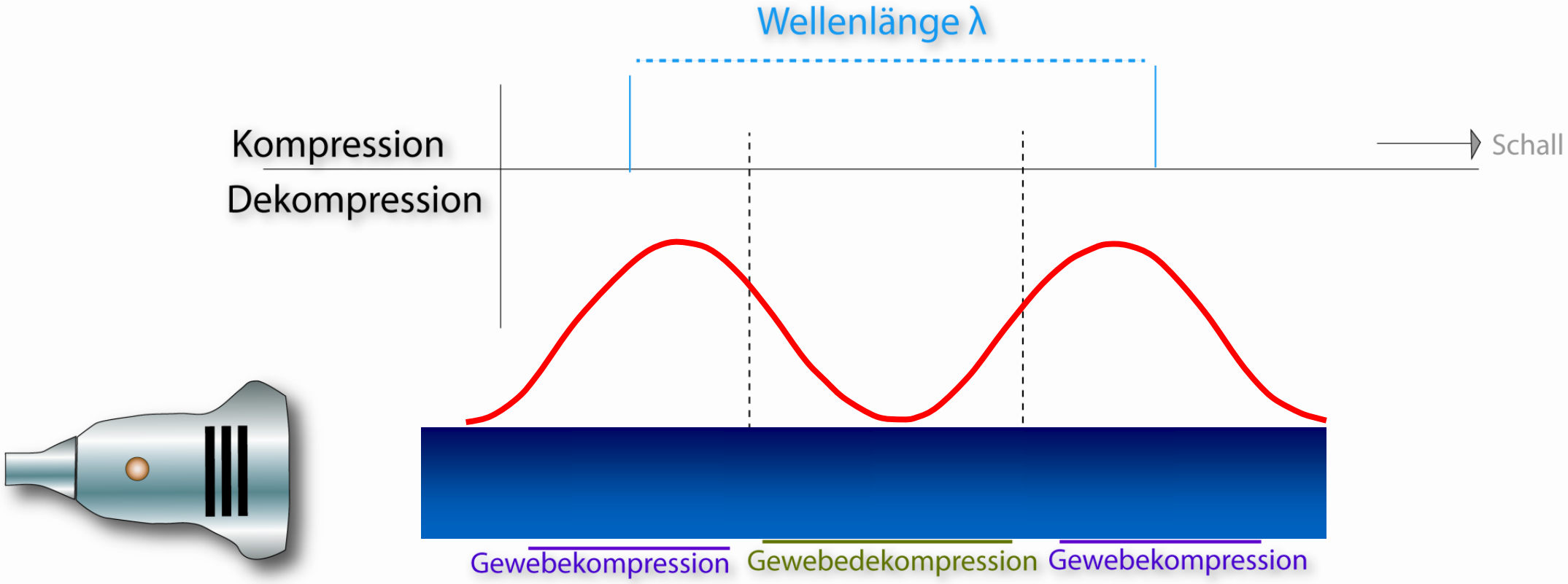
Wellenlänge λ
Kompression
Dekompression
Schall
Gewebekompression
Gewebedekompression
Gewebekompression

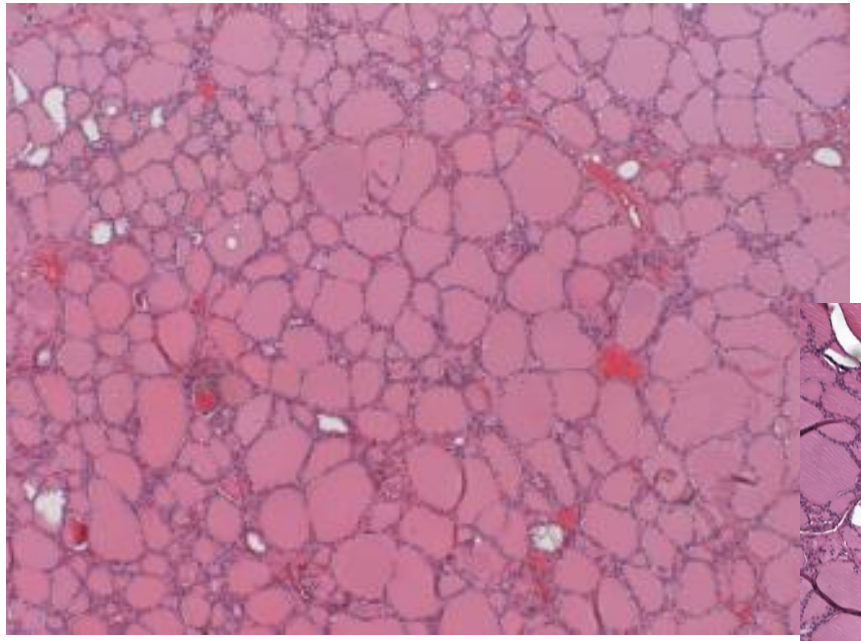

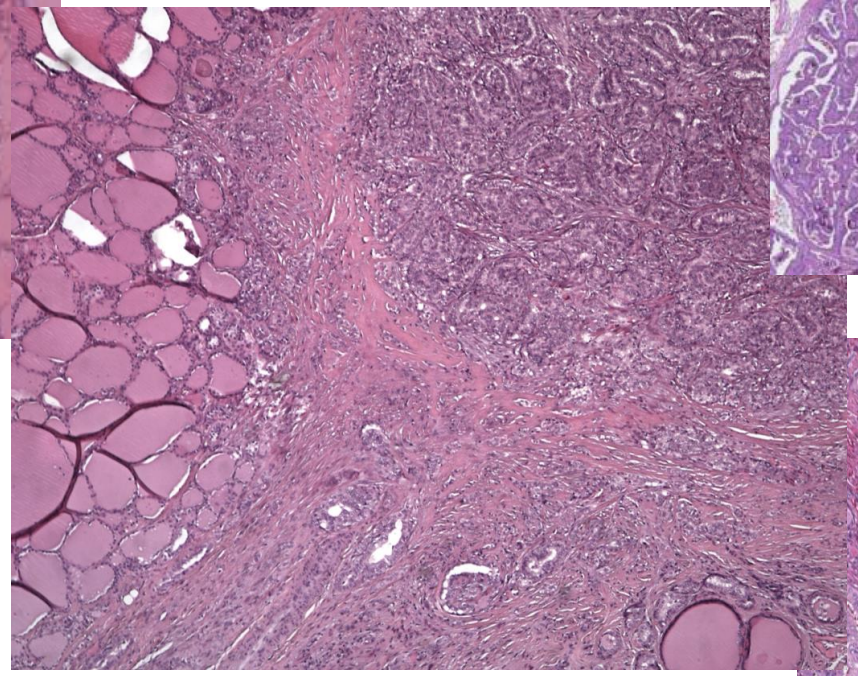

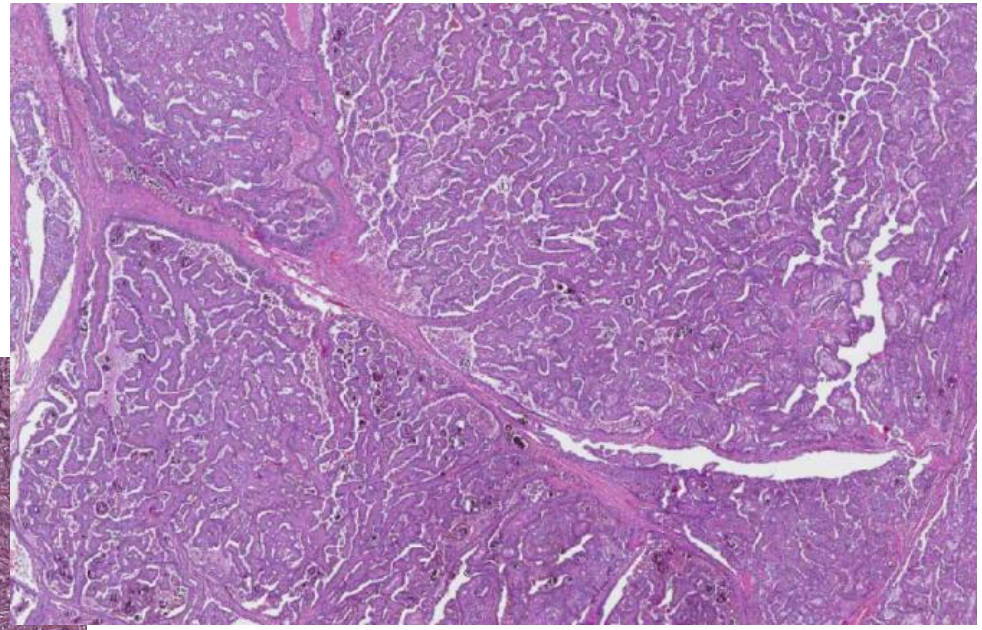

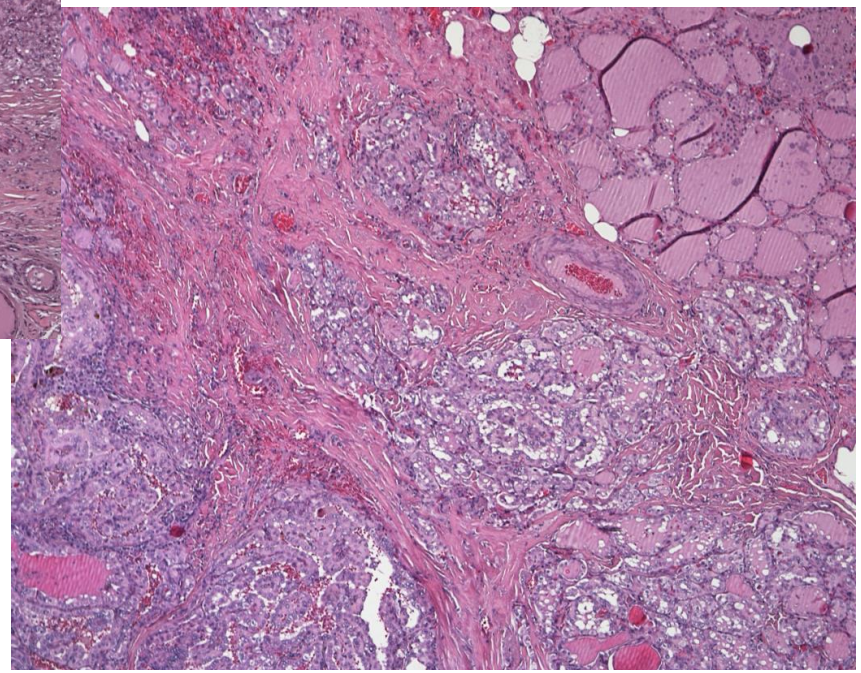

Bilder: Prof. Oskar Koperek

Sonomorphologische Malignitätskriterien

Schallmuster	unverdächtig	suspekt
solid/zystisch	zystisch	rein solide
Echotextur	echogleich u. -reich	deutlich echoarm
Kalk	ohne, grobschollig	Mikrokalk
Begrenzung	glatt	irregulär / Mikrolobuli
Form / Lage	längsoval	quer zu Längsachse
dünner Halo	gut abgrenzbar	fehlend/unregelm.
Blutfluss	intranodulär niedrig	intranodulär hoch

ORIGINAL ARTICLE

Endocrine Care—Brief Report

An Ultrasonogram Reporting System for Thyroid Nodules Stratifying Cancer Risk for Clinical Management

Eleonora Horvath, Sergio Majlis, Ricardo Rossi, Carmen Franco, Juan P. Niedmann, Alex Castro, and Miguel Dominguez

Thyroid Board (E.H., S.M., R.R., J.P.N., A.C., M.D.), Clinica Alemana de Santiago, Av. Vitacura 5951 Santiago, Chile; and Instituto de Anatomia Patologica (C.F.), Av. Manquehue Norte 1707 of. 9 Santiago, Chile

Context: There is a high prevalence of thyroid nodules on ultrasonographic (US) examination. However, most of them are benign. US criteria may help to decide cost-effective management.

Objective: Our objective was to develop a standardized US characterization and reporting data system of thyroid lesions

Design: This was
Imaging Reporti

Materials: A cor
1959 lesions bic
was divided into
stage, four TIRA
defined in the B
lignancy), TIRAD
malignancy).

Results: The TIRA
nodules (benign
predictive value,
The ratio of beni

Conclusions: The
avoiding unnece
radiologists and

THYROID
Volume 19, Number 11, 2009

DOI: 10.1089/thy.2008.0021

THYROID RADIOLOGY AND NUCLEAR MEDICINE

A Proposal for a Thyroid Imaging Reporting and Data System for Ultrasound Features of Thyroid Carcinoma

Ji-Young Park,[1] Hui Joong Lee,[2] Han Won Jang,[3] Ho Kyun Kim,[4] Jae Hyuck Yi,[2] Wonho Lee,[2] and Seong Hun Kim[5]

Background: Several thyroid ultrasound (TUS) findings have been associated with an increased risk for thyroid cancer; however, there is no consensus as to the format and style for reporting the results of TUS. The objective of this study was to discover the features indicative of malignancy in thyroid nodules based on TUS, generate an equation using these features that would be predictive of malignancy in thyroid nodules, and stratify the results of this equation into TUS categories reflecting the probability of malignancy.

Horvath et al., 2009, JCEM

- Korrelation US und FNP in 1.959 histologisch ausgewerteten Herdbefunden
- Definition von 10 US Mustern, bei 362 Herdefunden FNP, "Histologie" wurde in 3 Gruppen unterteilt, Definition von 4 TIRADS Gruppen "according to risk"
- Evaluation der Kriterien bei 1097 Knoten
- Sens. 88 %, Spez. 49 %, PPV 88 %, NPV 94 %
- Aber Achtung: FNP im Follow up nur bei jenen Knoten, bei denen der experienced radiologist der Meinung war, eine FNP sei indiziert.

ORIGINAL ARTICLE

Endocrine Care—Brief Report

An Ultrasonogram Reporting System for Thyroid Nodules Stratifying Cancer Risk for Clinical Management

Eleonora Horvath, Sergio Majlis, Rica
Alex Castro, and Miguel Dominguez

Thyroid Board (E.H., S.M., R.R., J.P.N., A.C., M.D
and Instituto de Anatomia Patologica (C.F.), Av.

Context: There is a high prevalence o
However, most of them are benign. US

Objective: Our objective was to develop a
of thyroid lesions for clinical managemer

Design: This was a prospective study usi
Imaging Reporting Data System of the

Materials: A correlation of the US finc
1959 lesions biopsied under US guid
was divided into three stages. In the
stage, four TIRADS groups were defi
defined in the Breast Imaging Report
lignancy), TIRADS 3 (<5% malignancy
malignancy).

Results: The TIRADS classification was e
nodules (benign: 703; follicular lesions
predictive value, negative predictive val
The ratio of benign to malignant or fo

Conclusions: The TIRADS has allowed u
avoiding unnecessary FNAB. In additio
radiologists and endocrinologists. *(J Cl*

THYROID
Volume 19, Number 11, 2009

DOI: 10.1089/thy.2008.0021

A Proposal for a Thyroid Imaging Reporting and Data System for Ultrasound Features of Thyroid Carcinoma

Ji-Young Park,[1] Hui Joong Lee,[2] Han Won Jang,[3] Ho Kyun Kim,[4] Jae Hyuck Yi,[2]
Wonho Lee,[2] and Seong Hun Kim[5]

Background: Several thyroid ultrasound (TUS) findings have been associated with an increased risk for thyroid cancer; however, there is no consensus as to the format and style for reporting the results of TUS. The objective of this study was to discover the features indicative of malignancy in thyroid nodules based on TUS, generate an equation using these features that would be predictive of malignancy in thyroid nodules, and stratify the results of this equation into TUS categories reflecting the probability of malignancy.
Methods: We obtained odds ratios of TUS findings indicative of malignancy and probability of malignancy for each nodule as determined by logistic regression analysis of ultrasound (US) findings in 1694 patients who had US-guided fine-needle aspiration biopsy. We then generated an equation to predict the probability of malignancy based on TUS and developed categories ranging from lowest to highest probability of malignancy. We evaluated the reliability of this equation and the categories using cytology and histopathology information regarding malignancy in the thyroid nodules.
Results: We characterized 12 aspects of thyroid nodules as seen on TUS and developed an equation to predict P^{us}, the probability of a nodule being malignant based on these US findings. The equation was $P^{us} = 1/(1+e^{-z})$, where e is the mathematical constant 2.71828 and z is the logit of malignant thyroid nodule. P^{us} was stratified into five categories based on the probability of a nodule being malignant as indicated by the findings (TUS 1, benign; TUS 2, probably benign; TUS 3, indeterminate; TUS 4, probably malignant; TUS 5, malignant). There was a significant correlation between the cytological category and the TUS 1 through TUS 5 categories ($r = 0.491$, $p < 0.001$).
Conclusions: We propose an equation to predict the probability of malignancy in thyroid nodules based on 12 features of thyroid nodules as noted on TUS. This equation, and the stratification of its results into categories, should be useful in reporting the findings of US for thyroid nodules and in guiding management decisions.

Introduction

THE INCREASED USE OF HIGH-RESOLUTION ULTRASOUND (US) for thyroid disease has markedly increased the discovery of small nonpalpable thyroid nodules. These nodules present a clinical dilemma as there is uncertainty regarding how they should be managed (1–3). Although nodules less

US is useful in detecting a focal lesion, determining whether a lesion is cystic or solid, and guiding USG-FNAB. Several US findings are associated with an increased risk for thyroid cancer (6–8). These include calcifications, hypoechogenecity, irregular margins, absence of a halo, predominantly solid composition, and intranodule vascularity (6,7,9–13). However, the sensitivities, specificities, and negative and

Schilddrüsenpraxis
JOSEFSTADT
Ihr Team von Experten

Zettinig 2018

12 Kriterien für Multivarianzanalyse

- Wachstumsrichtung
- Halo
- gut umschriebener Rand
- Mikrolobuli
- Infiltration am Rand
- Hypoechogenität
- deutliche Hypoechogenität
- Homogenes Echomuster
- großteils zystisch
- solid
- Mikrokalk
- abnorme Lymphknoten

Methoden

- Retrospektiv
- 5 1/2 Jahre
- 2679 Patienten

Table 4. Proposed Categorization of Thyroid Nodules Based on Their Ultrasonographic Features and Cytology, and the Number and Percentage of Nodules Classified as Benign or Malignant According to Cytology and Histopathology

		Cytology[b]					Classification				
Category	*Probability*[a]	*THY1*	*THY2*	*THY3*	*THY4*	*THY5*	*Benign*	*Malignant*	*Definition*	*Example of US findings*	*Recommendation*
TUS 0									No nodule	Normal or diffuse enlargement of the thyroid gland	
TUS 1	0–7%	15	416	2	6	2	433 (98.2%)	8 (1.8%)	Highly suggestive of benign	Cystic predominant, peripheral halo	No additional US is recommanded if clinically not needed
TUS 2	8–23%	17	372	20	31	9	406 (90.4%)	48 (9.6%)	Probably benign	Circumscribed margin, solid predominant, heterogeneous echotexture, iso- to hyperechogenecity, eggshell or macrocalcification	Long-term US follow-up if clinicaly needed
TUS 3	24–50%	20	292	44	58	52	321 (68.9%)	145 (31.1%)	Indeterminate	Homogeneous echotexture, hypoechogenecity, circumscribed margin, solid, taller, without other US findings suggestive of malignacy	Aspiration and short-term (6 month) follow-up if nondiagnositic cytological result
TUS 4	51–90%	16	55	57	95	79	70 (23.2%)	231 (76.8%)	Probably malignant	One or two US findings suggestive of malignancy, such as markedly hypoechoic, microcalcification, not-circumscribed margin, and lymph node abnormality	Aspiration and immediate reaspiration if nondiagnostic FNAB result
TUS 5	91–100%	2	0	11	14	9	0 (0.0%)	36 (100.0%)	Highly suggestive of malignancy	More than three US findings suggestive of malignancy, such as markedly hypoechoic, microcalcification, not-circumscribed margin, and lymph node abnormality	Consider surgery regardless of FNAB results

[a]Probability is the range for P^{us}, the probability of a nodule being malignant based on an equation derived from US features.
[b]Cytology categories: THY1, inadequate; THY2, benign; THY3, indeterminate; THY4, suspiciously malignant; THY5, malignant.
TUS, thyroid ultrasound; US, ultrasound; FNAB, fine-needle aspiration biopsy.

2011

- Prospektiv
- 8 Monate
- FNA in 3674 Knoten in 3414 Patienten

Jin Young Kwak, MD
Kyung Hwa Han, MS
Jung Hyun Yoon, MD
Hee Jung Moon, MD
Eun Ju Son, MD
So Hee Park, MD
Hyun Kyung Jung, MD
Ji Soo Choi, MD
Bo Mi Kim, MD
Eun-Kyung Kim, MD

Thyroid Imaging Reporting and Data System for US Features of Nodules: A Step in Establishing Better Stratification of Cancer Risk[1]

Radiology

Purpose: To develop a practical thyroid imaging reporting and data system (TIRADS) with which to categorize thyroid nodules and stratify their malignant risk.

Materials and Methods: The institutional review board approved this retrospective study, and the requirement to obtain informed consent for the review of images and records was waived. From May to December 2008, ultrasonographically (US)-guided fine-needle aspiration biopsy (FNAB) was performed in 3674 focal thyroid nodules in 3414 consecutive patients. The study included the 1658 thyroid nodules (≥1 cm in maximum diameter at US) in 1638 patients (1373 women, 265 men) for which pathologic diagnosis or follow-up findings were available. Univariate and multivariate analyses with

Identifikation von unabhängigen Faktoren

- solide Komponente
- Hypoechogenität
- deutliche Hypoechogenität
- Mikrolobuli bzw. unregelmäßiger Rand
- Mikrokalk
- More tall than wide

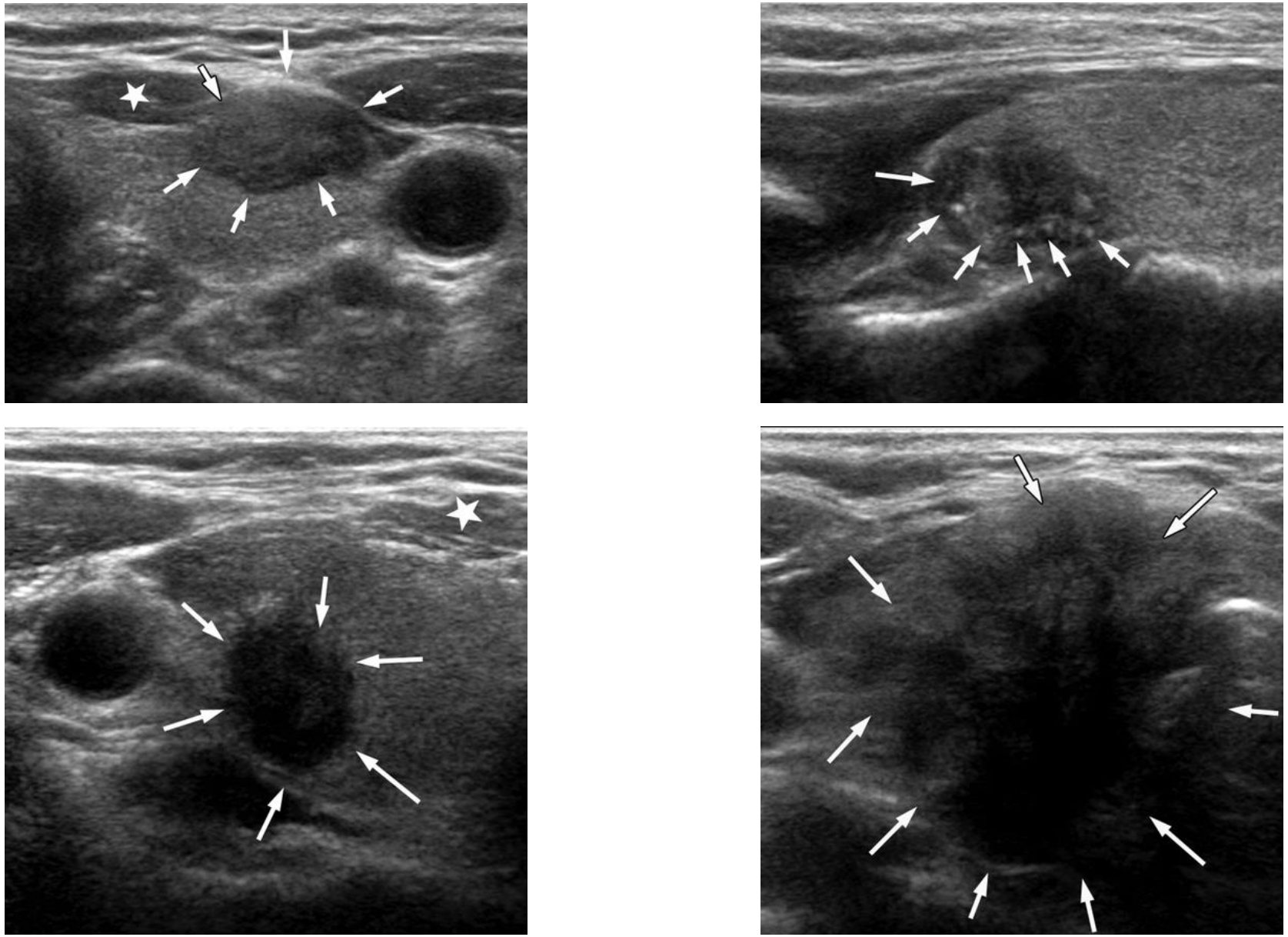

Schilddrüsenpraxis
JOSEFSTADT
Ihr Team von Experten

Published in: Jin Young Kwak; Kyung Hwa Han; Jung Hyun Yoon; Hee Jung Moon; Eun Ju Son; So Hee Park; Hyun Kyung Jung; Ji Soo Choi; Bo Mi Kim; Eun-Kyung Kim; *Radiology* **2011,** 260, 892-899.

THYROID
Volume 26, Number 1, 2016

DOI: 10.1089/thy.2015.0020

SPECIAL ARTICLE

2015 American Thyroid Association Management Guidelines for Adult Patients with Thyroid Nodules and Differentiated Thyroid Cancer

The American Thyroid Association Guidelines Task Force on Thyroid Nodules and Differentiated Thyroid Cancer

Bryan R. Haugen,[1,*] Erik K. Alexander,[2] Keith C. Bible,[3] Gerard M. Doherty,[4] Susan J. Mandel,[5] Yuri E. Nikiforov,[6] Furio Pacini,[7] Gregory W. Randolph,[8] Anna M. Sawka,[9] Martin Schlumberger,[10] Kathryn G. Schuff,[11] Steven I. Sherman,[12] Julie Ann Sosa,[13] David L. Steward,[14] R. Michael Tuttle,[15] and Leonard Wartofsky[16]

Background: Thyroid nodules are a common clinical proble
increasingly prevalent. Since the American Thyroid Associa
these disorders were revised in 2009, significant scientific ad
guidelines is to inform clinicians, patients, researchers, and h
to the diagnosis and management of thyroid nodules and di
Methods: The specific clinical questions addressed in these
guidelines, stakeholder input, and input of task force memb
knowledge synthesis methods, including electronic database

Home / Shop / **Differentiated Thyroid Cancer GUIDELINES Pocket Card**



Differentiated Thyroid Cancer GUIDELINES Pocket Card

APPROVED BY
American Thyroid Association

DIGITAL		$8.99	ADD TO CART
PRINT	QTY	$13.95	ADD TO CART

Free Sample

CONTACT US

106 Commerce Street Suite 105
Lake Mary, Florida 32746
407.878.7606

NAME*
EMAIL

DIGITAL | PRINT | WHAT'S INSIDE | ABOUT THE AUTHORS

The Digital version of the ATA Differentiated Thyroid Cancer GUIDELINES contains all the sam information found in the Pocket Card, and can be accessed on Mobile devices and online:

- For a single low price: $8.99
- Includes automatic updates on drugs and indications
- Supported platforms
  - iPhone and iPad

Schilddrüsenpraxis
JOSEFSTADT
Ihr Team von Experten

Zettinig 2018

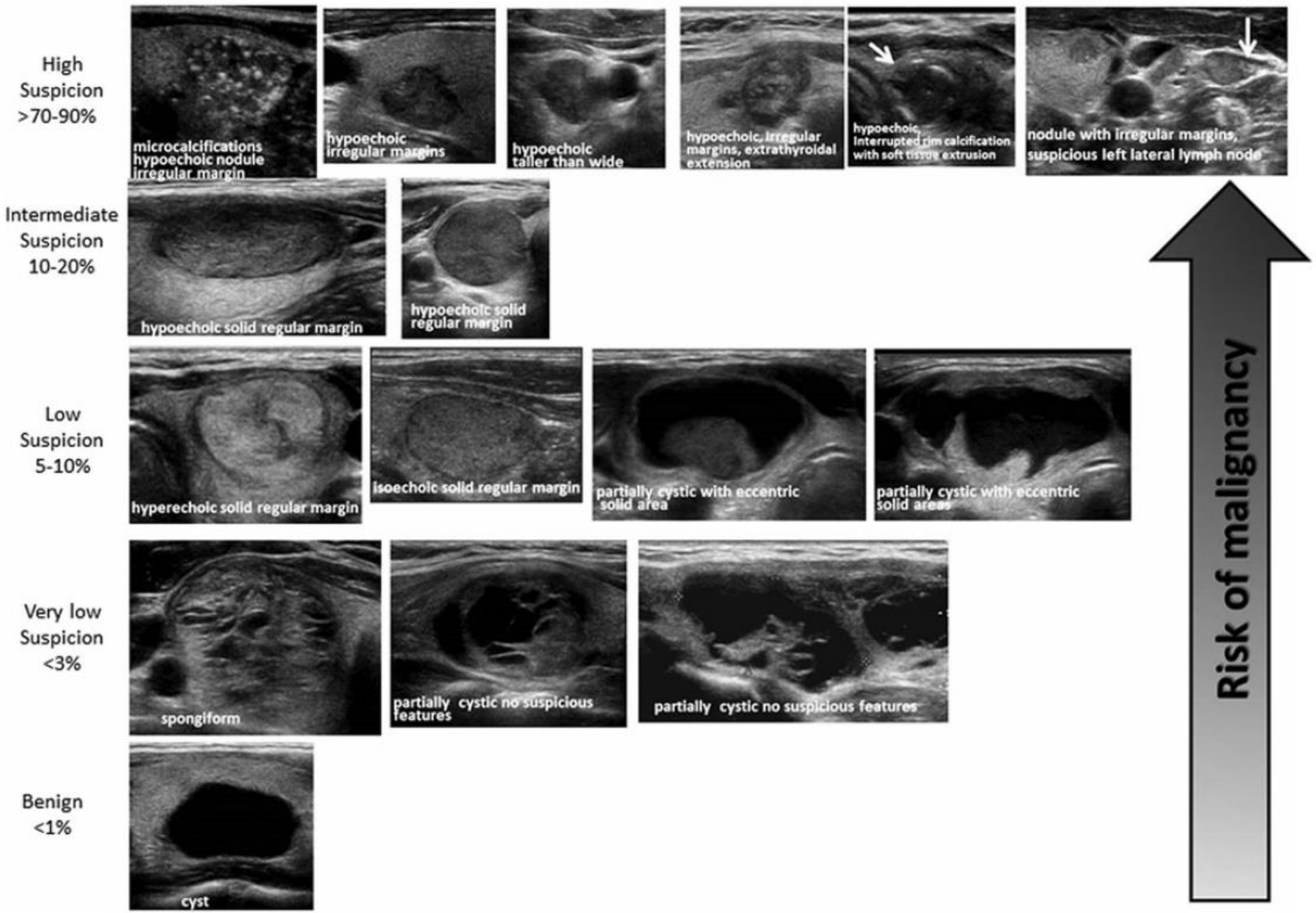

Thyroid 2016; 26(1): 1-133

FIG. 2. ATA nodule sonographic patterns and risk of malignancy.

Guidelines

European Thyroid Journal

Eur Thyroid J
DOI: 10.1159/000478927

Received: May 4, 2017
Accepted: June 17, 2017
Published online: August 8, 2017

European Thyroid Association Guidelines for Ultrasound Malignancy Risk Stratification of Thyroid Nodules in Adults: The EU-TIRADS

Gilles Russ[a] Steen J. Bonnema[b] Murat Faik Erdogan[c] Cosimo Durante[d] Rose Ngu[e] Laurence Leenhardt[a]

[a]Thyroid and Endocrine Tumors, Institute of Endocrinology, Pitié Salpêtrière Hospital, Pierre and Marie Curie University, Paris, France; [b]Department of Endocrinology, Odense University Hospital, Odense, Denmark; [c]Department of Endocrinology and Metabolism, University of Ankara School of Medicine, İbni Sina Hastanesi, Ankara, Turkey; [d]Department of Internal Medicine and Medical Specialties, Sapienza University of Rome, Rome, Italy; [e]Head Neck and Thyroid Imaging, Department of Radiology, Guy's and St Thomas' Hospitals NHS Foundation Trust, London, UK

Keywords
Ultrasound · Thyroid nodule · Risk of malignancy · Fine needle aspiration · TIRADS · Guidelines

Abstract
Thyroid ultrasound (US) is a key examination for the management of thyroid nodules. Thyroid US is easily accessible, ules, with the estimated risks of malignancy in each category; and indications for FNA. Illustrated by numerous US images, the EU-TIRADS aims to serve physicians in their clinical practice, to enhance the interobserver reproducibility of descriptions, and to simplify communication of the results.

European Journal of Endocrinology (2013) **168** 649–655 ISSN 0804-4643

CLINICAL STUDY

Prospective evaluation of thyroid imaging reporting and data system on 4550 nodules with and without elastography

Gilles Russ[1,2], Bénédicte Royer[1,3], Claude Bigorgne[1], Agnès Rouxel[1,2], Marie Bienvenu-Perrard[1,4] and Laurence Leenhardt[1,2]

[1]*Centre of Pathology and Radiology, 14 Avenue René Coty, 75014 Paris, France,* [2]*Department of Nuclear Medicine, Pitié-Salpêtrière Hospital, Pierre et Marie Curie University, Boulevard de l'Hôpital, 75651 Paris, France, Departments of* [3]*Pathology and* [4]*Nuclear Medicine, Cochin Hospital, 27 Rue du Faubourg Saint Jacques, 75014 Paris, France*

(Correspondence should be addressed to G Russ at Centre of Pathology and Radiology; Email: gilles.russ@wanadoo.fr)

Abstract

Objective: To evaluate prospectively the diag
system (TI-RADS) and its interobserver agre
needle aspiration biopsies (FNABs).
Design: A prospective comparative study wa
Methods: In 2 years, 4550 nodules in 3543
six-point scale and then submitted to US-FN
Histopathological results were available for
predictive value (NPV) and positive predicti
score, elastography, and a combination of

Table 1 Comparison of the clinical efficiency of TI-RADS grey scale score alone, elastography alone and of both methods in combination with cytological results

Imaging method	Sensitivity (%)	Specificity (%)	NPV (%)	Accuracy (%)
TI-RADS gray-scale score only (3658 cases)	95.7	61	99.7	62
Elastography only (991 cases)	74.2	91.1	98	90
Combined TI-RADS (991 cases) gray-scale + elastography	98.5	44.7	99.8	48.3

NPV, negative predictive value.

Guidelines

European Thyroid Journal

Eur Thyroid J
DOI: 10.1159/000478927

Received: May 4, 2017
Accepted: June 17, 2017
Published online: August 8, 2017

European Thyroid Association Guidelines for Ultrasound Malignancy Risk Stratification of Thyroid Nodules in Adults: The EU-TIRADS

Gilles Russ[a] Steen J. Bonnema[b] Murat Faik Erdogan[c] Cosimo Durante[d] Rose Ngu[e] Laurence Leenhardt[a]

[a]Thyroid and Endocrine Tumors, Institute of Endocrinology, Pitié Salpêtrière Hospital, Pierre and Marie Curie University, Paris, France; [b]Department of Endocrinology, Odense University Hospital, Odense, Denmark; [c]Department of Endocrinology and Metabolism, University of Ankara School of Medicine, İbni Sina Hastanesi, Ankara, Turkey; [d]Department of Internal Medicine and Medical Specialties, Sapienza University of Rome, Rome, Italy; [e]Head Neck and Thyroid Imaging, Department of Radiology, Guy's and St Thomas' Hospitals NHS Foundation Trust, London, UK

Keywords
Ultrasound · Thyroid nodule · Risk of malignancy · Fine needle aspiration · TIRADS · Guidelines

Abstract
Thyroid ultrasound (US) is a key examination for the management of thyroid nodules. Thyroid US is easily accessible, ules, with the estimated risks of malignancy in each category; and indications for FNA. Illustrated by numerous US images, the EU-TIRADS aims to serve physicians in their clinical practice, to enhance the interobserver reproducibility of descriptions, and to simplify communication of the results.

Table 2. EU-TIRADS categories and risk of malignancy

Category	US features	Malignancy risk, %
EU-TIRADS 1: normal	No nodules	None
EU-TIRADS 2: benign	Pure cyst Entirely spongiform	≅0
EU-TIRADS 3: low risk	Ovoid, smooth isoechoic/hyperechoic No features of high suspicion	2–4
EU-TIRADS 4: intermediate risk	Ovoid, smooth, mildly hypoechoic No features of high suspicion	6–17
EU-TIRADS 5: high risk	At least 1 of the following features of high suspicion: – Irregular shape – Irregular margins – Microcalcifications – Marked hypoechogenicity (and solid)	26–87

EU-TIRADS, European Thyroid Imaging Reporting and Data System; US, ultrasound.

Table 2. EU-TIRADS categories and risk of malignancy

Category	US features	Malignancy risk, %
EU-TIRADS 1: normal	No nodules	None
EU-TIRADS 2: benign	Pure cyst Entirely spongiform	≅0
EU-TIRADS 3: low risk	Ovoid, smooth isoechoic/hyperechoic No features of high suspicion	2–4
EU-TIRADS 4: intermediate risk	Ovoid, smooth, mildly hypoechoic No features of high suspicion	6–17
EU-TIRADS 5: high risk	At least 1 of the following features of high suspicion: – Irregular shape – Irregular margins – Microcalcifications – Marked hypoechogenicity (and solid)	26–87

EU-TIRADS, European Thyroid Imaging Reporting and Data System; US, ultrasound.

Table 2. EU-TIRADS categories and risk of malignancy

Category	US features
EU-TIRADS 1: normal	No nodules
EU-TIRADS 2: benign	Pure cyst Entirely spongiform
EU-TIRADS 3: low risk	Ovoid, smooth isoechoic/hype No features of high suspicion
EU-TIRADS 4: intermediate risk	Ovoid, smooth, mildly hypoecl No features of high suspicion
EU-TIRADS 5: high risk	At least 1 of the following featu – Irregular shape – Irregular margins – Microcalcifications – Marked hypoechogenicity (a

EU-TIRADS, European Thyroid Imaging Reporting and Data Sy

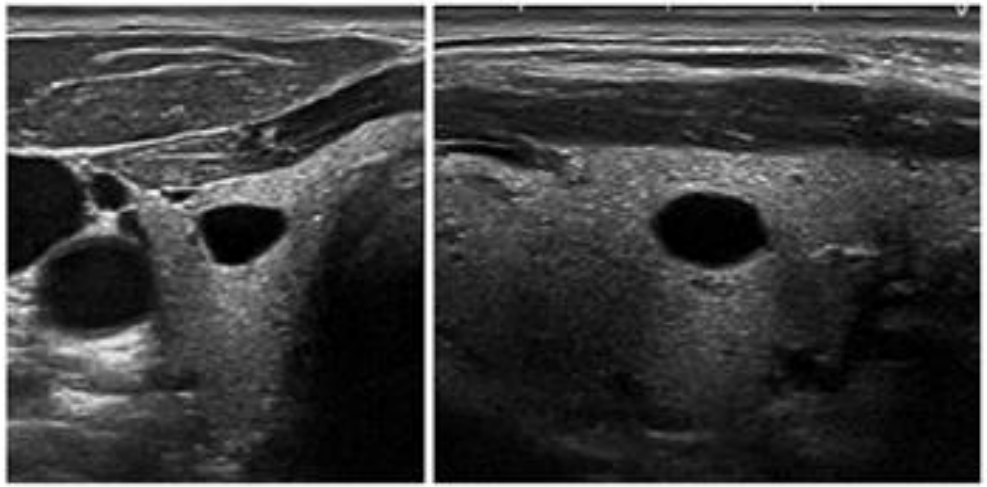

Fig. 2. EU-TIRADS 2: pure/anechoic cyst. Transverse (left) and longitudinal (right) planes.

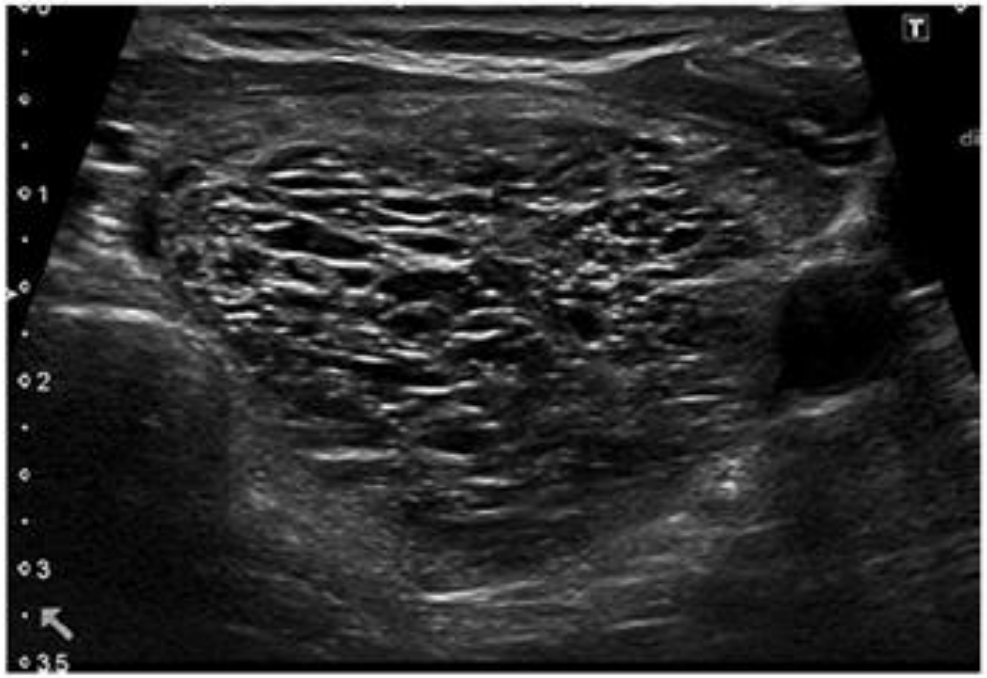

Fig. 3. EU-TIRADS 2: spongiform nodule. Transverse plane.

Table 2. EU-TIRADS categories and risk of malignancy

Category	US features	Malignancy risk, %
EU-TIRADS 1: normal	No nodules	None
EU-TIRADS 2: benign	Pure cyst Entirely spongiform	≅0
EU-TIRADS 3: low risk	Ovoid, smooth isoechoic/hyperechoic No features of high suspicion	2–4
EU-TIRADS 4: intermediate risk	Ovoid, smooth, mildly hypoechoic No features of high suspicion	6–17
EU-TIRADS 5: high risk	At least 1 of the following features of high suspicion: – Irregular shape – Irregular margins – Microcalcifications – Marked hypoechogenicity (and solid)	26–87

EU-TIRADS, European Thyroid Imaging Reporting and Data System; US, ultrasound.

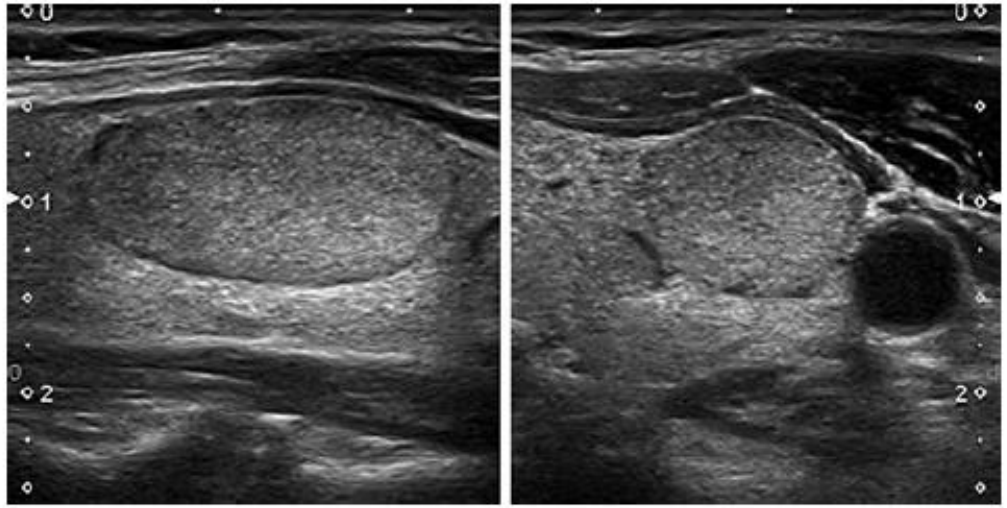

Fig. 4. EU-TIRADS 3: low-risk isoechoic nodule with an oval shape and smooth margins without any high-risk features. Longitudinal (left) and transverse (right) planes.

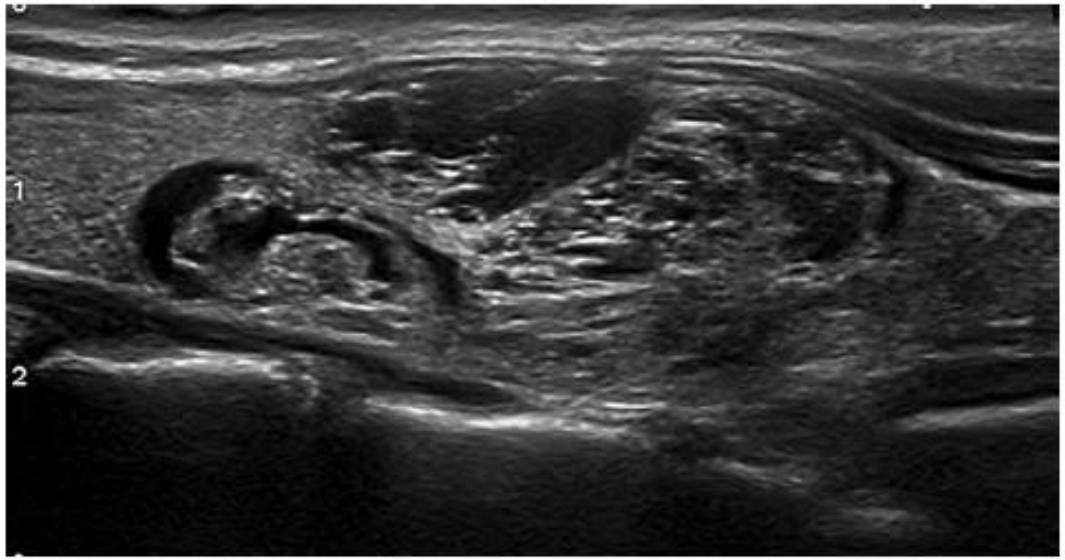

Fig. 6. EU-TIRADS 3: grouped low-risk isoechoic nodules with an oval shape and smooth margins without any high-risk features. Longitudinal plane.

f malignancy

tures

dules

yst

ly spongiform

, smooth isoechoic

EU-TIRADS 4: ir

EU-TIRADS 5: h

s of high suspicion: 26–87

solid)

EU-TIRADS,

em; US, ultrasound.

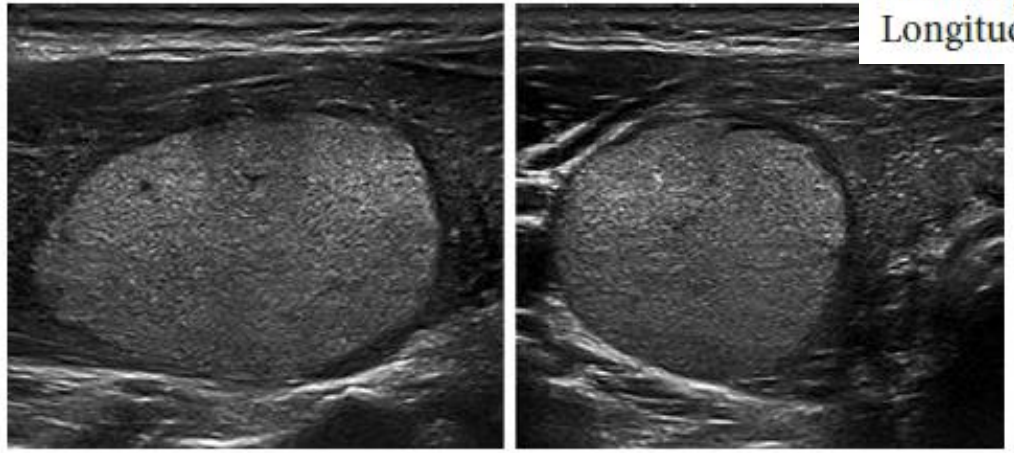

Fig. 5. EU-TIRADS 3: low-risk hyperechoic nodule with an oval shape and smooth margins without any high-risk features. Longitudinal (left) and transverse (right) planes.

Table 2. EU-TIRADS categories and risk of malignancy

Category	US features	Malignancy risk, %
EU-TIRADS 1: normal	No nodules	None
EU-TIRADS 2: benign	Pure cyst Entirely spongiform	≅0
EU-TIRADS 3: low risk	Ovoid, smooth isoechoic/hyperechoic No features of high suspicion	2–4
EU-TIRADS 4: intermediate risk	Ovoid, smooth, mildly hypoechoic No features of high suspicion	6–17
EU-TIRADS 5: high risk	At least 1 of the following features of high suspicion: – Irregular shape – Irregular margins – Microcalcifications – Marked hypoechogenicity (and solid)	26–87

EU-TIRADS, European Thyroid Imaging Reporting and Data System; US, ultrasound.

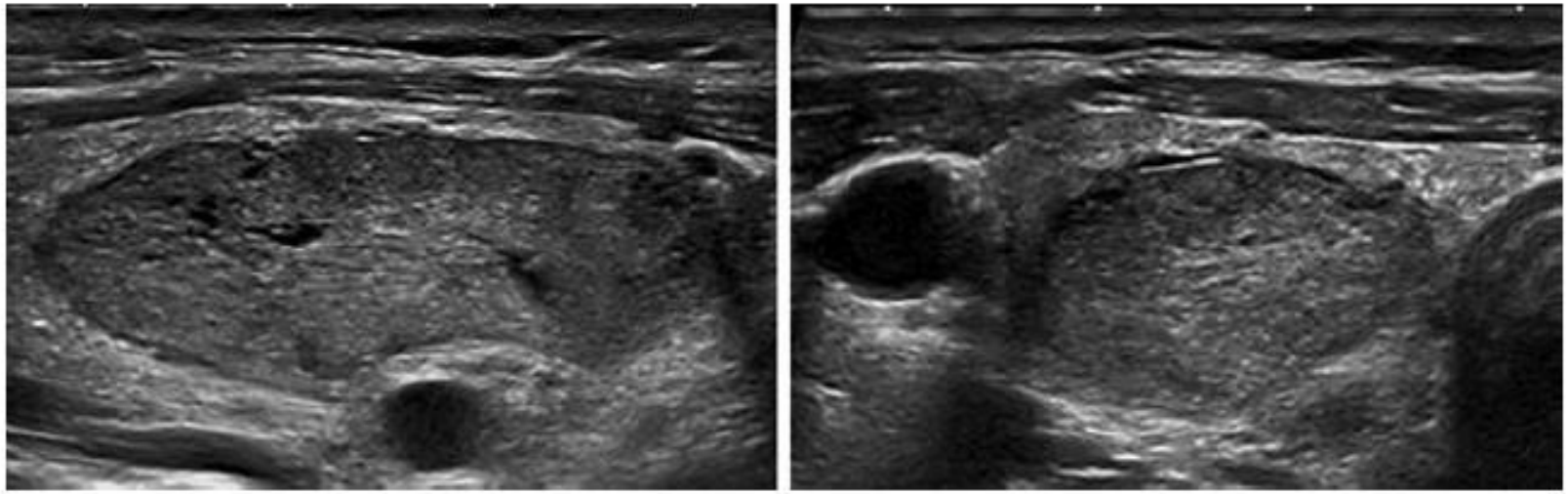

Fig. 7. EU-TIRADS 4: intermediate-risk, mildly hypoechoic nodule with an oval shape and smooth margins without any high-risk features. Longitudinal (left) and transverse (right) planes.

EU-TIRADS 3: low risk	Ovoid, smooth isoechoic/hyperechoic No features of high suspicion	2–4
EU-TIRADS 4: intermediate risk	Ovoid, smooth, mildly hypoechoic No features of high suspicion	6–17
EU-TIRADS 5: high risk	At least 1 of the following features of high suspicion: – Irregular shape – Irregular margins – Microcalcifications – Marked hypoechogenicity (and solid)	26–87

EU-TIRADS, European Thyroid Imaging Reporting and Data System; US, ultrasound.

Table 2. EU-TIRADS categories and risk of malignancy

Category	US features	Malignancy risk, %
EU-TIRADS 1: normal	No nodules	None
EU-TIRADS 2: benign	Pure cyst Entirely spongiform	≅0
EU-TIRADS 3: low risk	Ovoid, smooth isoechoic/hyperechoic No features of high suspicion	2–4
EU-TIRADS 4: intermediate risk	Ovoid, smooth, mildly hypoechoic No features of high suspicion	6–17
EU-TIRADS 5: high risk	At least 1 of the following features of high suspicion: – Irregular shape – Irregular margins – Microcalcifications – Marked hypoechogenicity (and solid)	26–87

EU-TIRADS, European Thyroid Imaging Reporting and Data System; US, ultrasound.

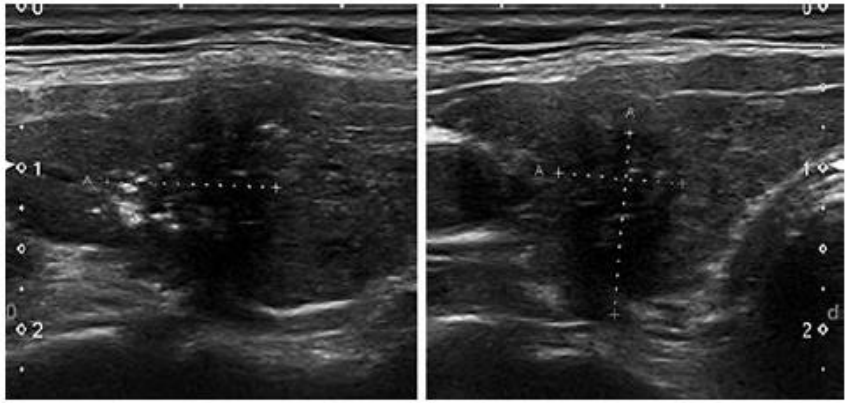

Fig. 8. EU-TIRADS 5: high-risk nodule with a taller-than-wide shape, irregular margins, microcalcifications, and marked hypoechogenicity. Longitudinal (left) and transverse (right) planes. 11 × 8 × 11 mm (length × width × thickness).

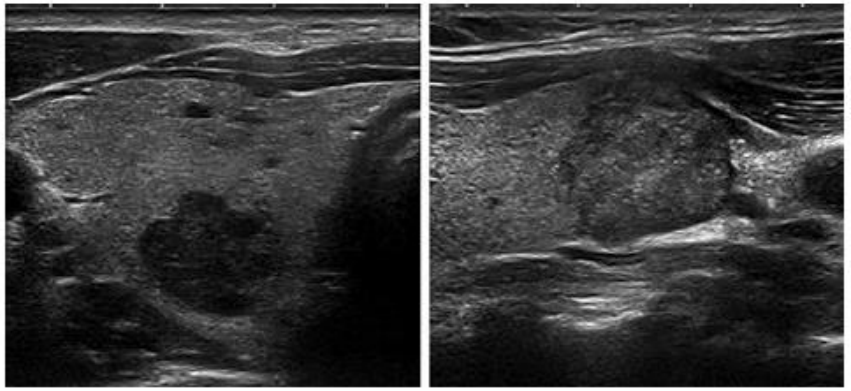

Fig. 10. EU-TIRADS 5: two different examples of high-risk hypoechoic nodules with lobulated margins in the transverse (left picture) and longitudinal (right picture) planes.

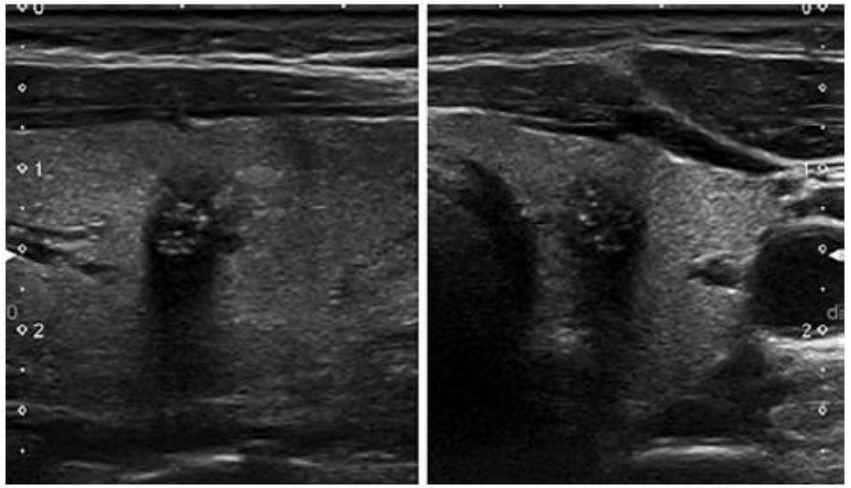

Fig. 9. EU-TIRADS 5: high-risk nodule with a non-oval shape, spiculated margins, microcalcifications, and marked hypoechogenicity. Longitudinal (left) and transverse (right) planes.

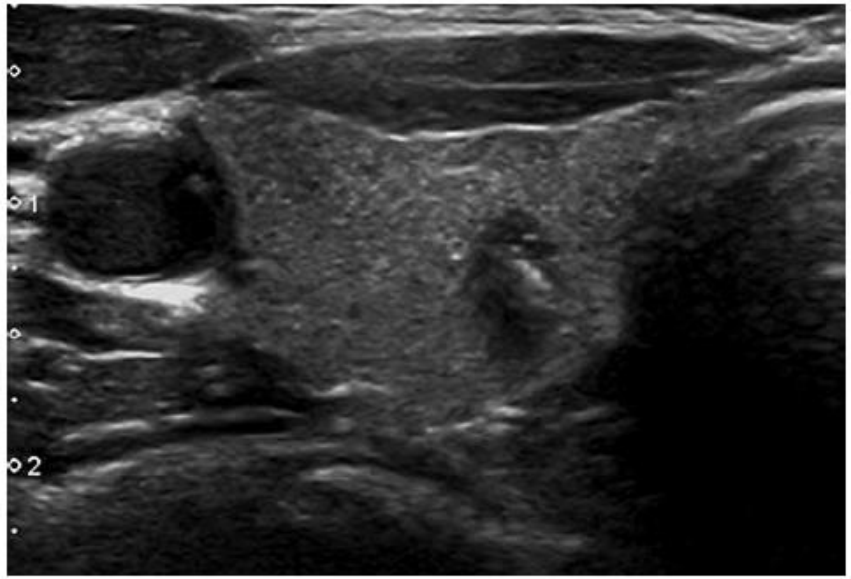

Fig. 11. EU-TIRADS 5: high-risk nodule with a taller-than-wide shape in the transverse plane.

SPECIAL CONTRIBUTION

2016년 ㅁ 개정안

서울특별시 보라매병
이비인후과[4], 외과[8],
서울대학교 의과대학
이비인후과[12], 울산대
이가희[1], 이은경[2]
백승국[12], 백정환

2016 Revis Guidelines Cancer

Ka Hee Yi[1], Eun
Dong Gyu Na[7],
Jung Hwan Baek
Won Bae Kim[18],

Table 2. Malignancy Risk Stratification according to K-TIRADS and FNA Indications

	Category	US feature	Malignancy risk, %	Calculated malignancy risk (%), overall (LV, HV)	Calculated sensitivity for malignancy (%), overall (LV, HV)	FNA[a]
5	High suspicion	Solid hypoechoic nodule with any of 3 suspicious US features[b]	>60	79.3 (60.9, 84.9)	51.3 (35.9, 56.7)	≥1 cm (>0.5 cm, selective)
4	Intermediate suspicion	Solid hypoechoic nodule without any of 3 suspicious US features[b] or Partially cystic or isohyperechoic nodule with any of 3 suspicious US features[b]	15–50	25.4 (15, 33.6)	29.5 (29.9, 29.4)	≥1 cm
3	Low suspicion	Partially cystic or isohyperechoic nodule without any of 3 suspicious US features[b]	3–15	7.8 (6, 10.3)[c]	19.2 (34.2, 13.9)	≥1.5 cm
2	Benign[d]	Spongiform Partially cystic nodule with comet tail artifact Pure cyst	<3 <1	0 0	0 0	≥2 cm NA
1	No nodule	-	-	-	-	NA

Adapted from Shin et al. [9]. LV and HV indicate low and high cancer volume data, respectively. Solid hypoechoic nodules include solid nodules with marked or mild hypoechogenicity.

K-TIRADS, Korean Thyroid Imaging Reporting and Data System; FNA, fine needle aspiration; US, ultrasonography; LV, low volume; HV, high volume; NA, not applicable for FNA.

[a]FNA is indicated regardless of size and US feature of nodule in presence of poor prognostic factors including suspected lymph node metastasis by US or clinical evaluation, suspected extrathyroidal tumor extension, patients with diagnosed distant metastasis from thyroid cancer; [b]Microcalcification, non-parallel orientation (taller-than-wide), spiculated/microlobulated margin; [c]Malignancy risk calculated from nodules excluding spongiform or partially cystic nodules with comet tail artifacts; [d]K-TIRADS 2 (benign category) includes partially cystic nodules with spongiform appearance or comet tail artifacts which do not have any suspicious US feature.

Zettinig 2018

Ultrasound criteria for risk stratification of thyroid nodules in the previously iodine deficient area of Austria. A single center, retrospective analysis.

Tugendsam, Zettinig et. al., Thyroid research, submitted

Table 2a: Chi square statistics: Number (%) of positive criteria - BN versus cancer

BN vs. cancer:	**BN** (n=142)	**Cancer** (n=53)	X^2	p-value
Mild hypoechogenicity	55 (38,7%)	19 (35,8%)	0,136	0,712
Marked hypoechogenicity	26 (18,3%)	22 (41,5%)	11,194	0,001
Microlobulated / irregular margins	39 (27,5%)	29 (54,7%)	12,621	0,0004
Microcalcifications	10 (7,0%)	16 (30,2%)	17,894	0,00002
Taller than wide	17 (12,0%)	15 (28,3%)	7,503	0,006
No thin halo	99 (69,7%)	47 (88,7%)	7,375	0,007

Table 3a: Diagnostic parameters for cancer

Cancer	Sensitivity	Specificity	PPV	NPV
Mild hypoechogenicity	36%	61%	26%	72%
Marked hypoechogenicity	42%	82%	46%	79%
Microlobulated / irregular margins	55%	73%	43%	81%
Microcalcifications	30%	93%	62%	78%
Taller than wide	28%	88%	47%	77%
No thin halo	89%	30%	32%	88%

Table 4: Mean number of positive ultrasound criteria in BN and in all cancer patients as well as in the subgroups of PTC and FTC.

	BN (n=142)	Cancer (n=53)	PTC (n=45)	FTC (n=8)
Mean number of criteria	1.73 ± 1.18	2.79 ± 1.35*	2.98 ± 1.32*	1.75 ± 1.04 **
* BN vs. Vancer: p < 0.001				
* PTC vs. BN: p < 0.001, PTC vs. FTC: P = 0.026				
** FTC vs. BN: p > 0.99, FTC vs. PTC: p = 0.026				

Clinical Thyroidology / Original Paper

European Thyroid Journal

Eur Thyroid J 2017;6:101–107
DOI: 10.1159/000452971

Received: September 21, 2016
Accepted after revision: October 31, 2016
Published online: December 13, 2016

"Nodule in Nodule" on Thyroid Ultrasonography: Possibility of Follicular Carcinoma Transformed from Benign Thyroid Tumor

Kaoru Kobayashi Hisashi Ota Mitsuyoshi Hirokawa Tomonori Yabuta Mitsuhiro Fukushima Hiroo Masuoka Takuya Higashiyama Minoru Kihara Yasuhiro Ito Akihiro Miya Akira Miyauchi

Kuma Hospital, Kobe, Japan

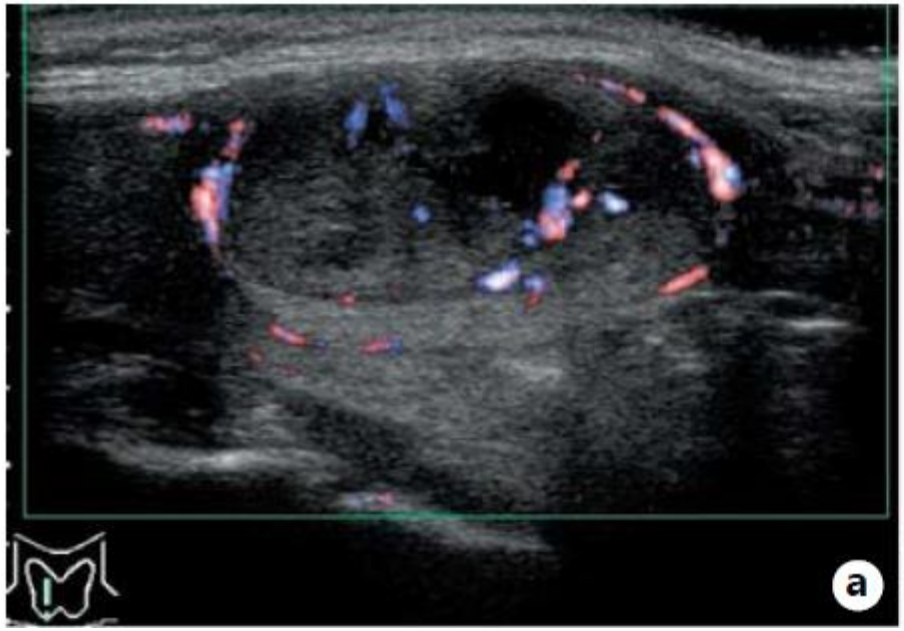

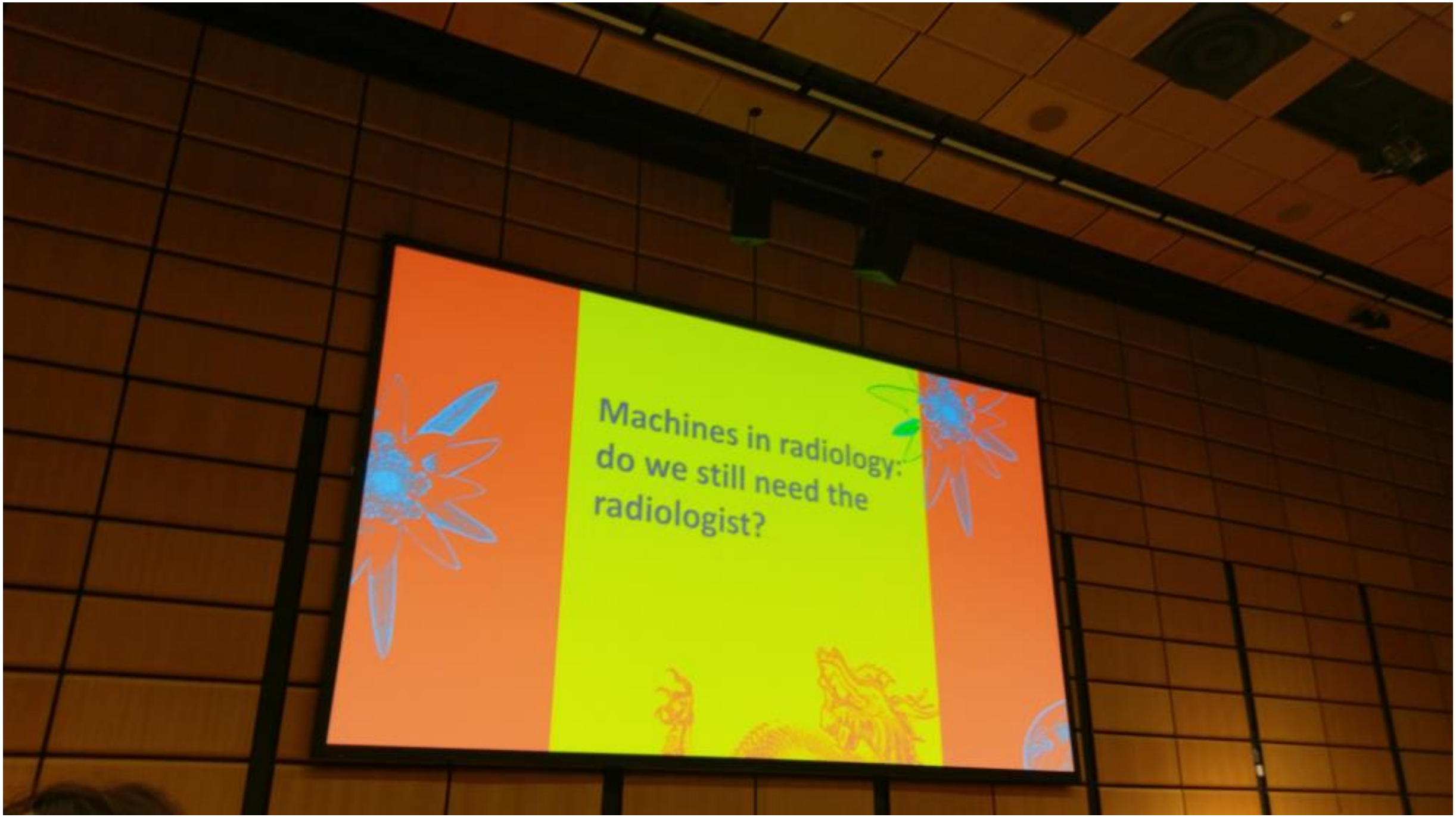
Machines in radiology:
do we still need the
radiologist?

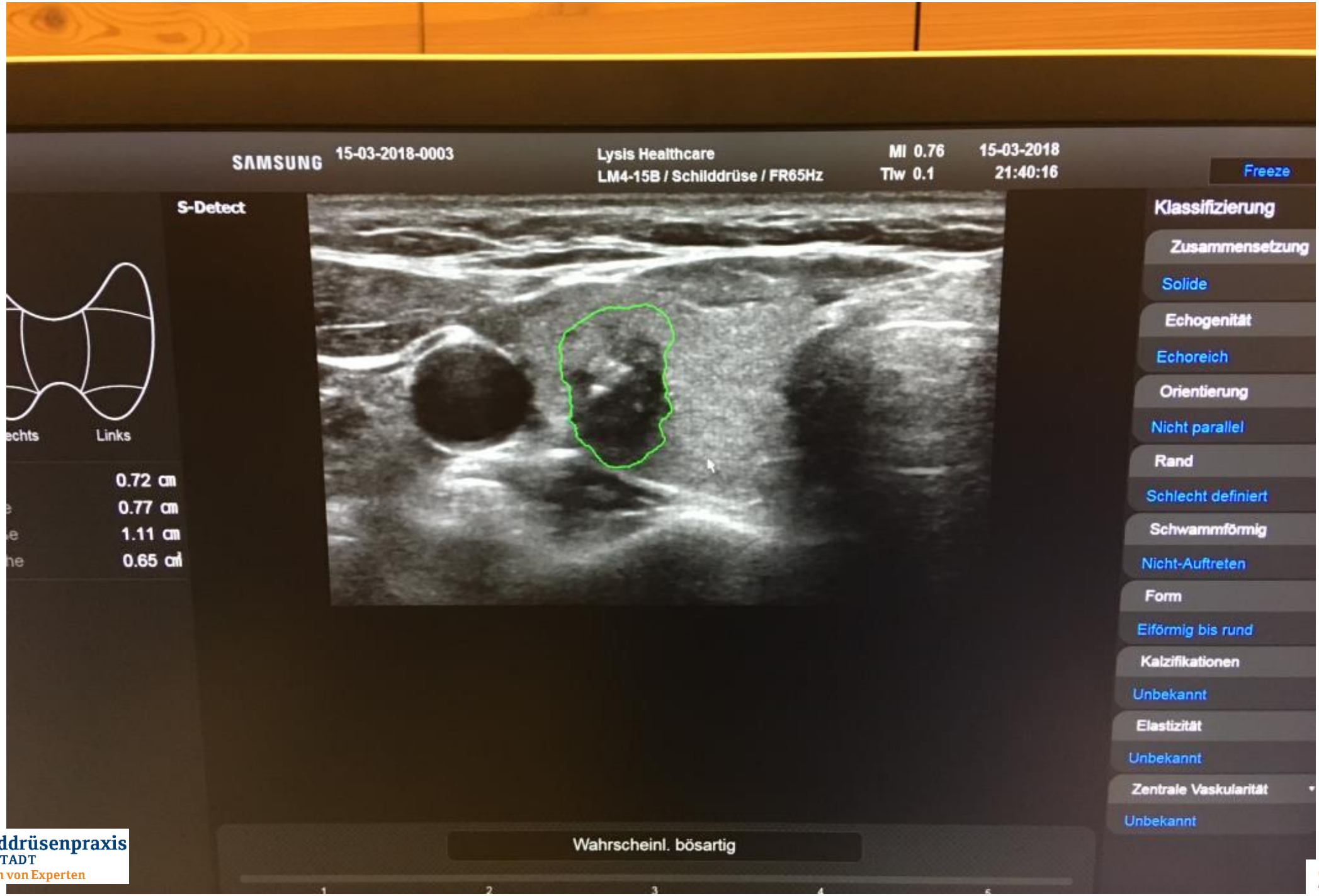

Schilddrüsenpraxis
JOSEFSTADT
Ihr Team von Experten

Zettinig 2018


Erster Mediterraner
SCHILDDRÜSENKURS
28. April – 4. Mai 2018
Sorrent, Italien
ÖSTERREICHISCHE
SCHILDDRÜSENGESELLSCHAFT
AUSTRIAN THYROID ASSOCIATION