SCHILDDRÜSEN INSTITUT

Medizinische Universität Graz

Schilddrüsenchirurgie jenseits der Schilddrüse

Chirurgie der Knochen

Universitätsklinik für Orthopädie und Traumatologie
Medizinische Universität Graz

Priv. Doz. DDr. Jörg Friesenbichler
Stv. Sektionsleiter Tumorchirurgie

Kurgan Tuva, Southern Sibiria

Int. J. Cancer: **121,** 2591–2595 (2007)

Oldest known case of metastasizing prostate carcinoma diagnosed in the skeleton of a 2,700-year-old Scythian King from Arzhan (Siberia, Russia)

Michael Schultz[1]*, Hermann Parzinger[2], Dmitrij V. Posdnjakov[3], Tatjana A. Chikisheva[3] and Tyede H. Schmidt-Schultz[4]

[1]*Department of Anatomy, University of Göttingen, Germany*
[2]*German Archaeological Institute (DAI), Berlin, Germany*
[3]*Institute of Archaeology, Russian Academy of Sciences, Novosibirsk, Russia*
[4]*Department of Biochemistry, University of Göttingen, Germany*

To determine whether a 2,700-year-old tumor can be reliably diagnosed using microscopic and proteomic techniques and whether such prostate carcinomas show the same morphological pattern at the micro-level as modern-day carcinomas, this case was investigated. A 40–50-year-old Scythian king who lived during the Iron Age in the steppe of Southern Siberia (Russia) suffered from macroscopically visible osteoblastic and osteoclastic lesions throughout his entire skeleton. Macro-morphological (macroscopy, endoscopy, radiology) and micro-morphological techniques (histology, scanning-electron microscopy) as well as proteomic techniques (1-D- and 2-D-electrophoresesis, Western blot) were applied. The results of the morphological and biochemical investigation proved that this mature male suffered for many years from and probably died of a carcinoma of the prostate. The diagnosis mainly rests on the results of the microscopic examination of the lesions and the positive evidence of PSA, which is an important marker for the diagnosis of prostate cancer. It is remarkable that, in this ancient case, the morphological pattern at the microlevel is the same as in recent cases. The loss of the spongy bone substance (red bone marrow) provoked chronic anemia during the final months of the life of this king. The proteomic techniques applied are new for the investigation of recent and ancient macerated bones. Sensitive and reliable biochemical markers (PSA) are an important precondition to every step of metabolism and now we also have a tool to establish a reliable diagnosis at the level of intact proteins from the Scythian ruler of Arzhan, who lived 2,700 years ago.

Material and methods

Materials

The relatively well-preserved skeleton of a 40–50-year-old unknown Scythian king excavated over a period between 2000 and 2003 from Kurgan 2, burial 5 at Arzhan near Tuva (southern Siberia, Russia), and dating from the 7th century BC represents an undisturbed burial, which is one of the richest graves from the Eurasian Steppes and contained about 9,600 objects, more than 6,000 made of gold.[4]

Samples for the microscopic and biochemical analysis are as follows: (*i*) Arzhan Kurgan 2, burial 5, individual 1, male, 40–50-year-old. For light and scanning-electron microscopy, samples were taken from the right parietal bone, the right humerus, the right femur, the body of the seventh thoracic vertebra and the left fourth and fifth rib. For biochemistry, a sample was taken from the

Interactive Map of Cancer Incidence, World, 2012 Estimates

Cancer incidence — Worldwide

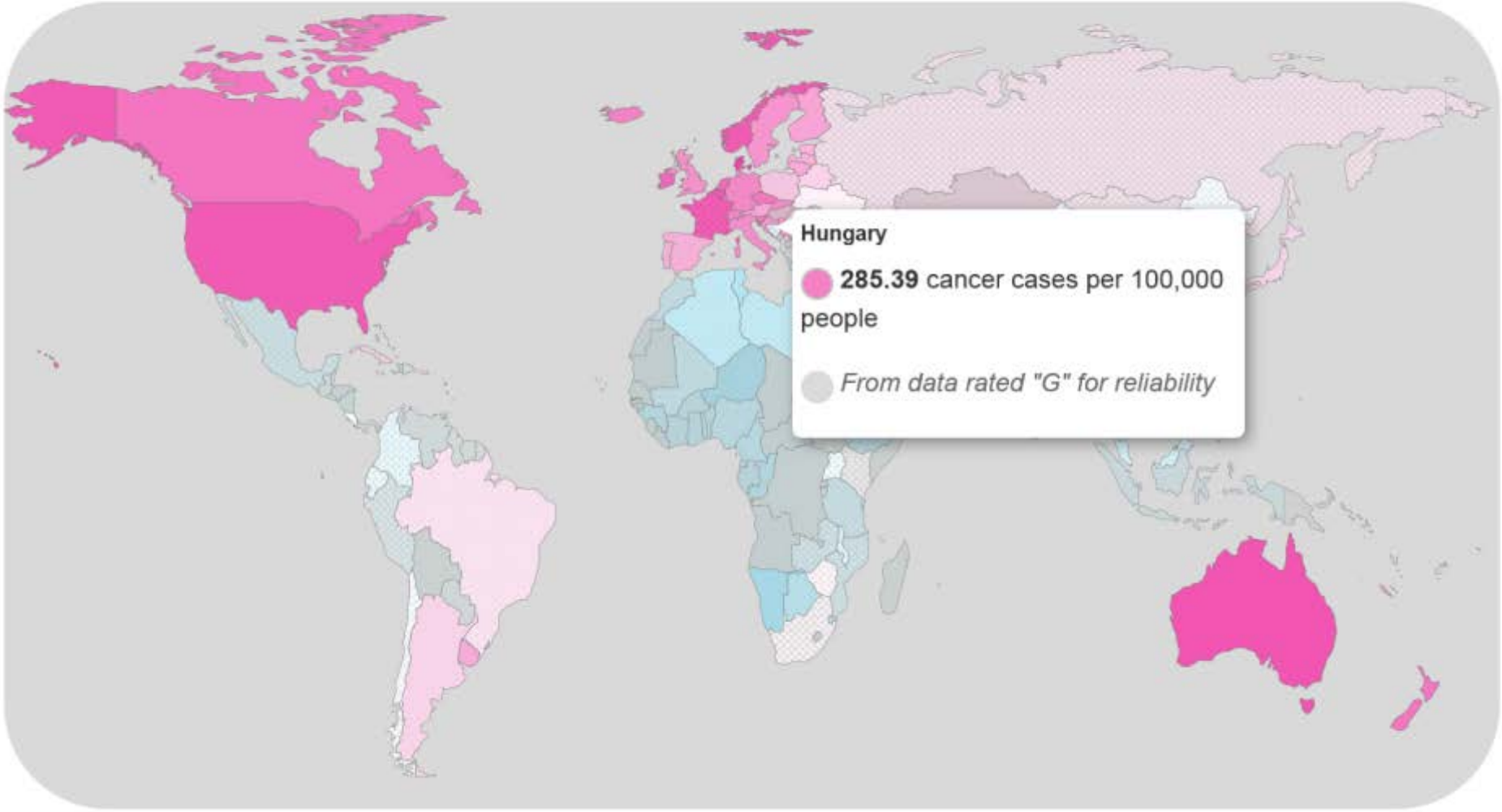

Worldwide cancer incidence — 14,090,149 new cancer cases per year:

Cancer survival in Europe 1999–2007 by country and age: results of EUROCARE-5—a population-based study

*Roberta De Angelis, Milena Sant, Michel P Coleman, Silvia Francisci, Paolo Baili, Daniela Pierannunzio, Annalisa Trama, Otto Visser, Hermann Brenner, Eva Ardanaz, Magdalena Bielska-Lasota, Gerda Engholm, Alice Nennecke, Sabine Siesling, Franco Berrino, Riccardo Capocaccia, and the EUROCARE-5 Working Group**

Summary

Background Cancer survival is a key measure of the effectiveness of health-care systems. EUROCARE—the largest cooperative study of population-based cancer survival in Europe—has shown persistent differences between countries for cancer survival, although in general, cancer survival is improving. Major changes in cancer diagnosis, treatment, and rehabilitation occurred in the early 2000s. EUROCARE-5 assesses their effect on cancer survival in 29 European countries.

Lancet Oncol 2014; 15: 23–34

Published Online
December 5, 2013
http://dx.doi.org/10.1016/S1470-2045(13)70546-1

See Comment page 2

ne Universität Graz

Cancer survival in
results of EUROCA

Roberta De Angelis, Milena Sant, Michel P C
Hermann Brenner, Eva Ardanaz, Magdalen
*and the EUROCARE-5 Working Group**

Summary

Background Cancer survival is a k
cooperative study of population-bas
for cancer survival, although in ge
and rehabilitation occurred in the
countries.

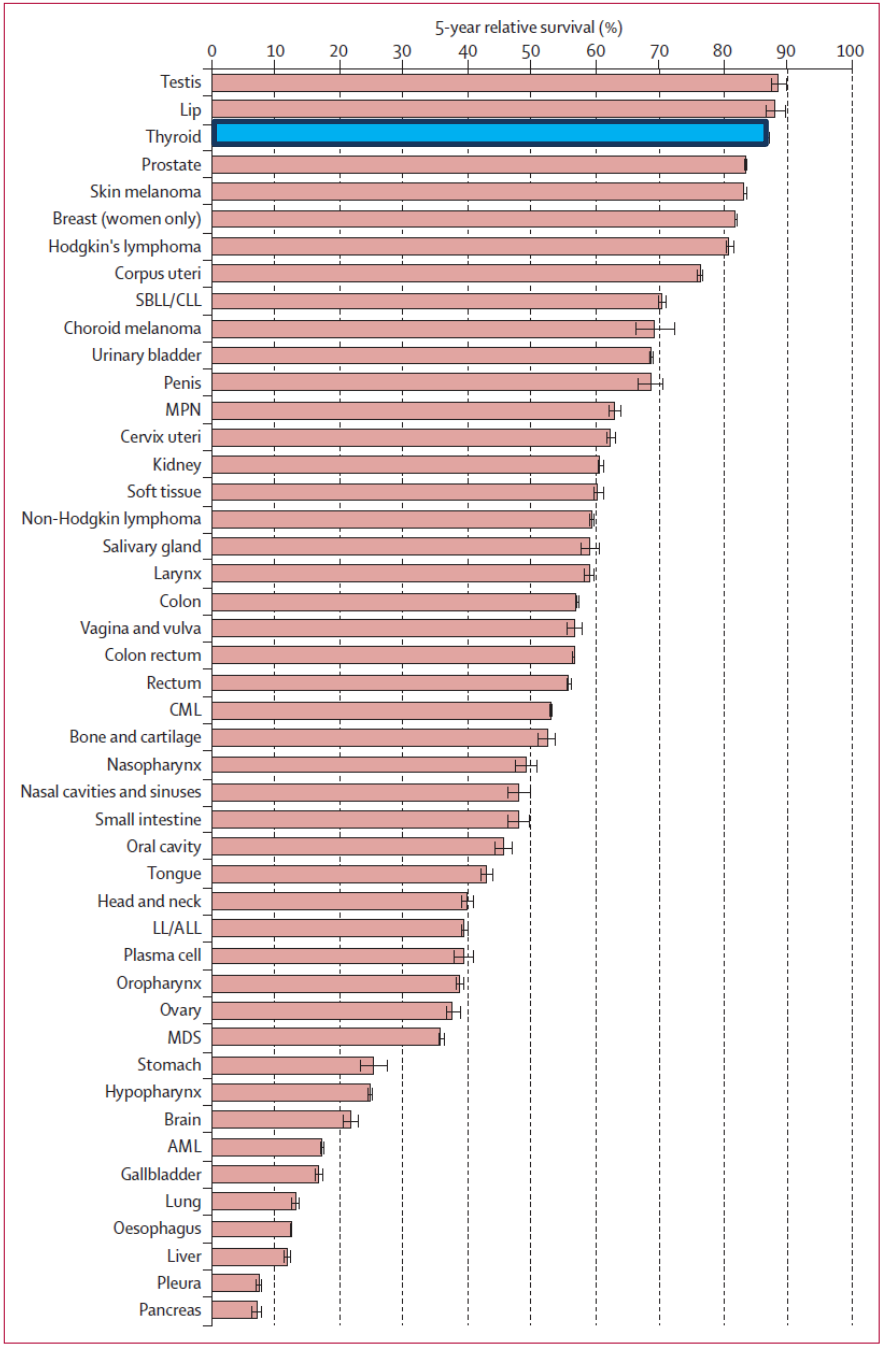

Figure 1: European mean age-standardised 5-year relative survival for adult patients with cancer diagnosed in 2000–2007

:accia,

rgest
ıtries
nent,
pean

Lancet Oncol 2014; 15: 23–34
Published Online
December 5, 2013
http://dx.doi.org/10.1016/S1470-2045(13)70546-1

See Comment page 2

Medizinische Universität Graz

Operatives Setting bei Knochenmetastasen

Fälle Orthopädie Graz

Medizinische Universität Graz

1998 – 2015:

- 805 Pat mit Knochenmetastasen operiert
  - .... Brust, Lunge & Multiples Myelom
  - 76 Prostatae
  - 58 NCC
  - 12 Schilddrüse

Metastasenchirurgie

Singuläre Metastasen

- ein „Herd“
- sonstiges Staging bland (CT Th/Abd./B, Szinti)

→ weite Resektion (kurativer Ansatz)

- Schmerzreduktion
- Stabilisierung
- Postop. Procedere
  - CTx & RTx

Metastasenchirurgie

Multiple Metastasen (palliatives Setting)

- Schmerzreduktion
- Stabilisierung
  - Frakturprophylaxe
  - Osteosynthese/Endoprothetik bei patholog. Fraktur
- Schnellst mögliche Re-Mobilisation bei SREs
- Postop. Procedere (i.A. vom Allgemeinzustand)
  - Pall. CTx, RTx, BSC

Ätiologie Knochenmetas

Medizinische Universität Graz

„seed and soil“

Paget S. Lancet 1889;1:571-3

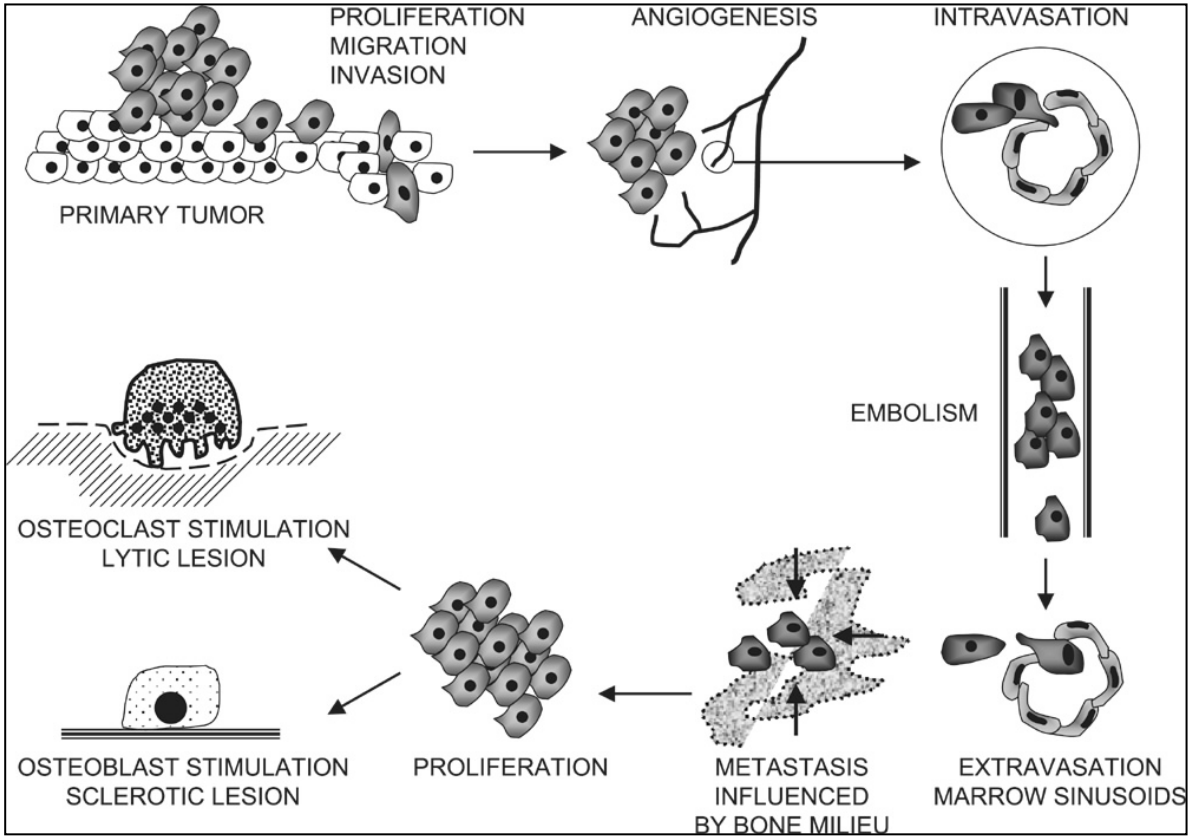

Choong PFM. Clin Orthop 2003;415S:S19-31

Lokalisation

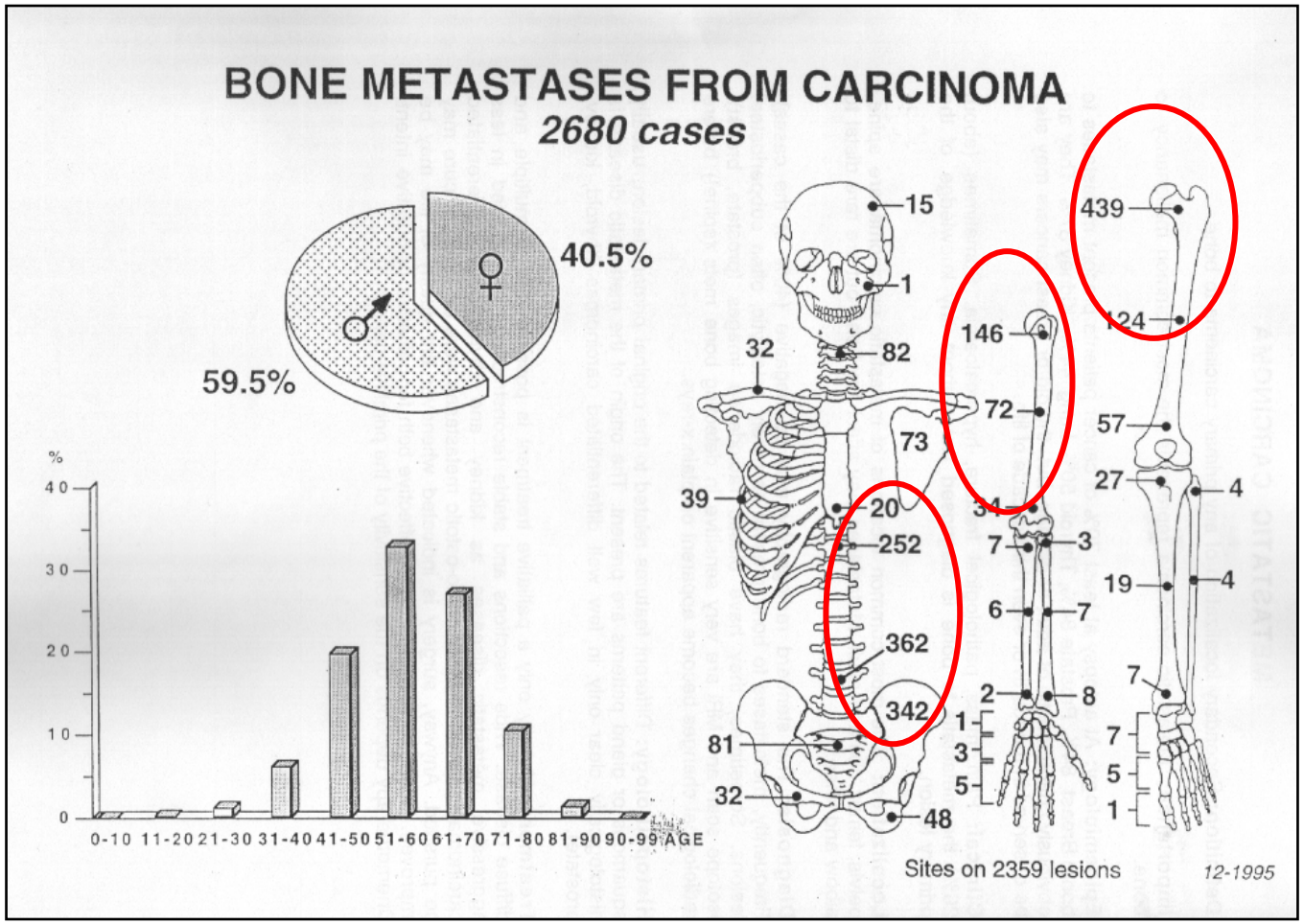

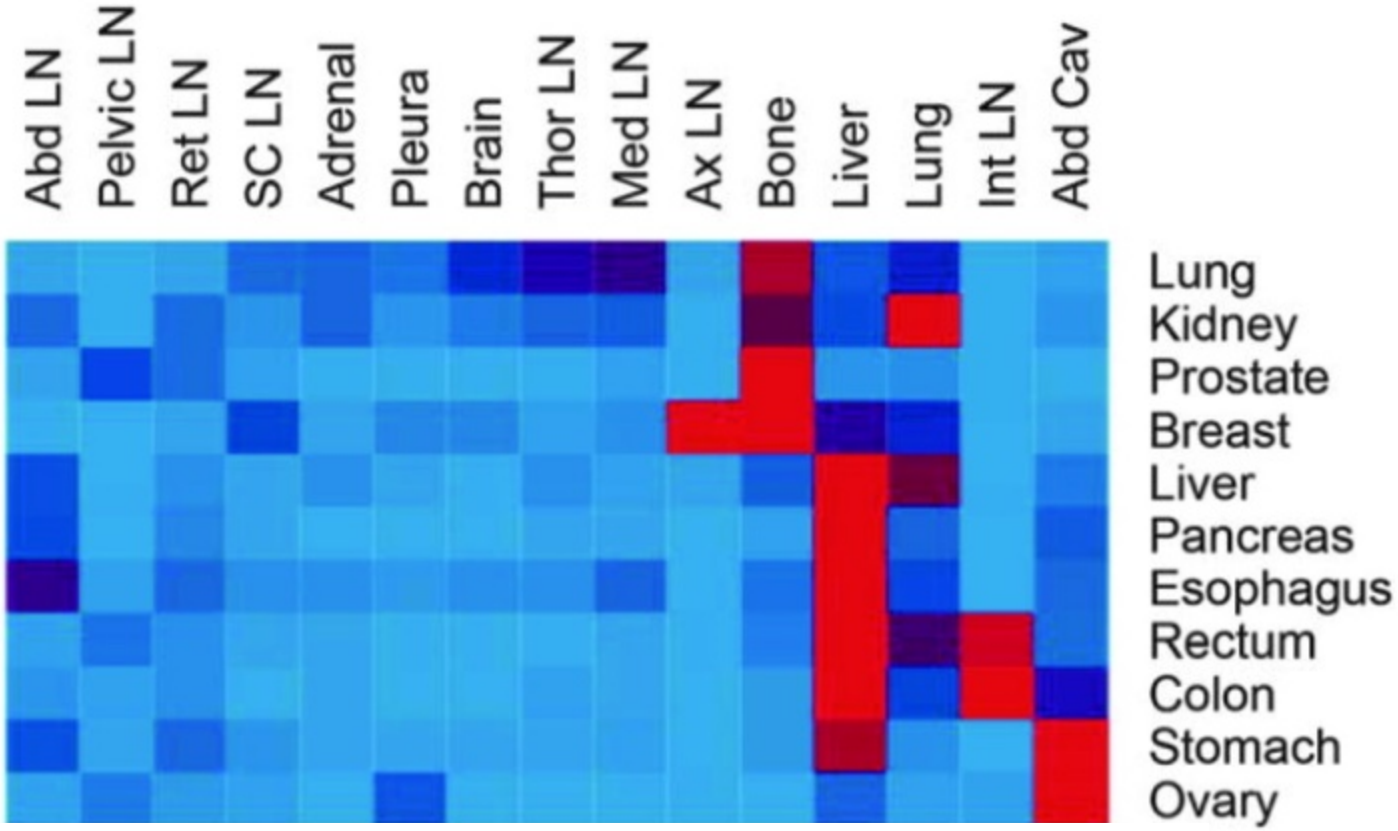

Hess KR et al, Cancer 2006

Table 1. Incidence of bone metastases at postmortem examination in different cancers

Primary tumor	Incidence of bone metastases (%)
Breast	73
Prostate	68
Thyroid	42
Kidney	35
Lung	36
Gastrointestinal tract	5

NOTE: Data are adapted from Galasko (1) and presented as a table.

Coleman RE, Clin Cancer Res 2006

Metastasen und SREs

Medizinische Universität Graz

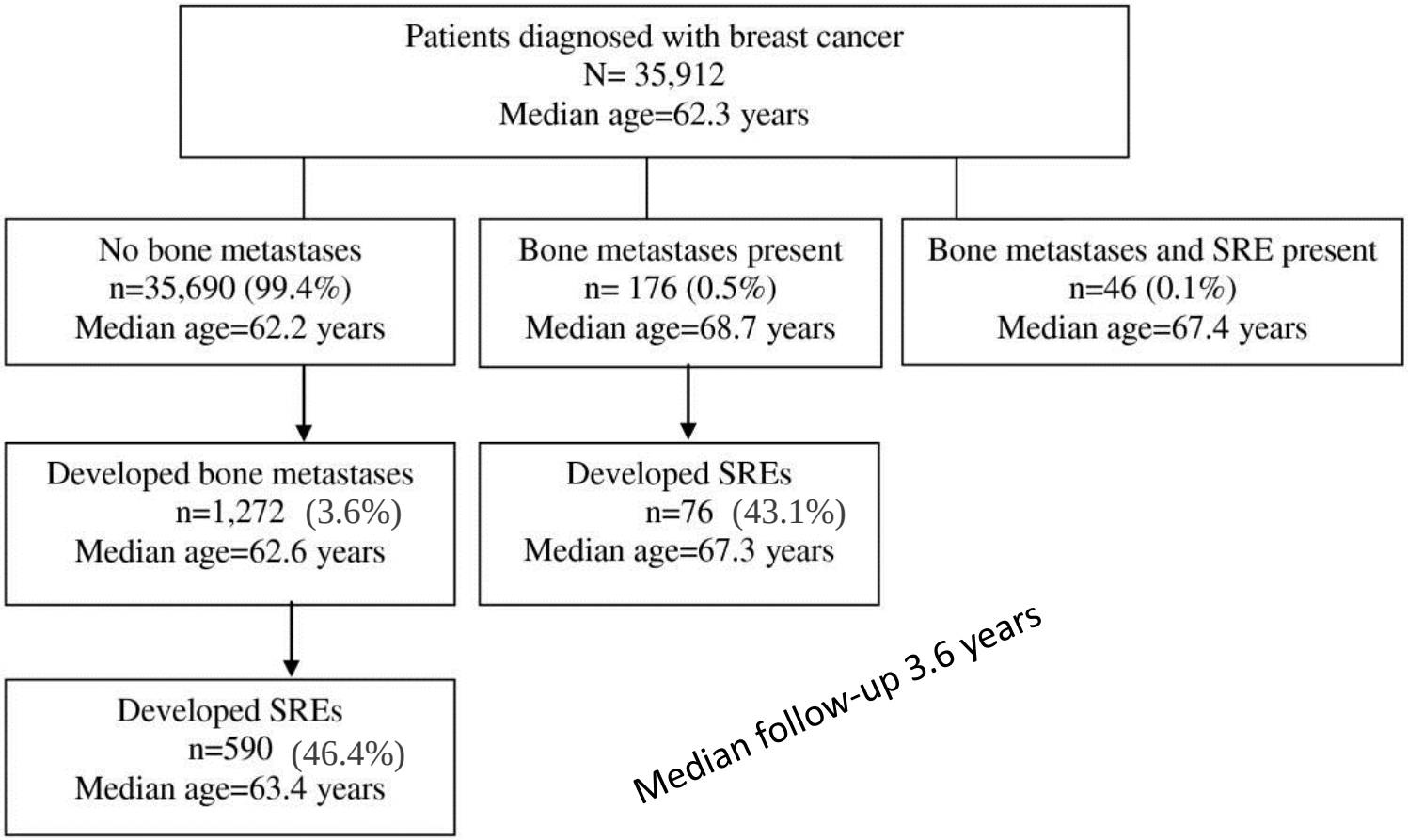

Median follow-up 3.6 years

Jensen AO, BMC Cancer 2011

Special Report

EXPERT REVIEWS

Management of long bone metastases: recommendations from the Italian Orthopaedic Society bone metastasis study group

Expert Rev. Anticancer Ther. 14(10), 1127–1134 (2014)

Rodolfo Capanna[1], Andrea Piccioli[2], Alberto Di Martino*[3], Primo Andrea Daolio[4], Vincenzo Ippolito[5], Giulio Maccauro[6], Raimondo Piana[7], Pietro Ruggieri[8], Alessandro Gasbarrini[8], Maria Silvia Spinelli[6], Domenico Andrea Campanacci[2] and The Italian Orthopaedic Society Bone Metastasis Study Group[9]

The purpose of this article is to outline the current approach to patients affected by metastasis to the long bones and to present a clinical and surgical algorithm available for clinicians and for future research. A modern approach to patients affected by long bone metastasis in fact requires a multidisciplinary contest where oncologists, radiotherapists, surgeons and physical therapists cooperate with a shared vision, in order to provide the best possible integrated treatments available. The authors of this article constitute the Bone Metastasis Study Group of the Italian Orthopaedic Society (SIOT): a national group of orthopedic tumor surgeons who are dedicated to studying the approach, techniques and outcomes of surgery for metastatic tumours of the musculoskeletal system.

Keywords: algorithm • appendicular skeleton • bone metastasis • long bones • palliative therapy • recommendations • surgery

Approaching patients with metastasis to the long bones

Metastatic disease to the bone can often be considered an asymptomatic event; however,

Over the past two decades, much research has been directed towards the selection of prognostic factors for patients affected by bone metastases (Table 1) and some authors proposed scoring systems for the staging of patients

EOR | VOLUME 1 | MAY 2016
DOI: 10.1302/2058-5241.1.000008
www.efort.org/openreviews

EFORT open reviews

Treatment of pathological fractures of the long bones

Julie J. Willeumier
Yvette M. van der Linden
Michiel A.J. van de Sande
P.D. Sander Dijkstra

- Bone metastases of the long bones often lead to pain and pathological fractures. Local treatment consists of radiotherapy or surgery. Treatment strategies are strongly based on the risk of the fracture and expected survival.
- Diagnostic work-up consists of CT and biopsy for diagnosis of the primary tumour, bone scan or PET-CT for dissemination status, patient history and blood test for evaluation of general health, and biplanar radiograph or CT for evaluation of the involved bone.
- A bone lesion with an axial cortical involvement of >30 mm has a high risk of fracturing and should be stabilised surgically.
- Expected survival should be based on primary tumour type, performance score, and presence of visceral and cerebral metastases.
- Radiotherapy is the primary treatment for symptomatic lesions without risk of fracturing. The role of post-operative radiotherapy remains unclear.
- Main surgical treatment options consist of plate fixation, intramedullary nails and (endo) prosthesis. The choice of modality depends on the localisation, extent of involved bone, and expected survival. Adjuvant cement should be considered in large lesions for better stabilisation.

unfortunately gives each patient more time to develop metastases.

Bone metastases of the long bones may lead to pain, pathological fractures, immobility, decreased functioning, and hypercalcaemia. Over half of patients experience clinical symptoms for which treatment is required,[3] of whom only a minority are surgically treated.[4] In the long bones, pain is the most common symptom, followed by impending or actual pathological fractures in 10%-25% of patients.[5] Pathological fractures of the femur, 75% of which present in the proximal part, are roughly 3.5 times as common as fractures of the humerus.[6]

This review discusses the local management of (impending) pathological fractures of the long bones, with focus on surgical treatment strategies.

Diagnosis and evaluation

For successful management, the following adage should be followed: stop; think and stage; act. The most important information is gathered with the following four questions and flowchart (Fig. 1).

What is the origin of the lesion?

A bone lesion with unknown aetiology is a primary bone tumour until proven otherwise. Denying this possibility might deprive patients of correct and curative treatments. If the patient has no history of malignancy, a (PET-)CT scan of the chest and abdomen should be performed. In case no primary tumour is visible, a core needle biopsy of the bone lesion should be performed for histological identification

Klinischer Alltag

Untersuchung

Medizinische Universität Graz

1.) Anamnese (Vorgeschichte, Primum bekannt?)

2.) Inspektion & Palpation

3.) (Funktionsprüfung)

4.) allgemeine Diagnostik (Labor, Punktion…)

5.) Bildgebung

- Röntgen
- (Ultraschall)
- MRT + KM
- CT
- PET CT/Skelettszintigraphie

4. allgemeine Diagnostik

- BB, CRP, Tu-Marker, Eiweißelphor…

5. Bildgebung:

– Röntgen immer in 2 Ebenen

– MRT + KM

– CT (Staging Th/Abd./Becken, Stabilitätsbeurteilung)

Beurteilung Frakturgefährdung

♀ 35a, Schmerzen Hüfte links seit 4 Wochen

„einfach“

♂ 60a, metastasiertes Prostata Ca, patholog. # SH re.

Frakturgefahr?

Warnzeichen:

- positive Tumoranamnese
- lange Röhrenknochen
- belastungsabhängige Schmerzen
- Schwellung (pulsierend?)

♀ 68a, Schmerzen Knie rechts seit mehreren Wochen, zuletzt Urosepsis 09-10/17

♀ 68a, 2 Wochen später….genaue Anamnese → Cervix Ca ED 05/17

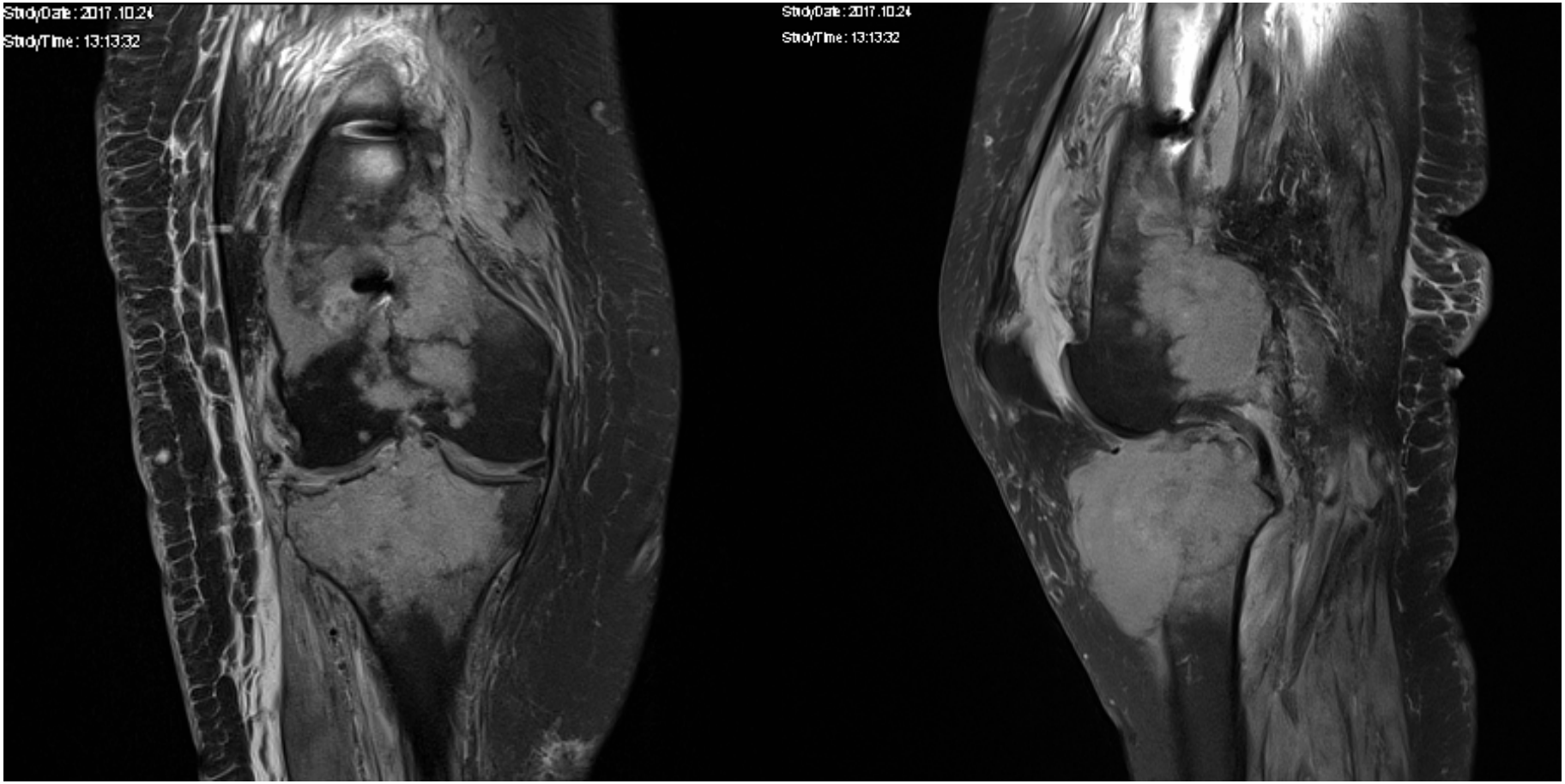

Metastase Cervix Ca

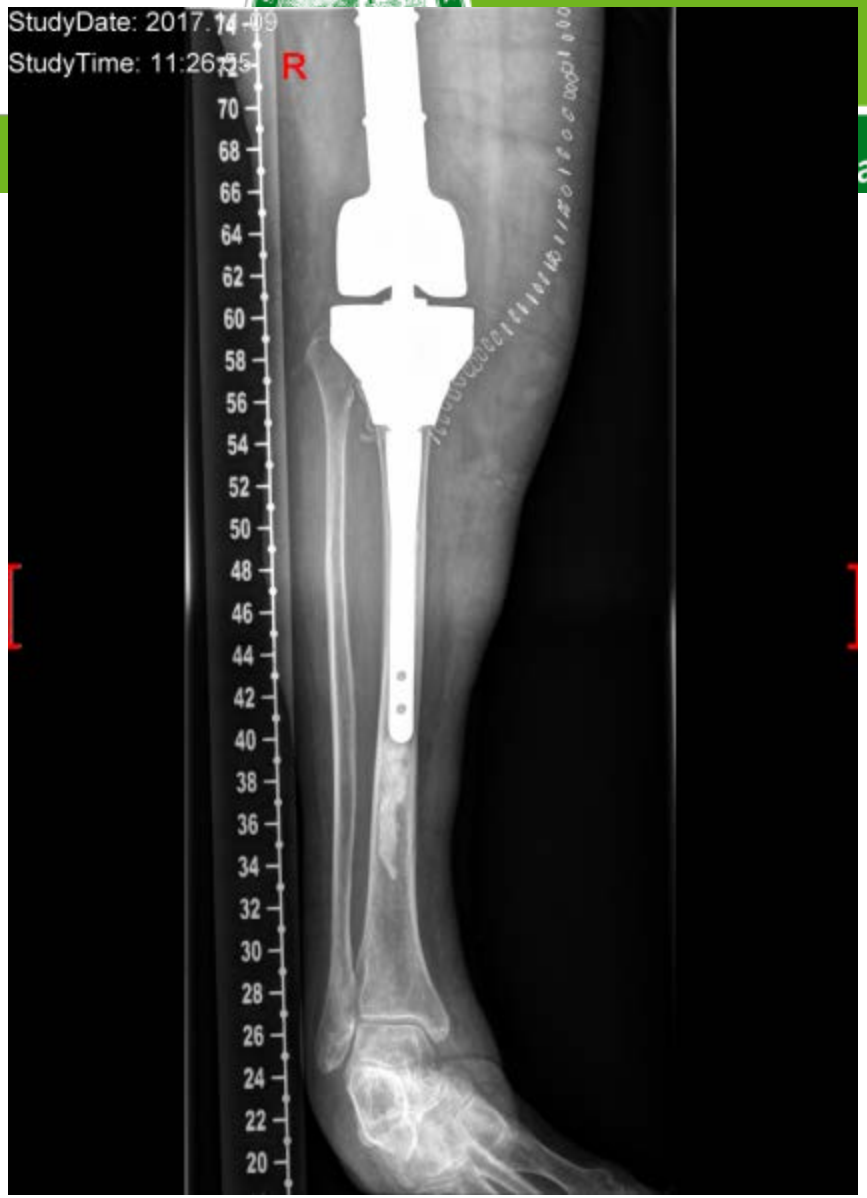

St.p. Implantation distaler Femur & prox. Tibiaersatz, modulare Tumorprothese

Frakturgefahr?

Medizinische Universität Graz

- große corticale Osteolysen
- axialer Befall > 50%
- „strahlenresistente“ Osteolysen

Harrington KD Clin Orthop 1982;169:53.

Indikationen zur OP

Medizinische Universität Graz

Mirels Score

TABLE 1. Scoring System

	Score		
Variable	*1*	*2*	*3*
Site	Upper limb	Lower limb	Peritrochanter
Pain	Mild	Moderate	Functional
Lesion	Blastic	Mixed	Lytic
Size	<1/3	1/3–2/3	>2/3

Mirels H. Clin Orthop 1989;249:256-64.

TABLE 5. Conditional Probability of Fracture for Each Score

Score	*Fracture*	*Nonfracture*	*False Positive*	*True Positive*	*Fracture Probability*
4	0	4	91%	100%	0
5	0	10	75%	100%	0
6	0	8	56%	100%	0
7	1	18	22%	96%	0.04
8	4	8	6%	85%	0.15
9	4	3	0%	66%	0.33
10	13	0	0%	18%	0.72
11	4	0	0%	4%	0.96
12	1	0	0%	0%	1.00

Wann Biopsie?

Medizinische Universität Graz

…wenn unklar ob Primum oder Metastase

…multiple Absiedelungen, Primum unbekannt

…Primum > 5 Jahre zurück

…Radiologie nicht „typisch“ – Zweittumor?

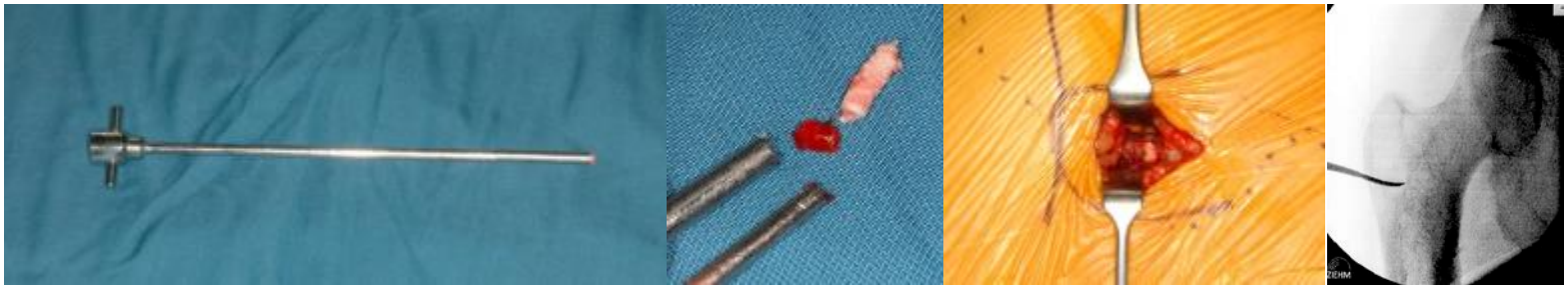

Biopsie

Medizinische Universität Graz

Jede Läsion wird behandelt wie ein primärer Tumor bis das Gegenteil bewiesen ist

10 Gebote der Biopsie

1. Kein Schnitt ohne Bildgebung
2. Zeit nehmen, keine Eile
3. Biopsie so planen, dass eine adäquate Resektion möglich ist
4. Wähle den kürzesten Weg durch ein Kompartment
5. Atraumatische OP-Technik (stumpfes Instrumentarium)
6. Gefäße, Nerven und Gelenke nicht kontaminieren
7. Vermeidung ein postoperativen Hämatoms
8. Drainage einlegen und durch Wunde ausleiten
9. Gewinnung von genug Material
10. Zusammenarbeit mit einem/er erfahrenen Pathologen/in

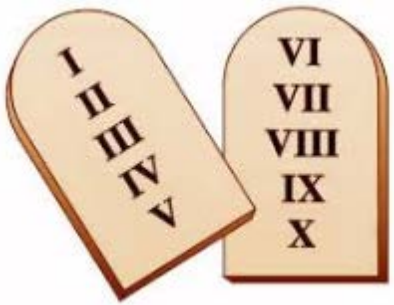

Behandlungsalgorithmus

Medizinische Universität Graz

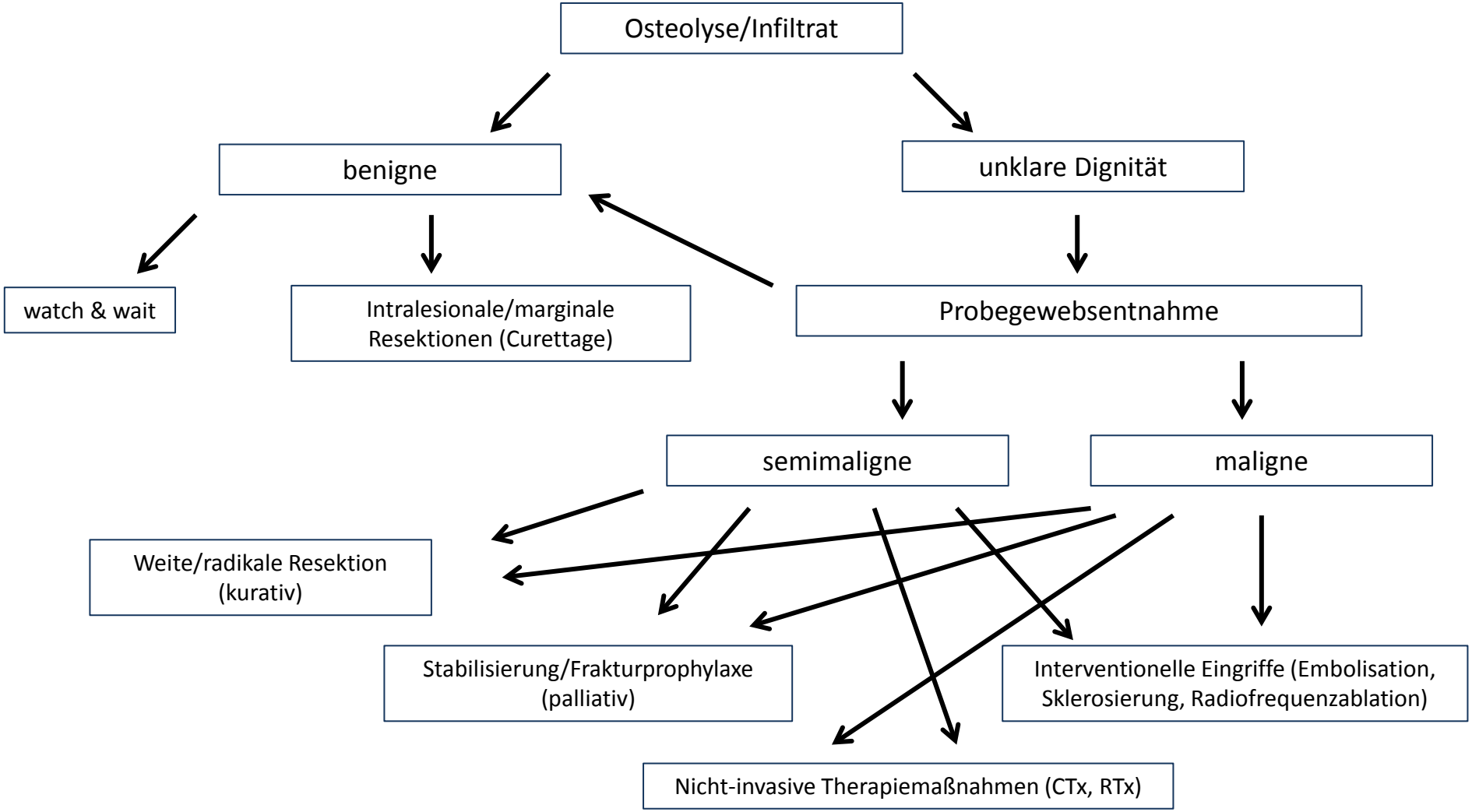

Resektionstechniken

Medizinische Universität Graz

intraläsional

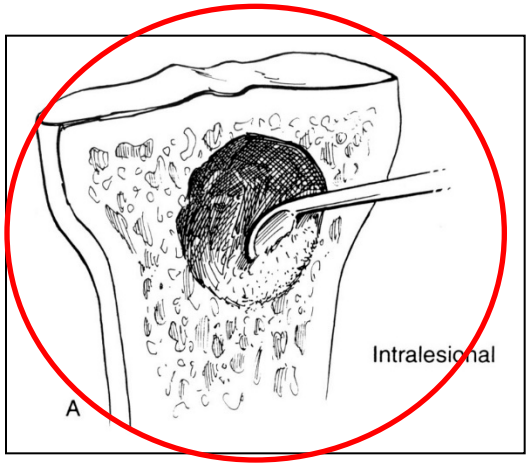

marginal

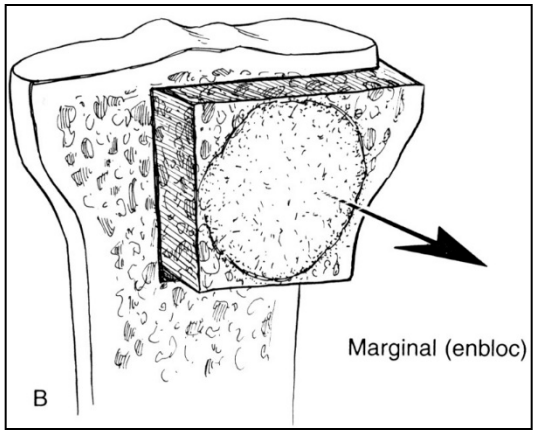

weit

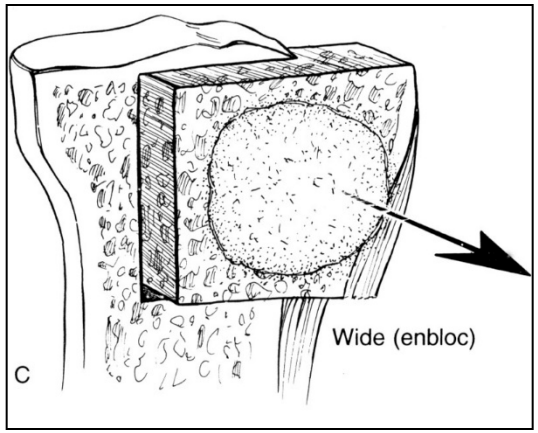

Resektionstechniken

Medizinische Universität Graz

W

…

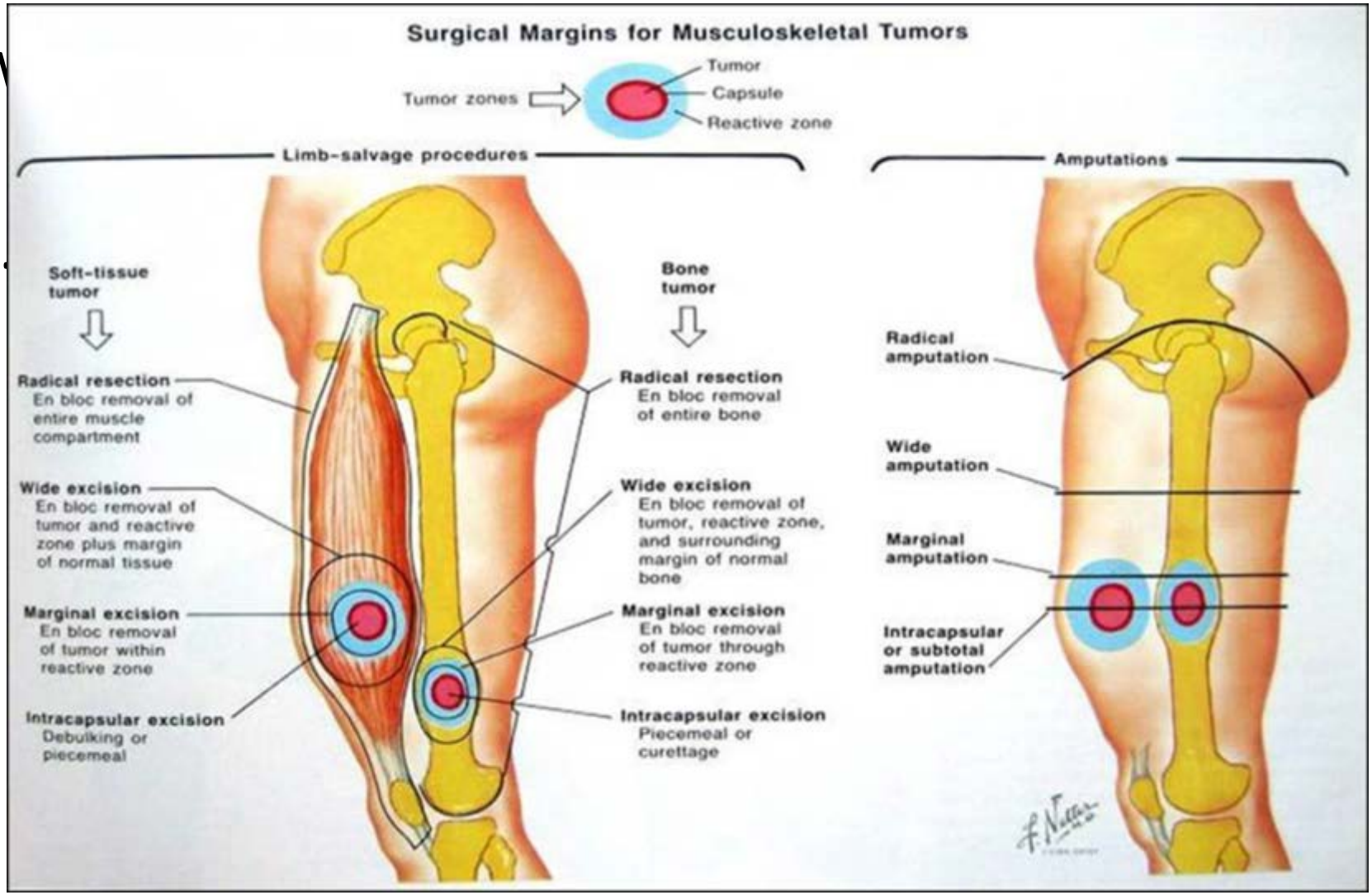

OP-Prinzipien

<u>Multiple Metastasen:</u>

save, short, simple

(cheap)

Indikation hängt ab von…

…Erwartung des Patienten
…Prognose
…Erfahrung des Chirurgen
…Lokalisation

Ziele

Stabilität/Mobilität
Lebensqualität
Schmerzfreiheit

konservativ

operativ

Extremitätenversorgung

Konservativ

Nägel (+/- Zement)

Platten (+/- Zement)

} Verbundosteosynthese

Endoprothesen (+/- Zement)

Modulare Tumorendoprothesen (+/- Zement)

OPTIModel

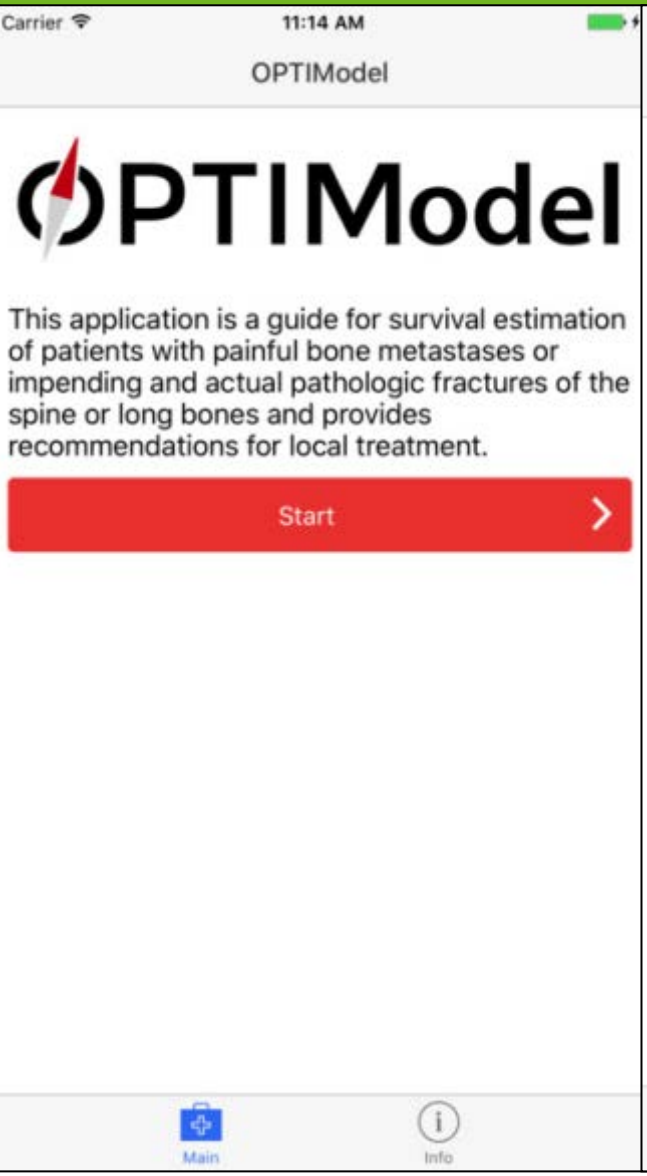
Carrier
11:14 AM
OPTIModel
OPTIModel
This application is a guide for survival estimation of patients with painful bone metastases or impending and actual pathologic fractures of the spine or long bones and provides recommendations for local treatment.
Start
Main
Info

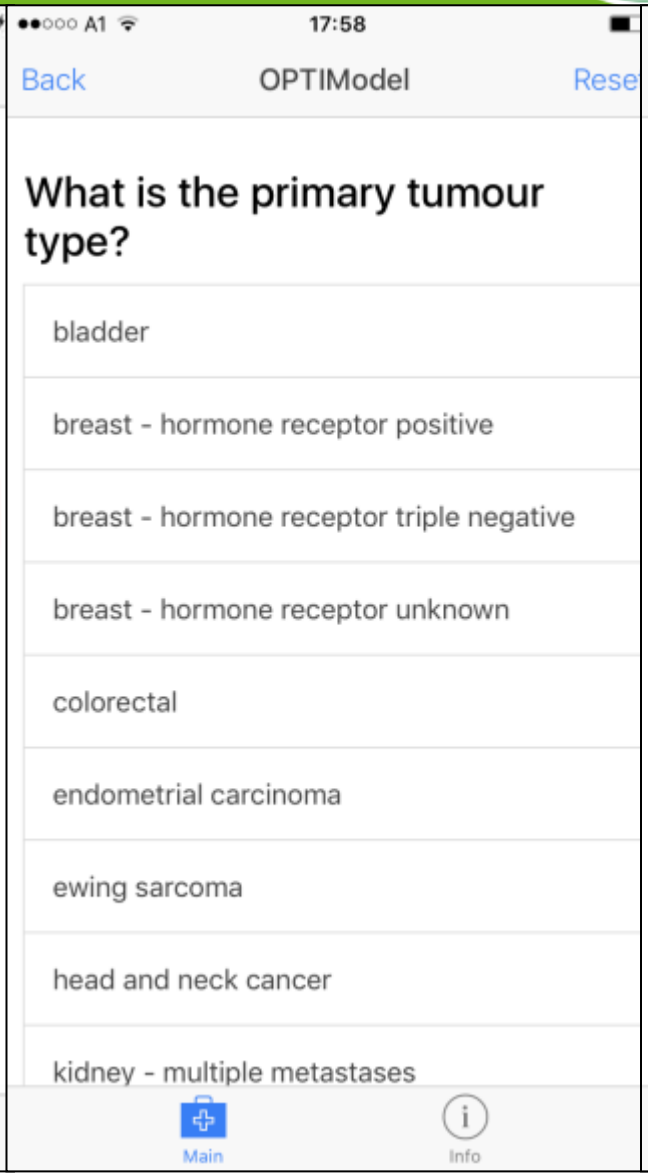
A1
17:58
Back
OPTIModel
Rese
What is the primary tumour type?
bladder
breast - hormone receptor positive
breast - hormone receptor triple negative
breast - hormone receptor unknown
colorectal
endometrial carcinoma
ewing sarcoma
head and neck cancer
kidney - multiple metastases
Main
Info

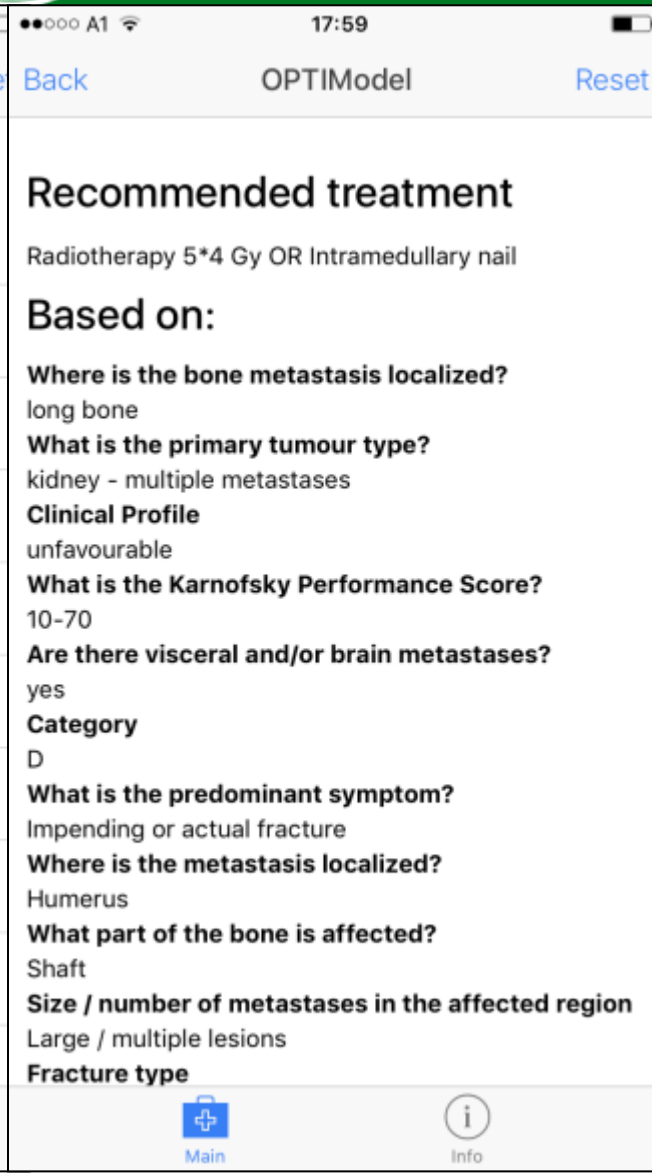
A1
17:59
Back
OPTIModel
Reset
Recommended treatment
Radiotherapy 5*4 Gy OR Intramedullary nail
Based on:
Where is the bone metastasis localized?
long bone
What is the primary tumour type?
kidney - multiple metastases
Clinical Profile
unfavourable
What is the Karnofsky Performance Score?
10-70
Are there visceral and/or brain metastases?
yes
Category
D
What is the predominant symptom?
Impending or actual fracture
Where is the metastasis localized?
Humerus
What part of the bone is affected?
Shaft
Size / number of metastases in the affected region
Large / multiple lesions
Fracture type
Main
Info

Fallbeispiele Ortho Graz

Medizinische Universität Graz

No.	Primum	ED	Alter ED	Rezidive	Status bei Erstvorstellung	OP Indiaktion	Therapie	Alter OP	Postop. Th.	FU (Mo.)	Status
1	follikuläres Ca	1974	36	1988	Fil. pulm., Fil. oss. mult.	patholog. # Humerus rechts	Verbundosteosynthese (Nagel, Zement)	68	RTx	32	DOD
2	follikuläres Ca	2004	72		Fil. pulm., Fil. oss. mult.	Osteolyse prox. Femur rechts	Verbundosteosynthese (Paltte, Zement)	74	RTx	37	DOD
3	follikuläres Ca	2008	31			Osteolyse Os pubis links	Curettage, Zement	31		8	LTFU
4	follikuläres Ca	1964	15	1997	Fil. oss. mult.	Osteolyse gesamtes Femur links	Embolisation, totaler Femurersatz	60	RTx	29	DOD
5	follikuläres Ca	2010	71		Fil. oss. mult.	Osteolyse 4. Rippe rechts	offene PE	73	RTx	57	AWD
6	follikuläres Ca	1998	49	2011	Fil. pulm., Fil. oss. mult., Fil. Lnn	Ostelyse BWK 6	Embolisation, RFA	63	RTx	74	AWD
7	follikuläres Ca	2013	75			Osteolyse Proc. Spinosus LWK 1	weite Resektion	75	RTx	19	LTFU
8	medulläres Ca	2011	45		Fil. Lnn	Osteolyse LWK (solitär)	Korporektomie	48		42	AWD
9	follikuläres Ca	2009	74		Fil. oss. mult.	patholog. # prox. Femur rechts	Nagel	81		14	LTFU
10	follikuläres Ca	2015	65		Fil. pulm., Fil. oss. mult.	patholog. # Femur rechts, Osteolyse Femur links	Nagel	65	RTx	16	DOD
11	papilläres Ca	1980	40	1989, 2002, 2004, 2013	Fil. Lnn, Fil. Pulm.	Osteolyse prox. Femur rechts	Nagel	77	RTx	3	DOD

Fall 1

♀ 68a,ED 1974, patholog. # Humerus rechts

Verbundosteosynthese (Nagel, Zement), FU 32 Mo, DOD

♀ 65a, ED 2015, patholog. # Femur rechts

Intramedulläre Stabilisierung (IMN)

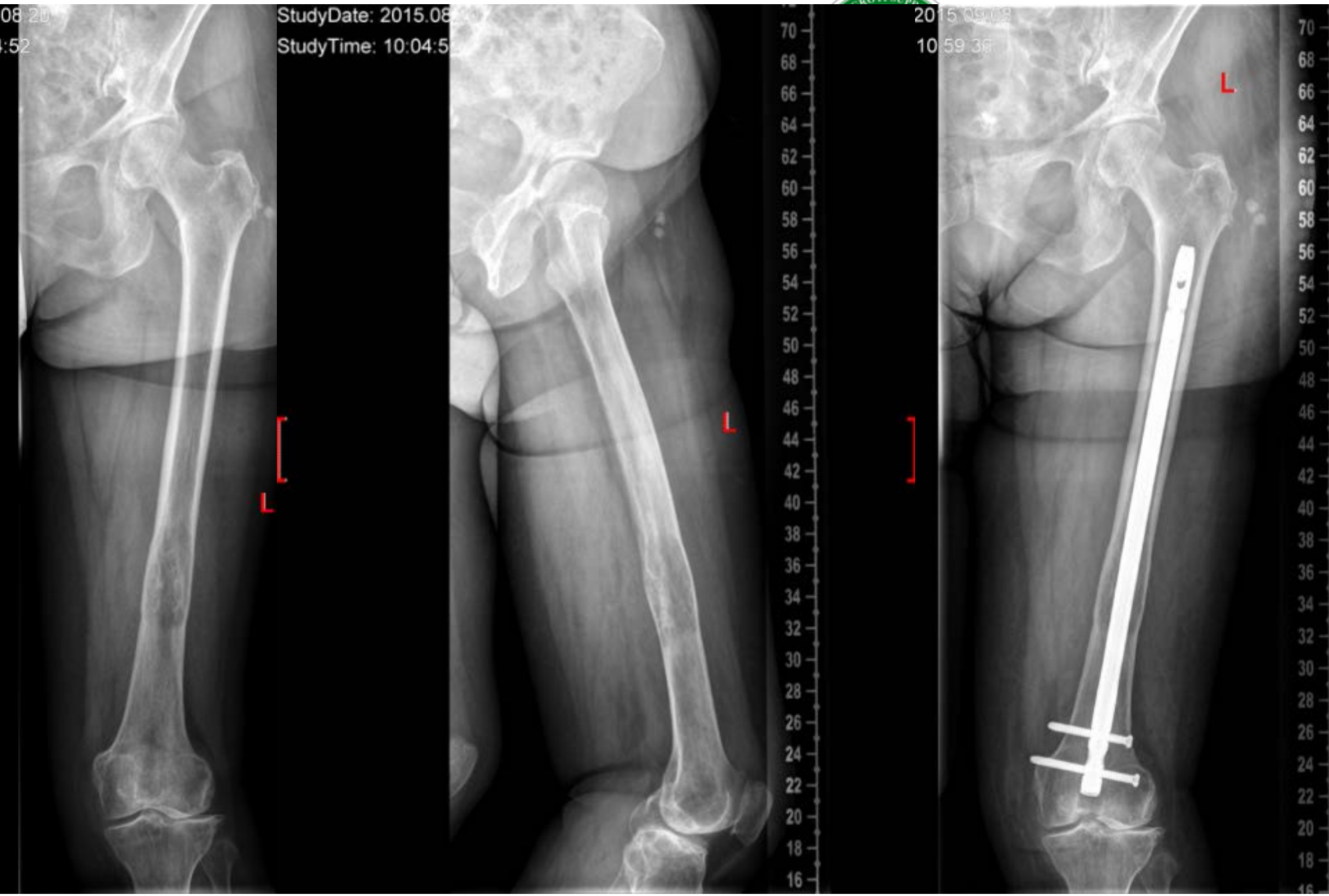

♀ 65a, frakturgefährdete Osteolyse Femur links

Intramedulläre Stabilisierung (IMN), DOD nach 16 Mo

Fall 3

Medizinische Universität Graz

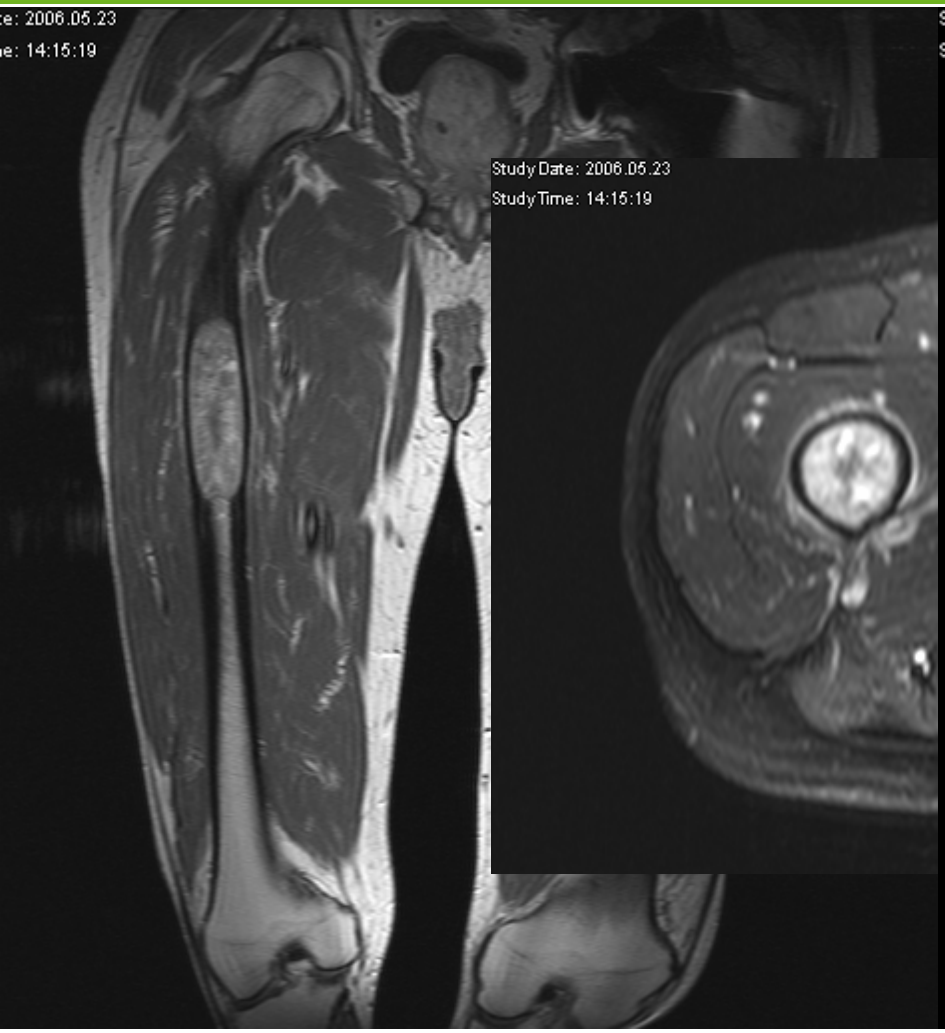

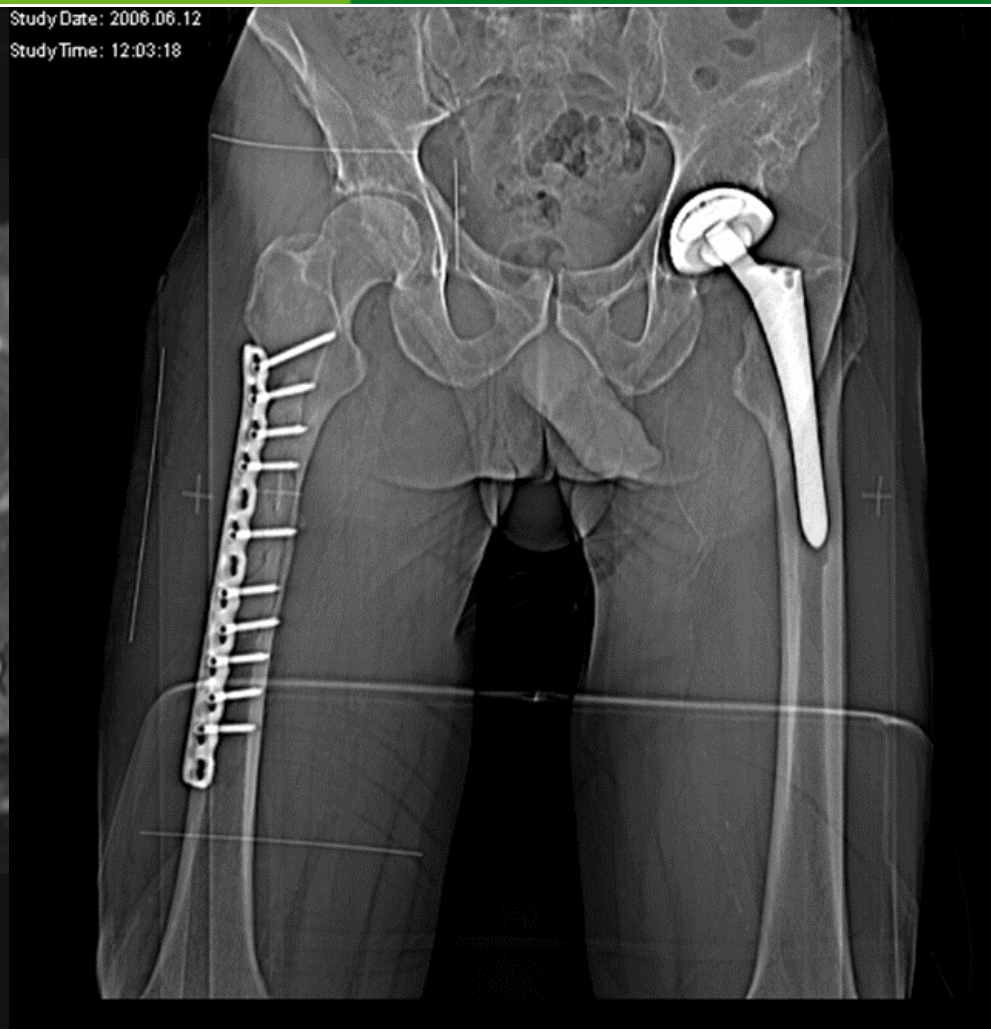

♂ 74a, ED 2004, frakturgefährdete Osteolyse Femur rechts, Verbundosteosynthese, DOD 37 Mo postop.

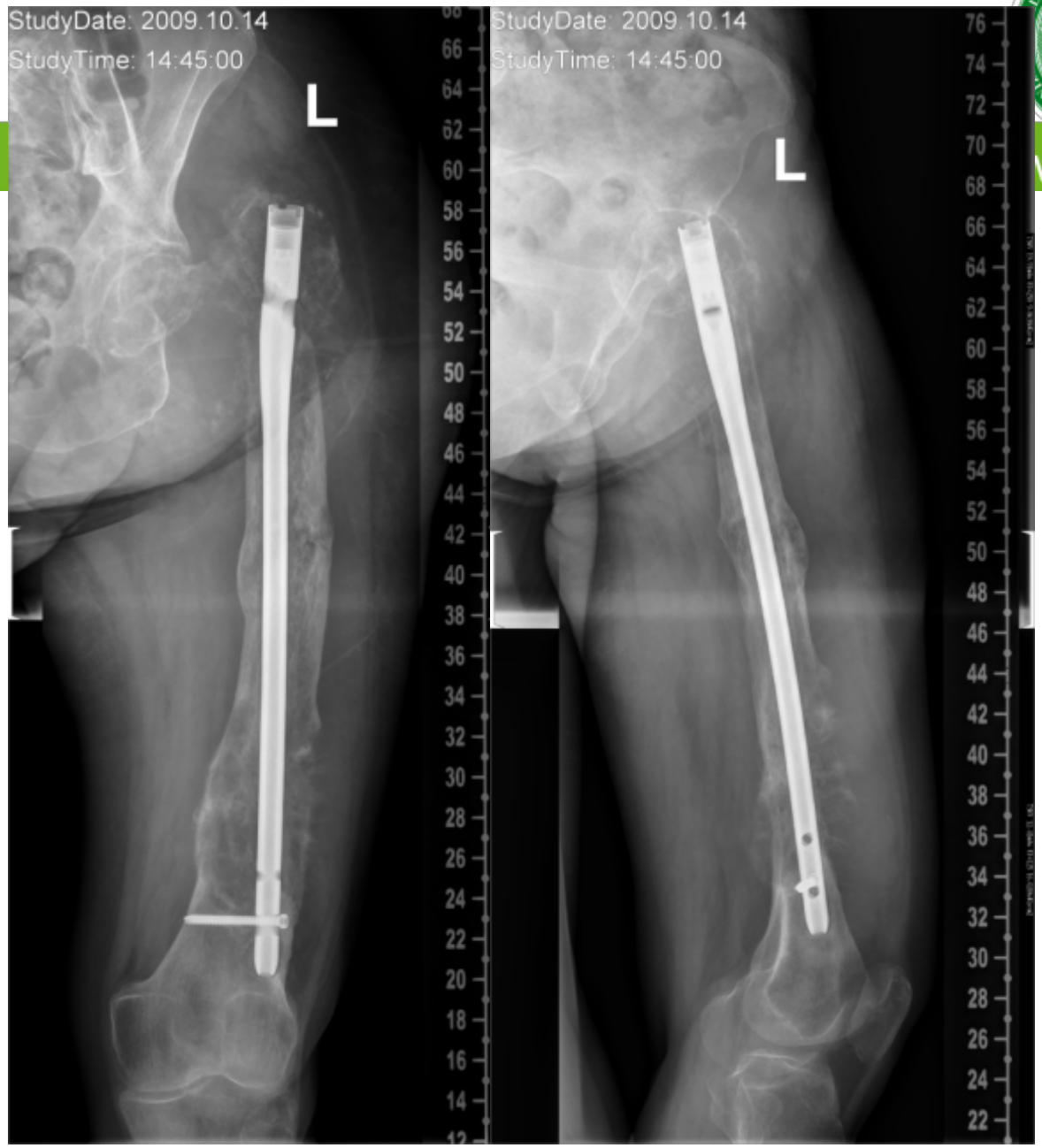

Medizinische Universität Graz

♀ 60a, sek. neoplast. Infiltration gesamtes Femur li. nach IMN 2007 bei patholog. #:

Progredienz vs. Kontamination?

MRT

Medizinische Universität Graz

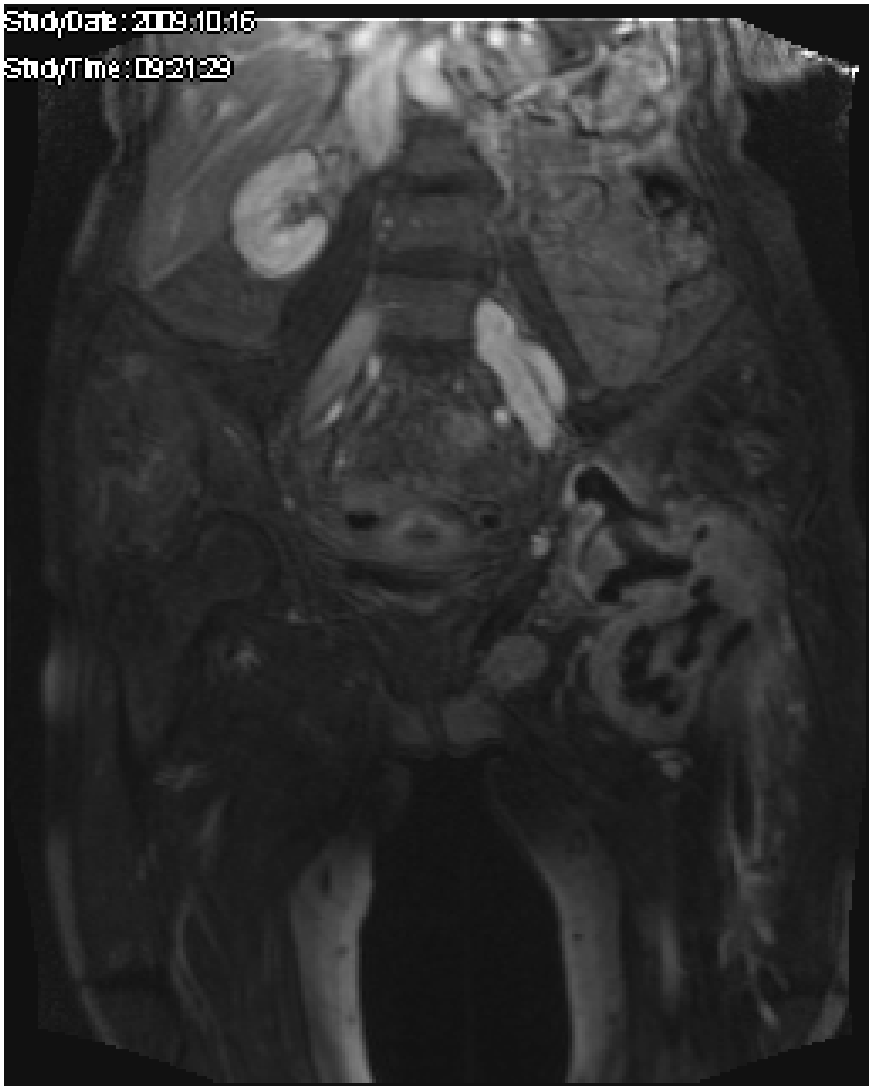

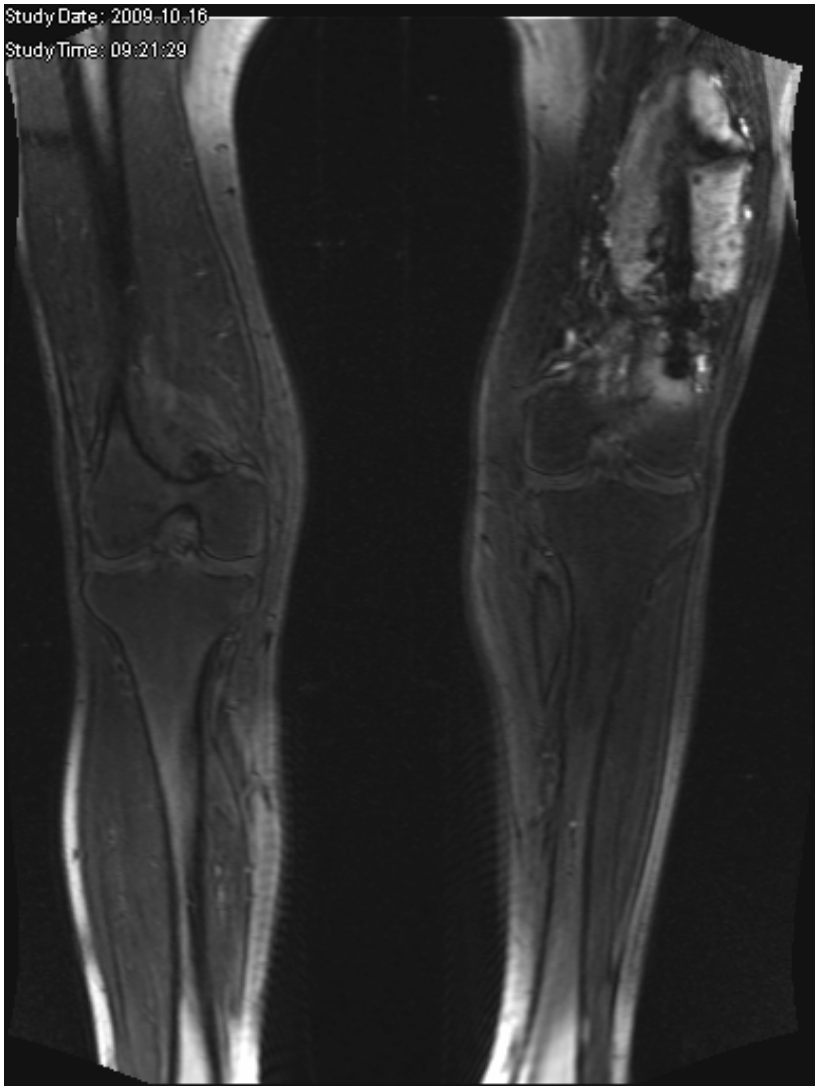

Angiographie

Medizinische Universität Graz

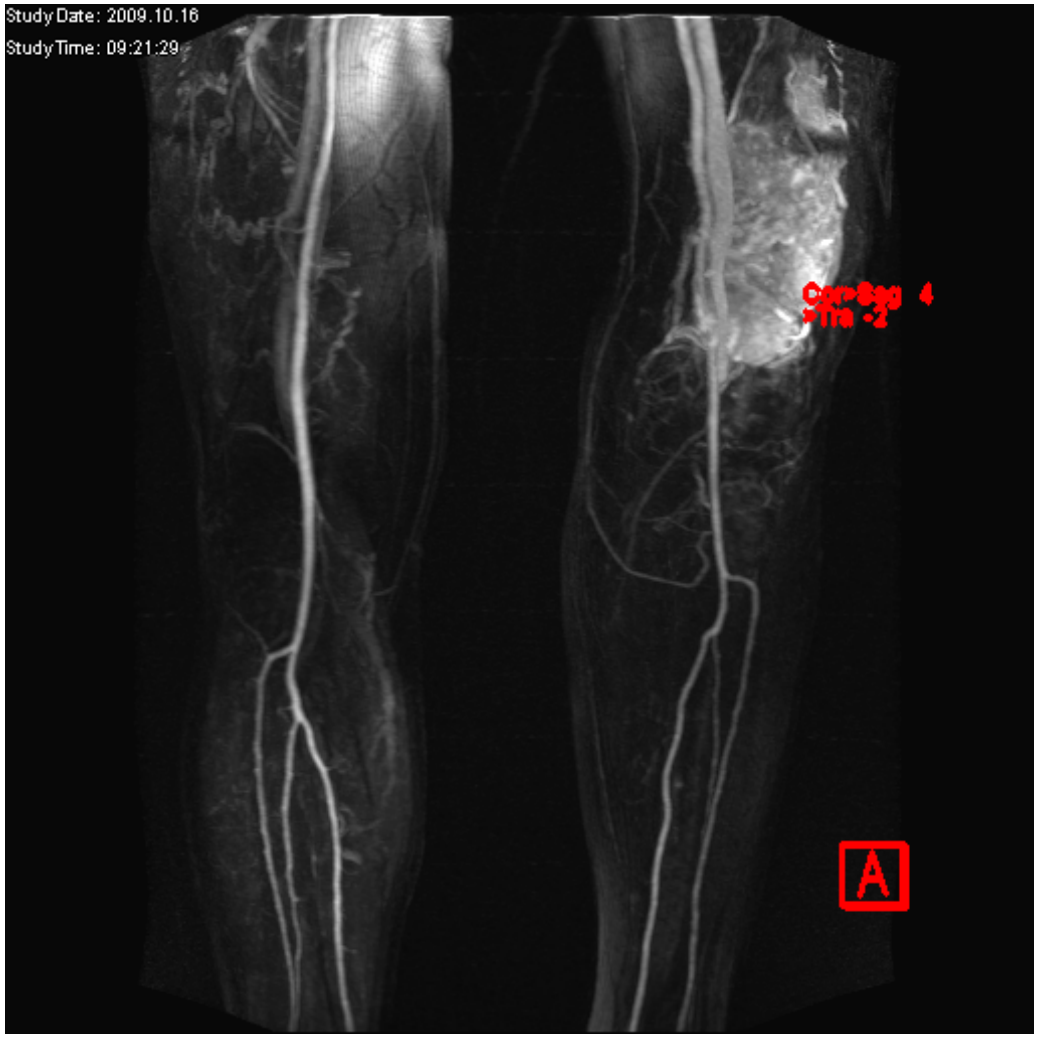

Embolisation

Medizinische Universität Graz

Postoperativ

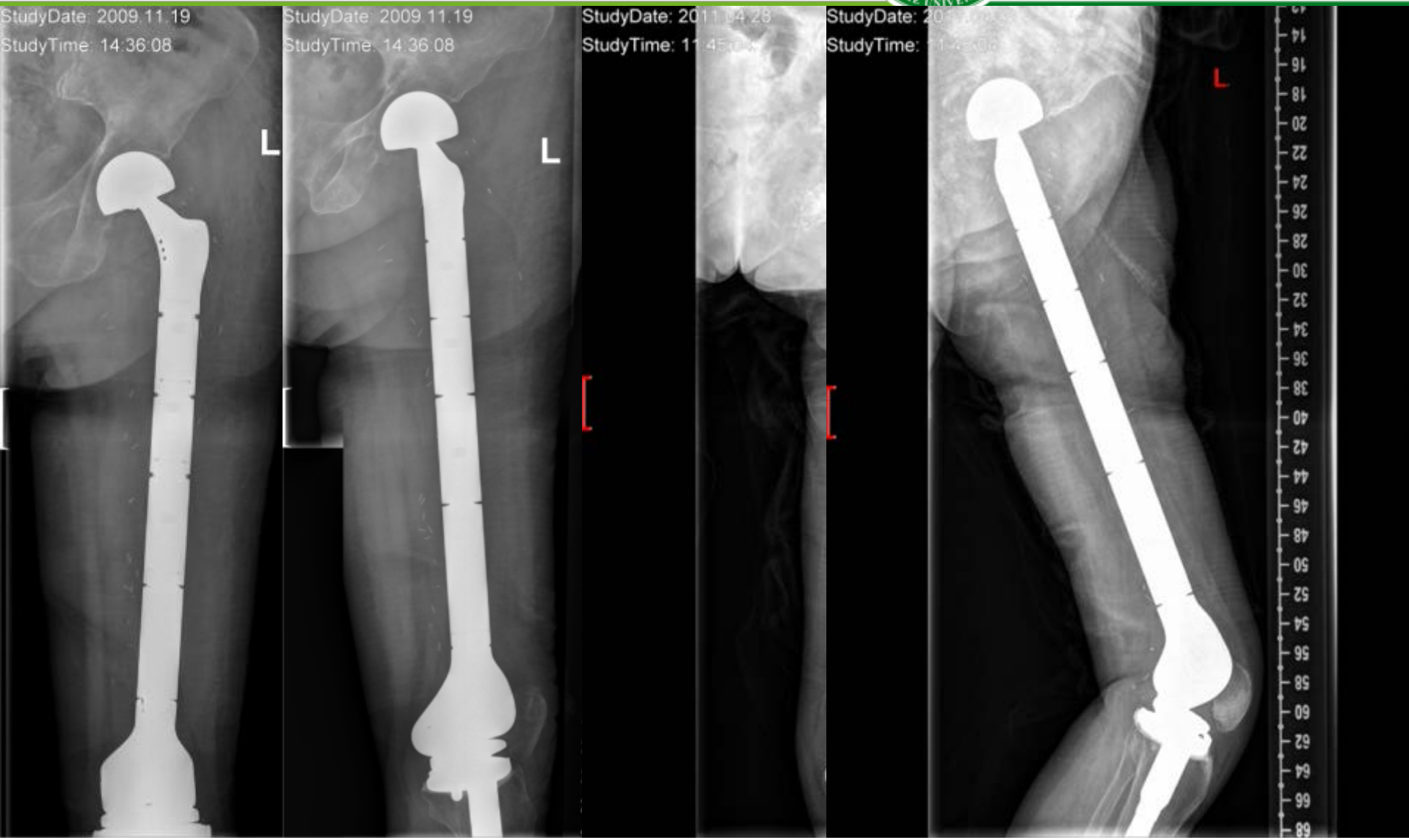

Totaler Femurersatz Tumorprothese GMRS, Befundprogredienz Becken links, DOD 29 Monate postop.

Wirbelsäule (Fall 4)

Medizinische Universität Graz

♀ 63a, ED 1998, Osteolyse BWK 6, PE + RFA 2011, AWD nach FU 74 Mo

Wirbelsäule (Fall 5)

Medizinische Universität Graz

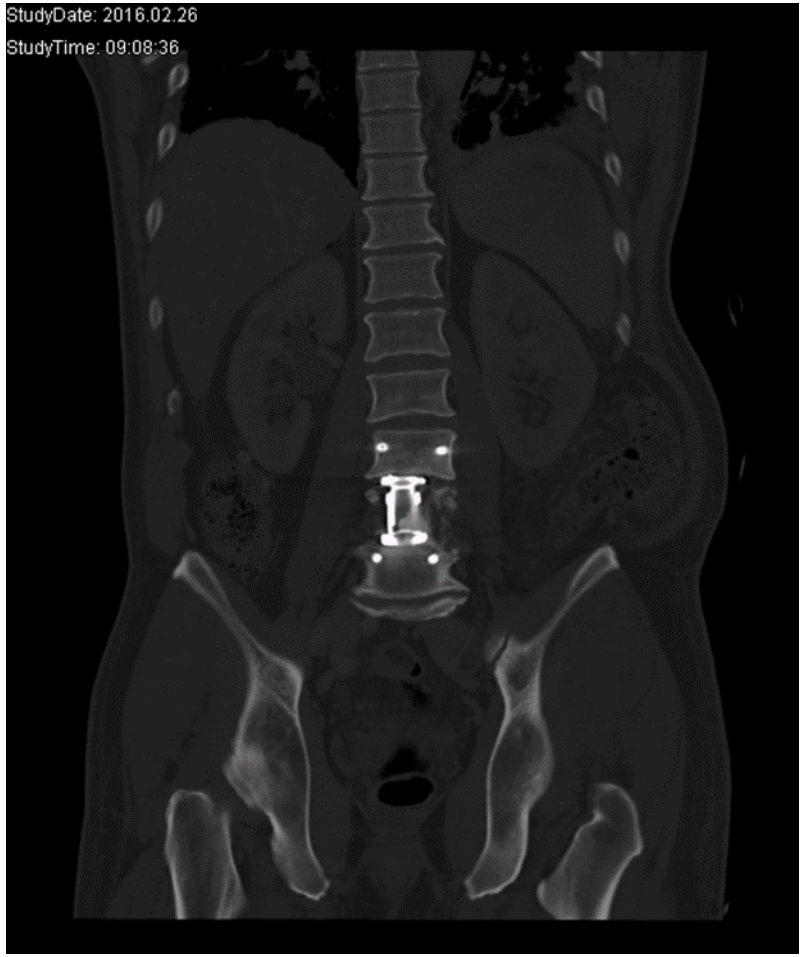

♂ 48a, ED 2011, St.p. Korporektomie L4 bei solitärer Metastase 2014, AWD 42 Mo postop.

Fall 6

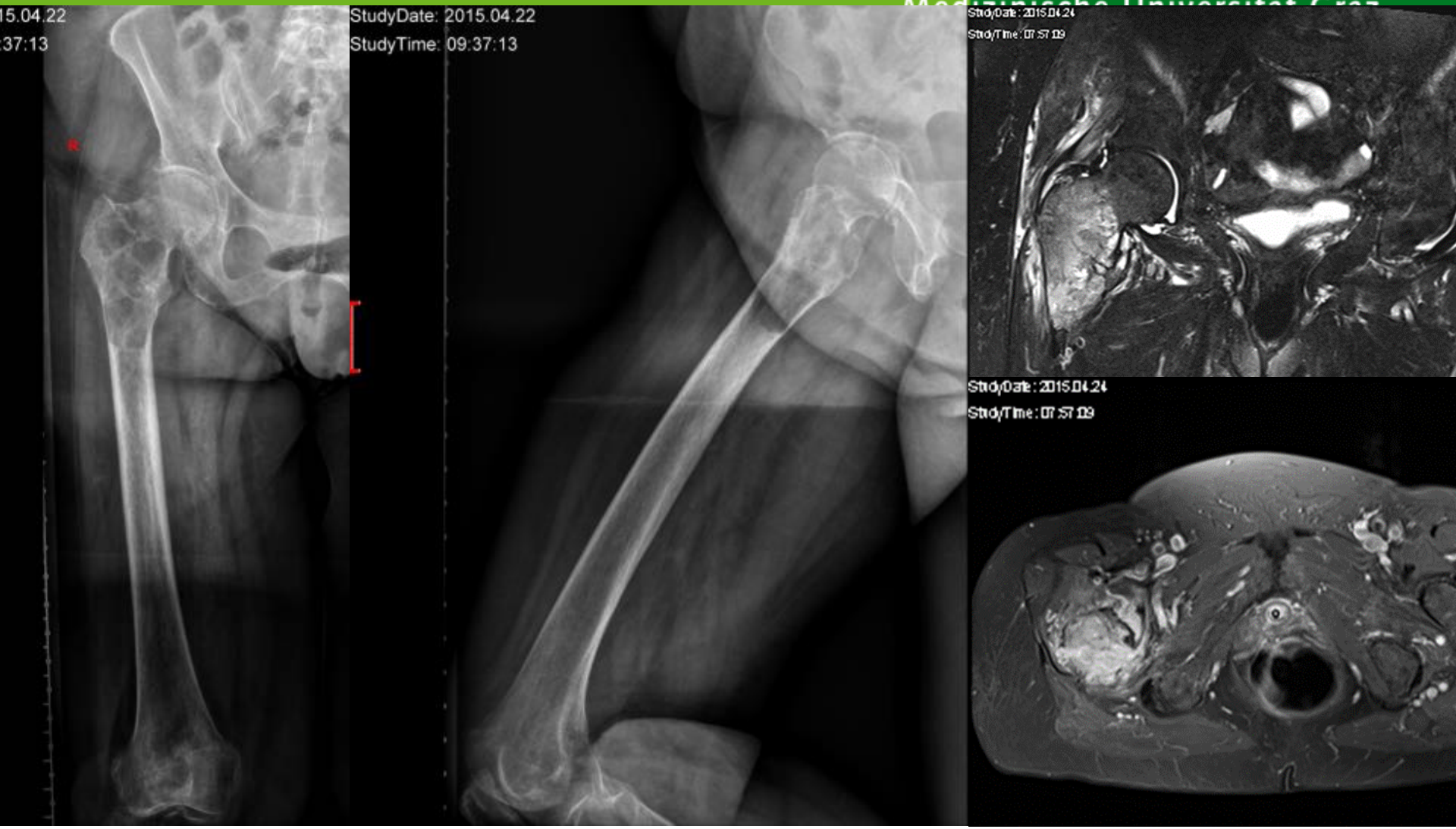

♀ 81a, ED 2009, patholog. # pertrochant. re, Primum/Chondrosarkom? Meta?

Medizinische Universität Graz

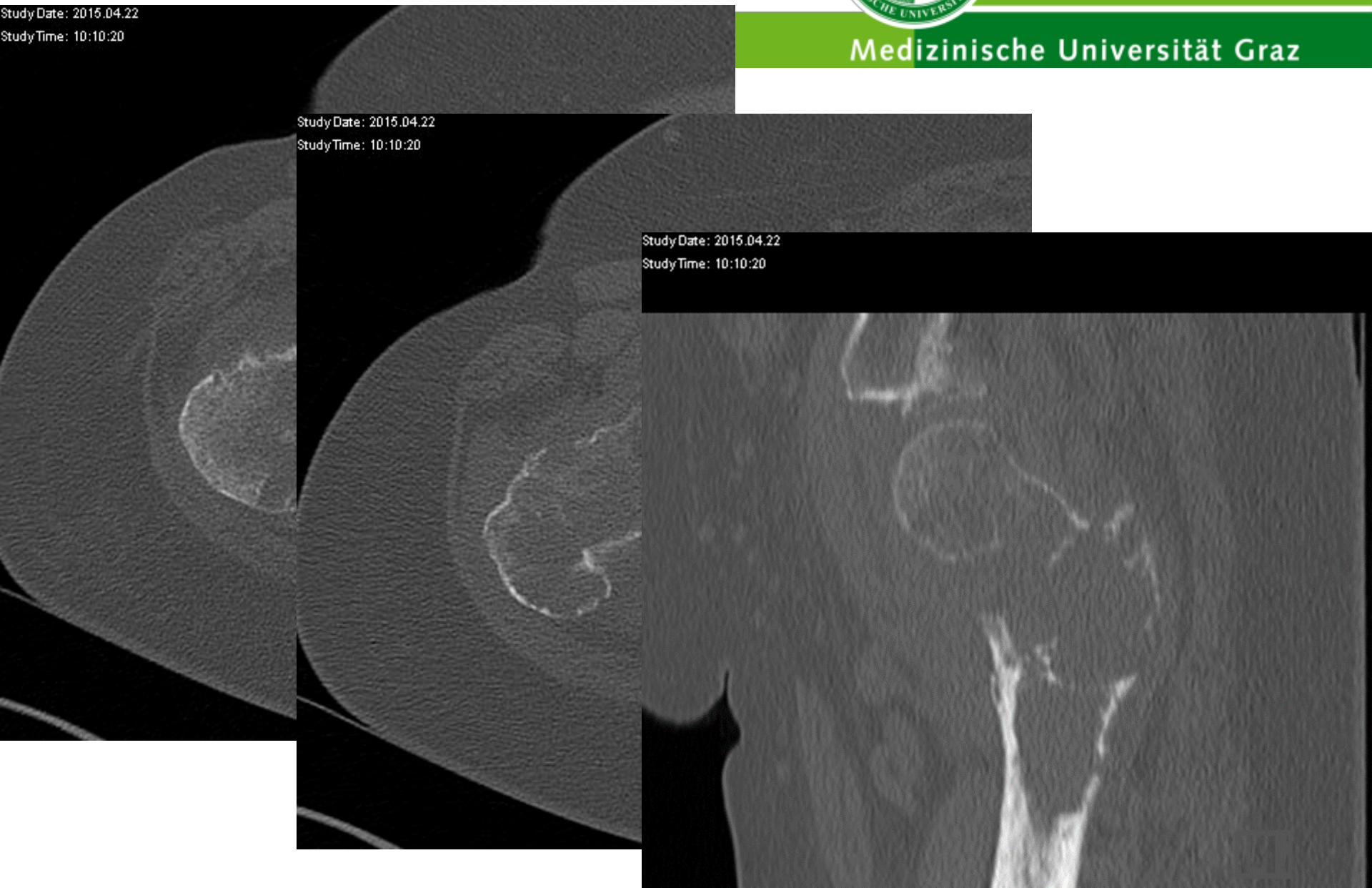

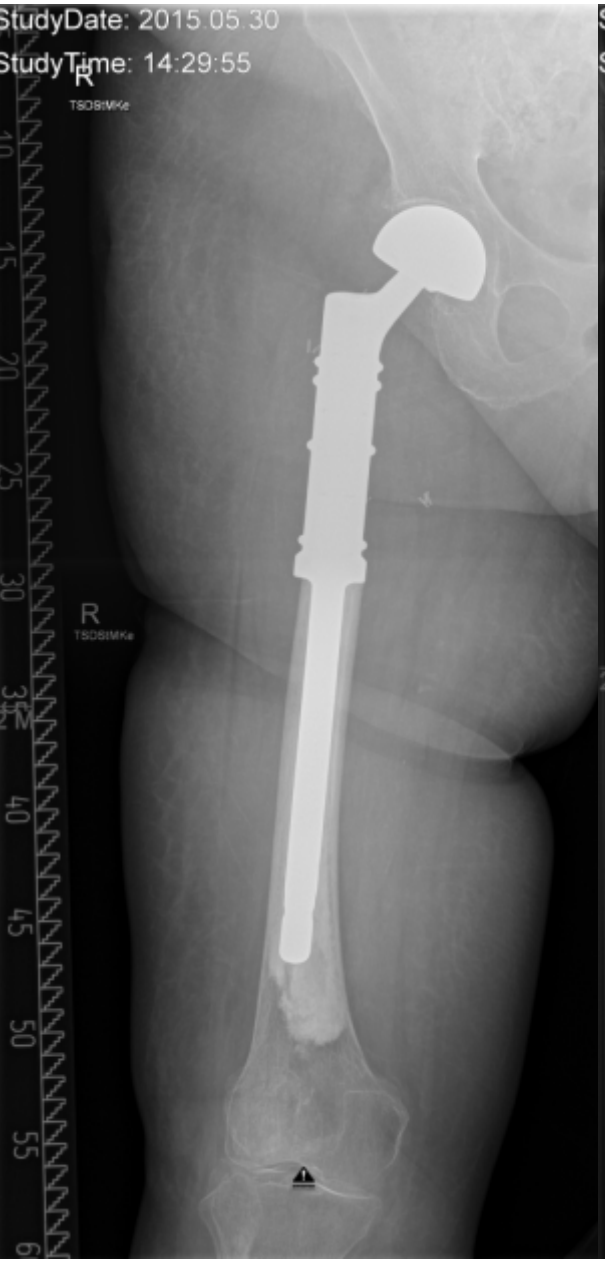



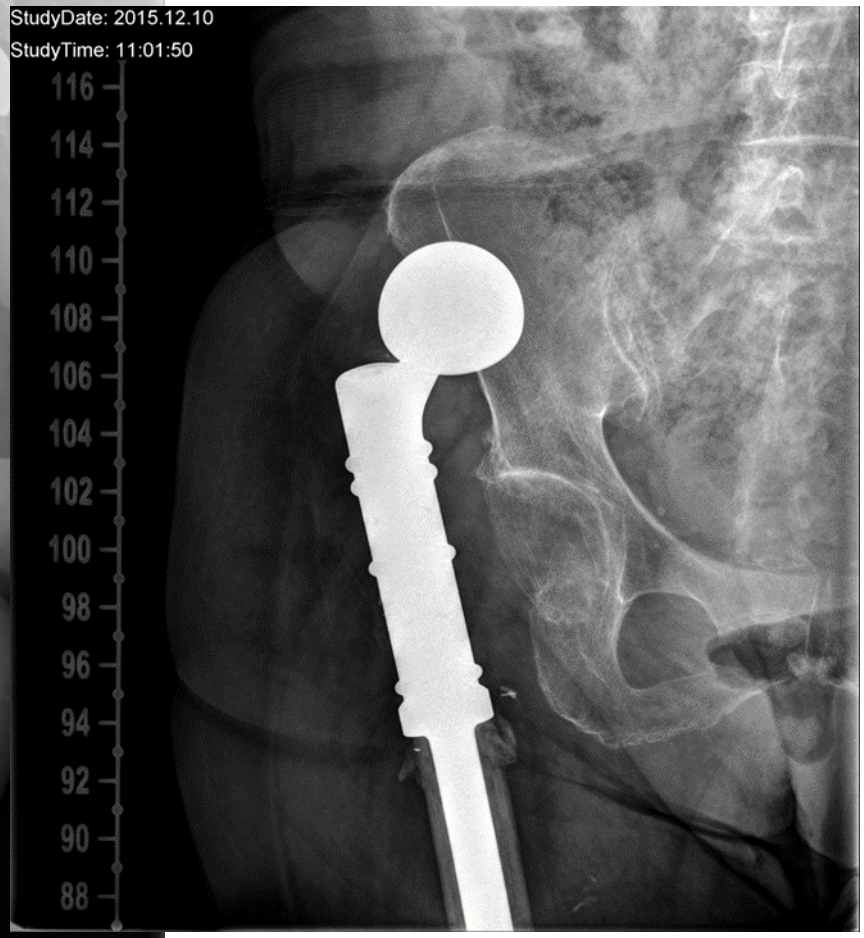

♀ 81a, PE + SS → Meta foll. SD Ca → prox. Femurersatz, Luxation 7 Mo postop., LTFU nach 14 Mo

Take Home Messages

Medizinische Universität Graz

Biopsie

- wenn unklar ob Primum oder Metastase

- multiple Absiedelungen aber Primum unbekannt

- wenn Primum >5 Jahre zurückliegt

- wenn Radiologie nicht passt – Zweittumor?

Take Home Messages

Medizinische Universität Graz

<u>Metastasenchirurgie</u>

- Individuelle, prognoseabhängige Entscheidung über OP-Ausmaß

- Lokalisation, Erfahrung & Routine des Chirurgen

- Entität: eher „aggressive“ chirurgische Therapie bei SD-Metastasen

- Weite Resektion bei singulären Metastasen

- Multidisziplinäre Therapie (prä- und postoperativ)

Interdisziplinäres Tumorboard Knochen- und Weichteiltumore

Medizinische Universität Graz

Onkologie

Strahlentherapie

- 1x wöchentlich
- Besprechung 5-15 Patienten
- Diskussion und Erstellung von Behandlungsplänen, v.a. bei seltenen Entitäten

- Orthopädie:
  - jeden Dienstag, 13.30 Uhr – ca.14.15 Uhr, Bibliothek Orthopädie

andere chirurgische und nicht-chirurgische Disziplinen

Nuklearmedizin

Medizinische Universität Graz

VIELEN DANK!