ÖGES
ÖSTERREICHISCHE GESELLSCHAFT FÜR ENDOKRINOLOGIE UND STOFFWECHSEL

ANETS AUSTRIAN NEUROENDOCRINE TUMOR SOCIETY

ÖSTERREICHISCHE SCHILDDRÜSENGESELLSCHAFT
AUSTRIAN THYROID ASSOCIATION

Neues in der histo- und zytopathologischen Klassifikation der Schilddrüsenkarzinome

Sigurd F. Lax

JOHANNES KEPLER UNIVERSITY LINZ

LKH Graz II
Akademisches Lehrkrankenhaus der Medizinischen Universität Graz

Klinische Pathologie und Molekularpathologie

KAGes

Neue Klassifikationen

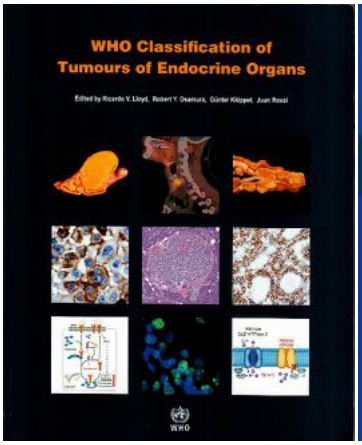

4th ed. 2016



2nd ed. 2017



8th ed. 2017

Inzidenz und Mortalität des Schilddrüsenkarzinoms: Österreich 2005-15

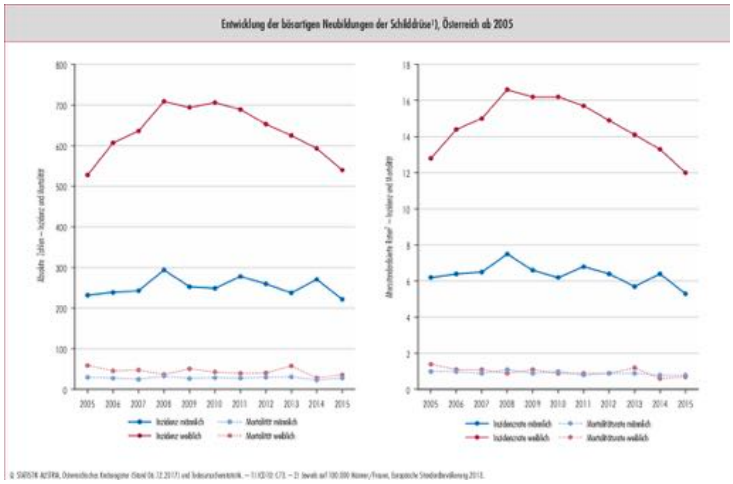

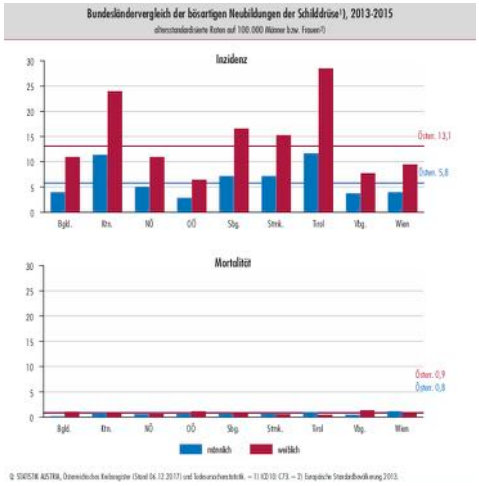

WHO 2016: Schilddrüsenkarzinome

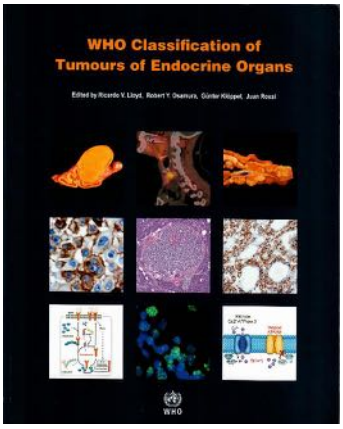

- Papillär
- Follikulär
- Hürthle cell
- Niedrig differenziert
- Undifferenziert
- Medullär
- Gemischt medullär-follikulär
- Andere: plattenepithelial, mukoepidermoid etc.

Schilddrüsenkarzinome Österreich

Typ	N (%)
Papillär	654 (79,5%)
Follikulär	71 (8,6%)
Medullär	31 (3,8%)
Anaplastisch	12 (1,5%)
Ohne Angaben	24 (3%)

Statistik Austria: 2013-5

WHO 2016: Neue Entitäten

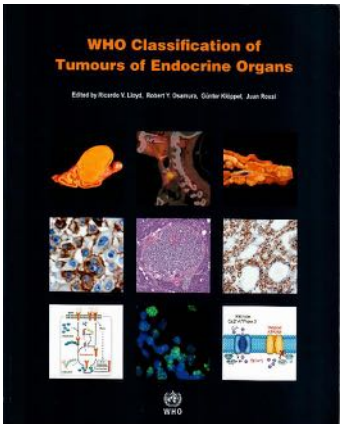

- Tumoren unsicherer maligner Potenz
- NIFT-P statt bekapselte follikuläre Variante des PTC
- Einteilung des follikulären Karzinoms
- Hürthle Zell Tumoren

Was zählt: Key Features

- Wachstum (Kapsel, Gefäße)
- Papillen
- Zellkerne

Follikuläres Adenom

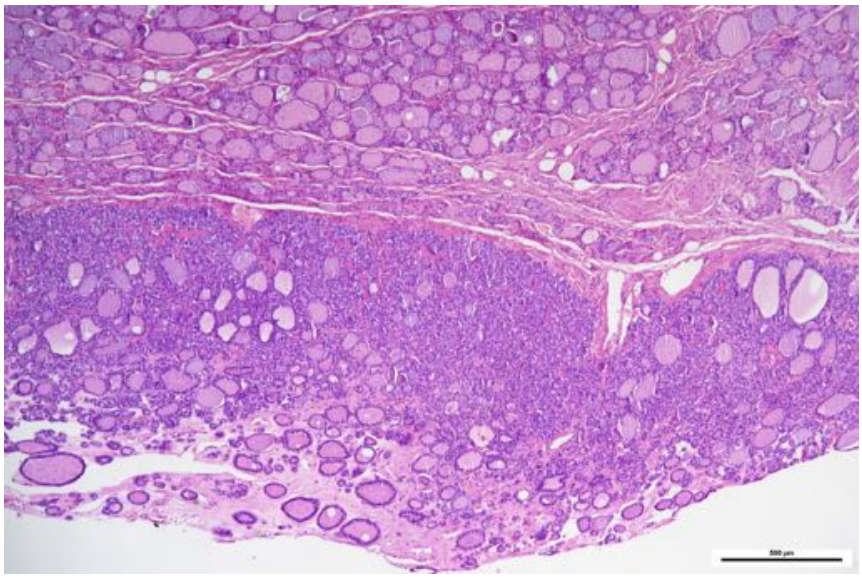

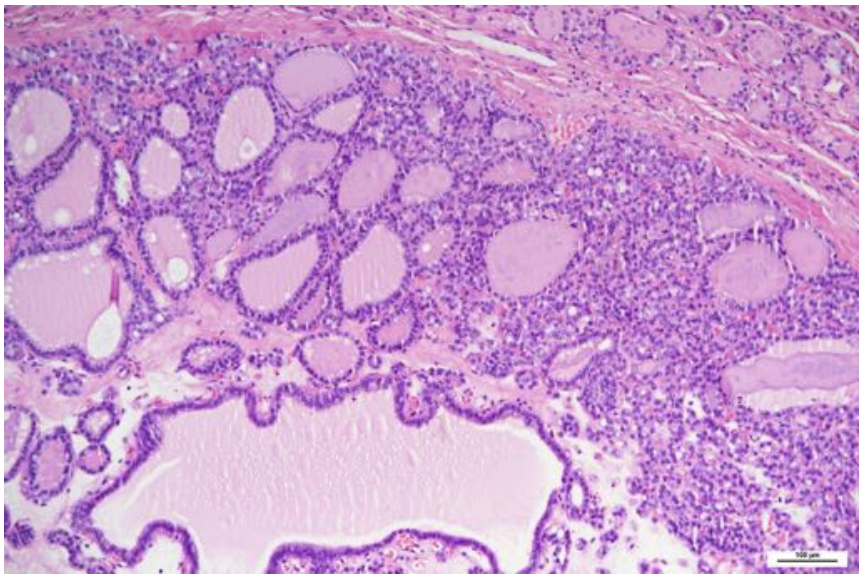

Benigne/intermediäre Tumoren

Follicular adenoma	8330/0
Hyalinizing trabecular tumour	8336/1*
Other encapsulated follicular-patterned thyroid tumours	
Follicular tumour of uncertain malignant potential	8335/1*
Well-differentiated tumour of uncertain malignant potential	8348/1*
Non-invasive follicular thyroid neoplasm with papillary-like nuclear features	8349/1*

Encapsulated follicular-patterned thyroid tumours

Table 2.02 2017 WHO classification: recommended nomenclature for encapsulated follicular-patterned tumours on the basis of the presence or absence of nuclear features of papillary thyroid carcinoma (PTC) and capsular or vascular invasion.

		Capsular or vascular invasion		
		Present	**Questionable**	**Absent**
Nuclear features of PTC	**Present**	Invasive encapsulated follicular variant of PTC	Well-differentiated tumour of uncertain malignant potential	Non-invasive follicular thyroid neoplasm with papillary-like nuclear features
	Questionable	Well-differentiated carcinoma, NOS		
	Absent	Follicular carcinoma	Follicular tumour of uncertain malignant potential	Follicular adenoma

Non-invasive follicular thyroid neoplasm with papillary-like nuclear features (NIFT-P)

- Komplett bekapselt oder scharfe Begrenzung
- Fehlen eines invasiven Wachstums
- Follikulärer Bau
- Kernveränderungen des papillären Karzinoms

- Keine oder nur abortive Papillen (urspr. <1%)
- Solides Wachstum <30%
- Mitosen <3/10HPF, keine Tumorzellnekrosen

Bekapselte follikuläre Tumoren

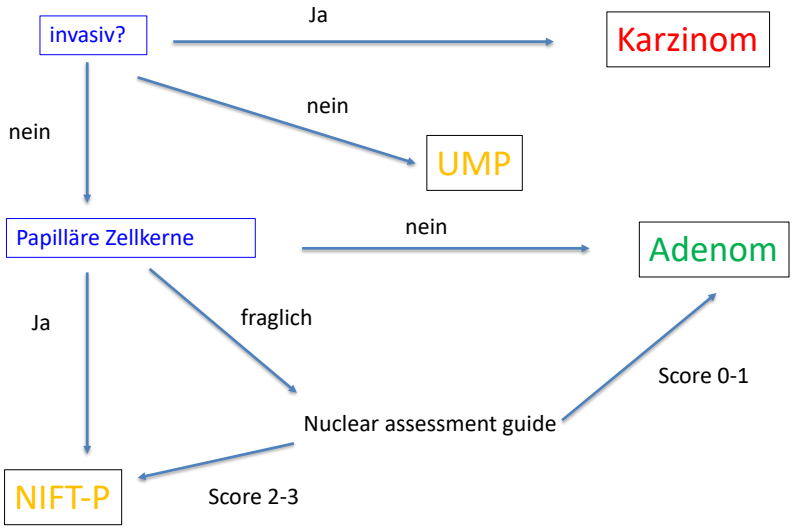

WHO Classification of endocrine tumours, 4th ed., 2017

Scoring scale for nuclear features

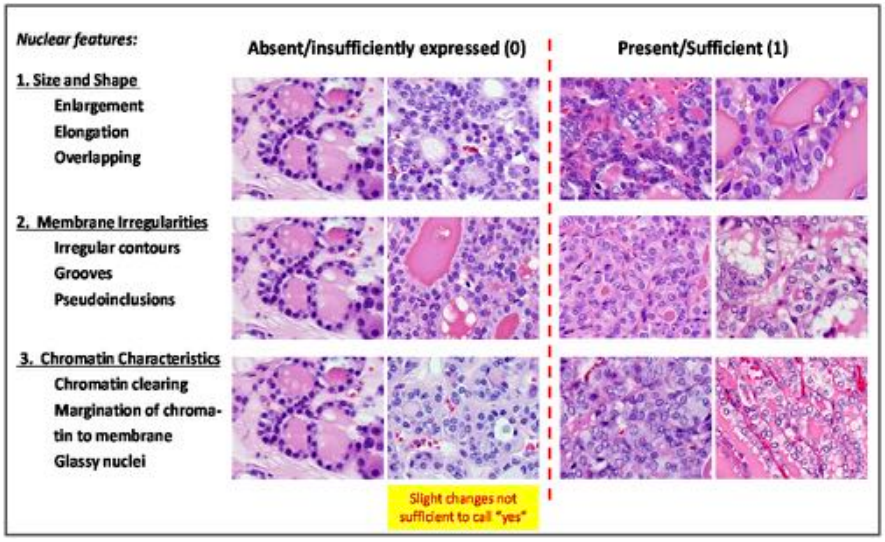

Nikiforov et al., JAMA Oncol 2016 Suppl.

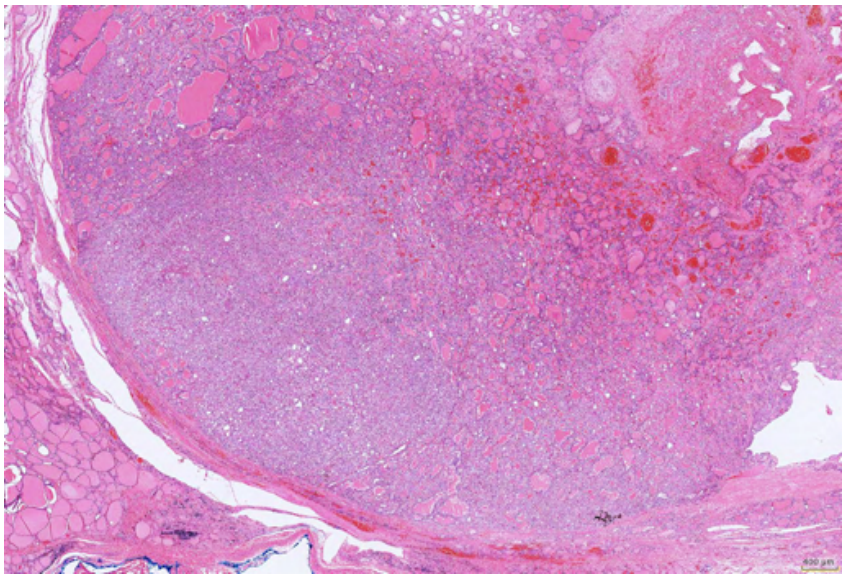

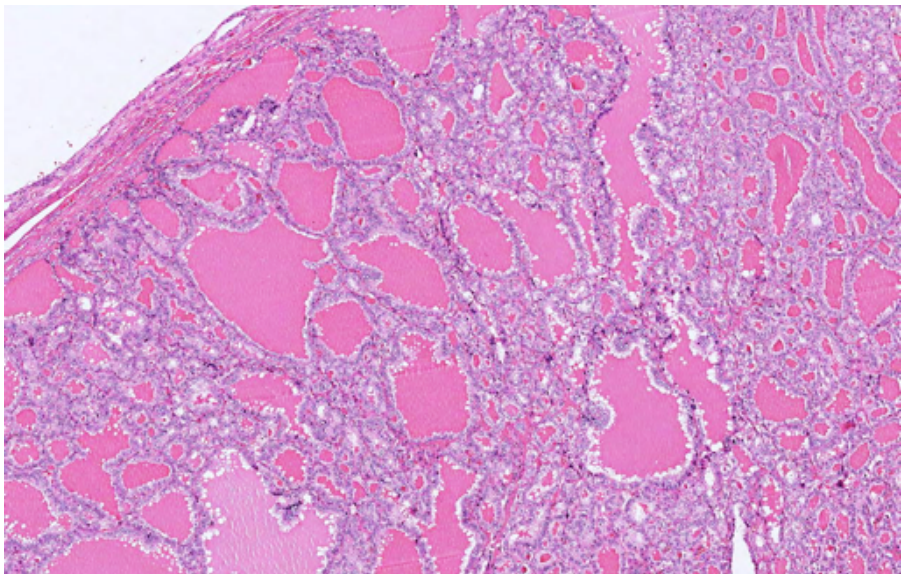

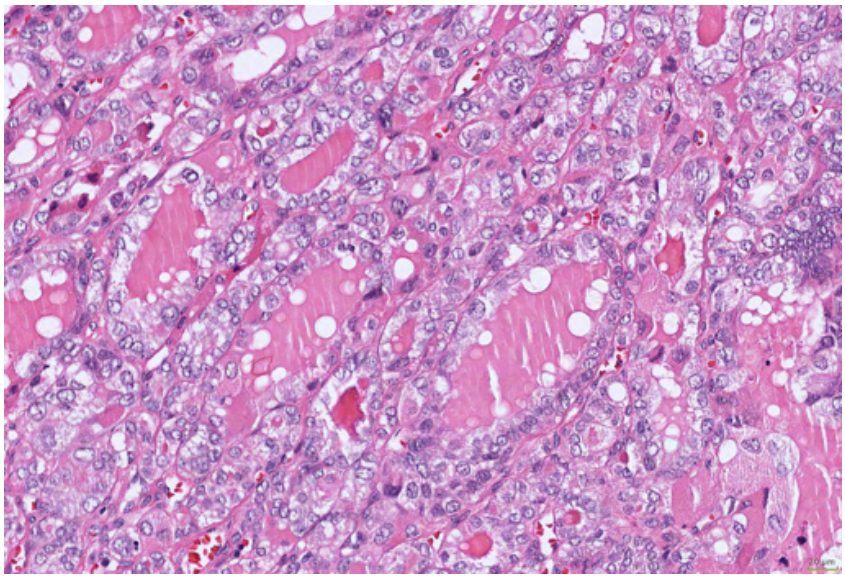

Meilenstein

JAMA Oncology | Original Investigation

Nomenclature Revision for Encapsulated Follicular Variant of Papillary Thyroid Carcinoma

A Paradigm Shift to Reduce Overtreatment of Indolent Tumors

Yuri E. Nikiforov, MD, PhD; Raja R. Seethala, MD; Giovanni Tallini, MD; Zubair W. Baloch, MD, PhD; Fulvio Basolo, MD; Lester D. R. Thompson, MD; Justine A. Barletta, MD; Bruce M. Wenig, MD; Abir Al Ghuzlan, MD; Kennichi Kakudo, MD, PhD; Thomas J. Giordano, MD, PhD; Venancio A. Alves, MD, PhD; Elham Khanafshar, MD, MS; Sylvia L. Asa, MD, PhD; Adel K. El-Naggar, MD; William E. Gooding, MS; Steven P. Hodak, MD; Ricardo V. Lloyd, MD, PhD; Guy Maytal, MD; Ozgur Mete, MD; Marina N. Nikiforova, MD; Vania Nosé, MD, PhD; Mauro Papotti, MD; David N. Poller, MB, ChB, MD, FRCPath; Peter M. Sadow, MD, PhD; Arthur S. Tischler, MD; R. Michael Tuttle, MD; Kathryn B. Wall; Virginia A. LiVolsi, MD; Gregory W. Randolph, MD; Ronald A. Ghossein, MD

JAMA Oncol. 2016;2(8):1023-1029. doi:10.1001/jamaoncol.2016.0386

Table. Summary of Follow-up Information for Patients in the Study Groups

Characteristic	Group 1 (Noninvasive EFVPTC) (n = 109)	Group 2 (Invasive EFVPTC) (n = 101)
Age, mean (range), y	45.9 (21-81)	42.8 (8-78)
Sex, No. (%)		
Female	91 (83)	71 (70)
Male	18 (17)	30 (30)
Tumor size, mean (range), cm	3.1 (1.1-9.0)	2.5 (0.6-5.5)
Extent of surgery		
Lobectomy	67	15
Total thyroidectomy	42	86
Follow-up, y		
Mean (range)	14.4 (10-26)	5.6 (1-18)
Median	13.0	3.5
Adverse events during follow-up, No. (%)	0	12 (12)

No RAI therapy

Frequency of encapsulated follicular variant of PTC

Source	Setting/ Location	Time interval	Total number of PTC	Analysis performed	FVPTC	EFVPTC	EFVPTC with no invasion
G. Tallini, *unpublished*	Bellaria Hospital, Bologna, Italy	2000-2015	523	Hospital database search	22.4%	20.7%	13.6%
M. Papotti, *unpublished*	San Luigi Hospital, Turin, Italy	2005-2014	409	Hospital database search	36%	36%	25%
F. Basolo, *unpublished*	Hospital of Pisa, Pisa, Italy	2000-2004	2197	Hospital database search	43.4%	22.7%	18.7%
R. Ghossein, *unpublished*	MSKCC, NY, USA	2000-2003	303	Pathology slide review	27.7%	23.4%	18.8%
							Mean – 18.6%

PTC, papillary thyroid carcinoma; FVPTC, follicular variant of PTC; EFVPTC, encapsulated follicular variant of PTC

Nikiforov et al., JAMA Oncol 2016 Suppl.

Invasion rather than nuclear features correlates with outcome in encapsulated follicular tumors: further evidence for the reclassification of the encapsulated papillary thyroid carcinoma follicular variant☆

Ian Ganly MD, PhD[a], Laura Wang MD[a], R. Michael Tuttle MD[b], Nora Katabi MD[c], Gustavo A. Ceballos MD[d], H. Ruben Harach MD, PhD[e], Ronald Ghossein MD[c,*]

Human Pathology (2015) 46, 657–664

- 57 non invasive, 26 invsive EFVPTC
- 9.5 years FU
- NIEFVPTC behave like adenoma
- 16% of IFVPTC poor outcome

Tumoren unsicheren malignen Potenzials: FT-UMP, WDT-UMP)

- Fragliche Invasion (Kapsel, Gefäße)
- Fragliche Kernkriterien des PTC

Papilläres Karzinom

- Typische Kernveränderungen: Milchglaskerne, Einschlüsse, Einkerbungen
- Papillen, Invasives Wachstum
- Molekular: B-RAF Mutation, RET/PTC Fusion
- Deutliche Zunahme der Inzidenz seit 1980-er (Diagnostik, Umwelt?)
- Lymphogene Metastasierung
- Auch mit Metastasen selten letaler Verlauf

Papilläres Karzinom

Papillary thyroid carcinoma (PTC)	
Papillary carcinoma	8260/3
Follicular variant of PTC	8340/3
Encapsulated variant of PTC	8343/3
Papillary microcarcinoma	8341/3
Columnar cell variant of PTC	8344/3
Oncocytic variant of PTC	8342/3

Papilläres Karzinom

Histologie

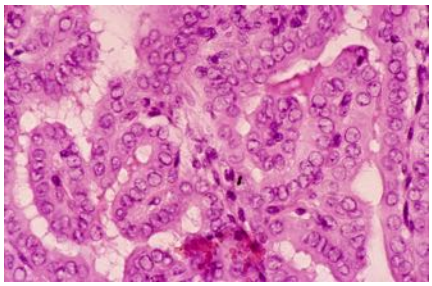

Zytologie

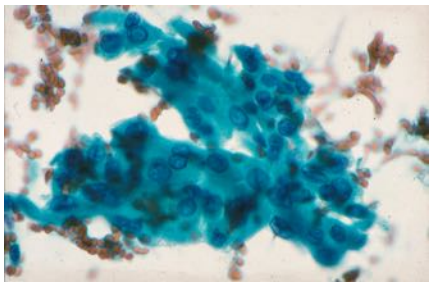

columnar cell variant

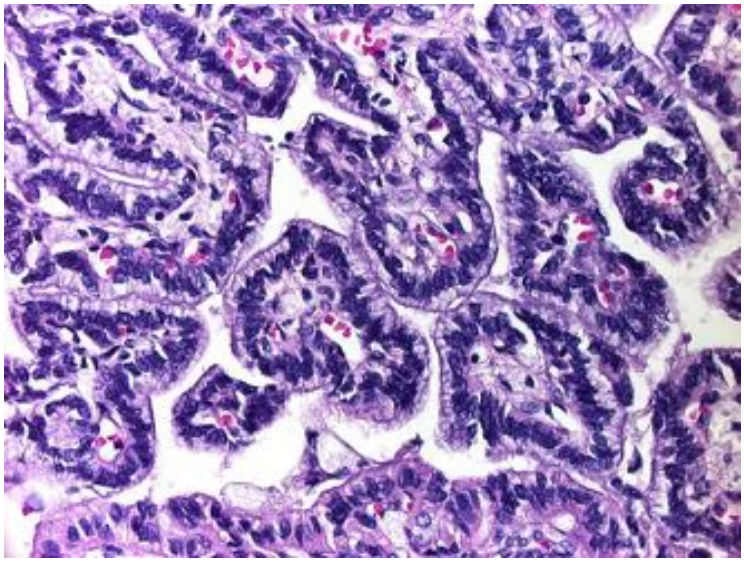

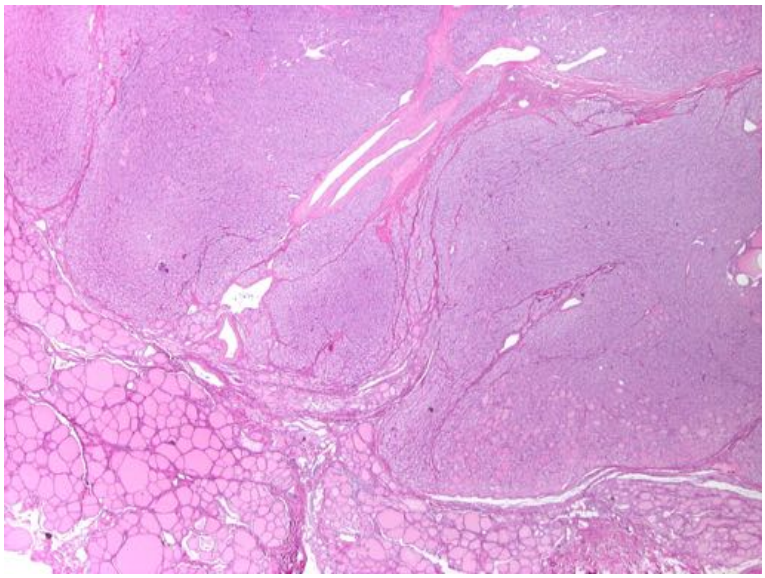

Solide Variante

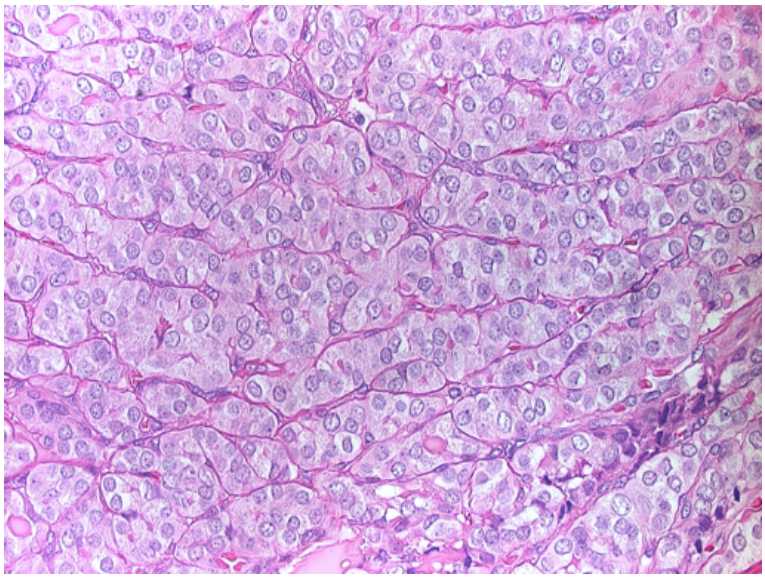

Papilläres Mikrokarzinom

- Multifokalität in 30%
- Klinische Lymphknotenmetastasen in <1%
- Rezidive in 0,05% (Neuhold et al., Ann Surg Oncol 2011)
- Kein aggressives Verhalten !
- Porto Proposal: Papillärer Mikrotumor
- Ausnahmen (ca. 1%):
  - klinische Lymphknotenmetastasen
  - Extrathyroidales Wachstum
  - Aggressive Sonderformen (tall oder columnar cell)

Zufallsbefund im Rahmen einer Strumaresektion

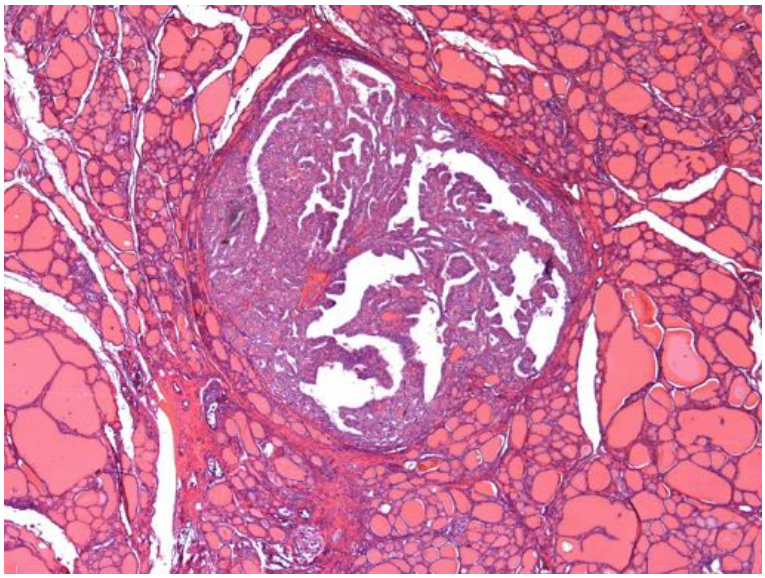

Follikuläres Karzinom und andere

Follicular thyroid carcinoma (FTC), NOS	8330/3
FTC, minimally invasive	8335/3
FTC, encapsulated angioinvasive	8339/3*
FTC, widely invasive	8330/3
Hürthle (oncocytic) cell tumours	
Hürthle cell adenoma	8290/0
Hürthle cell carcinoma	8290/3
Poorly differentiated thyroid carcinoma	8337/3

Follikuläres Schilddrüsenkarzinom

- Kernveränderungen des PTC fehlen
- Meist bekapselt
- Invasives Wachstum (Angioinvasion)
- Hämatogene Metastasierung: Knochen, Lunge
- Klassich: Keine oxiphile Differenzierung
- Molekular: RAS, PPARG Mutationen
- DD: PDTC, FA, FTUMP
- Hereditär: Cowden Syndrom, Carney Komplex

Follikuläres Schilddrüsenkarzinom

Table 2.07 Classification of follicular thyroid carcinoma

Traditional {2596}	Armed Forces Institute of Pathology (AFIP) 2014 {2340}		WHO 2017
Minimally invasive	Minimally invasive	With capsular invasion	Minimally invasive
		With limited vascular invasion (<4 vessels)	Encapsulated angioinvasive
		With extensive vascular invasion (≥4 vessels)	
Widely invasive	Widely invasive		Widely invasive

Minimal invasives follikuläres Karzinom

- 65 Fälle
- > 10 Jahre Follow up
- Trennung von Kapselinvasion und Gefäßinvasion

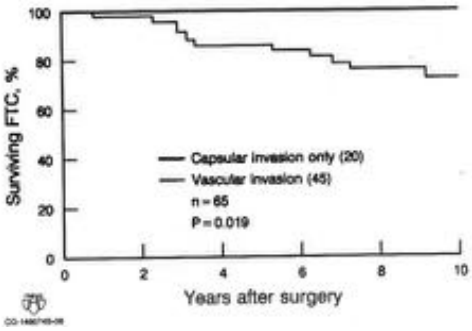

Van Heerden et al., Surgery 1992

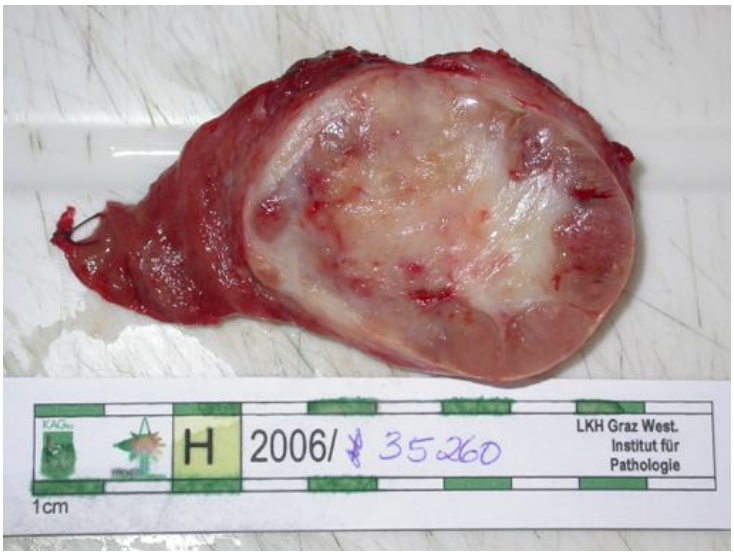

Follikuläres Karzinom:Kapsel-/Angioinvasion

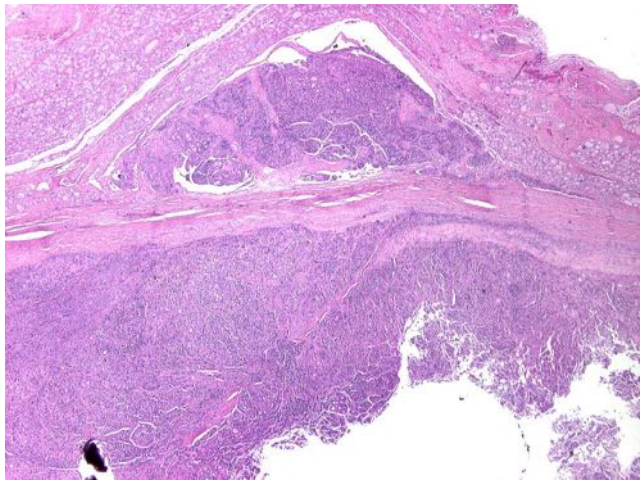

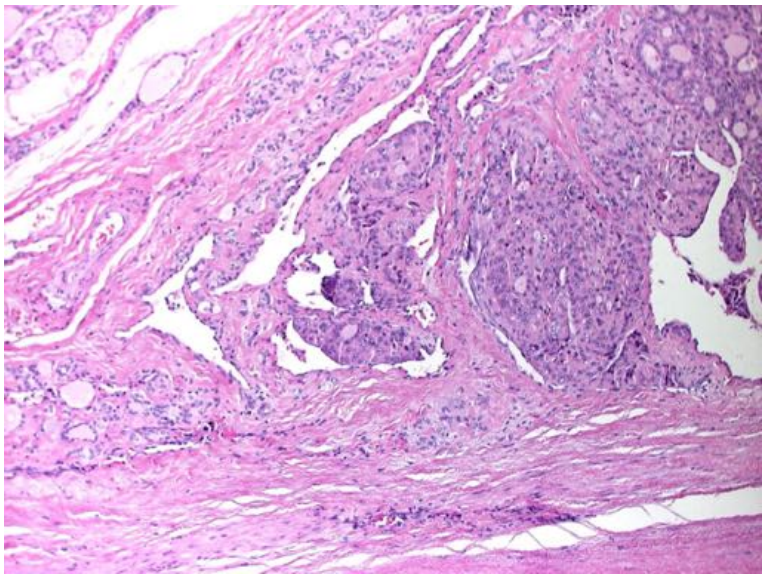

Follikuläre Neoplasie

- Zytologischer Begriff
- DD zwischen gut differenziertem follikulären Karzinom und follikulären Adenom nicht möglich

Hürthlezell (onkozytäre) Tumoren

- Eigene Kategorie (früher: follikuläre Ad/Ca)
- Pros und cons: Klinik versus molekular
- Molekular: Mutationen in Genen für Mitochondrienmembran; RAS Mut. seltener
- Adenom versus Karzinom: Invasion
- Karzinome: eher trabekulär, kleinere Zellen
- Nach FNA (onkozyt. Npl.)Totalnekrose möglich
- kleiner Teil der HCC > anaplastisches Karzinom

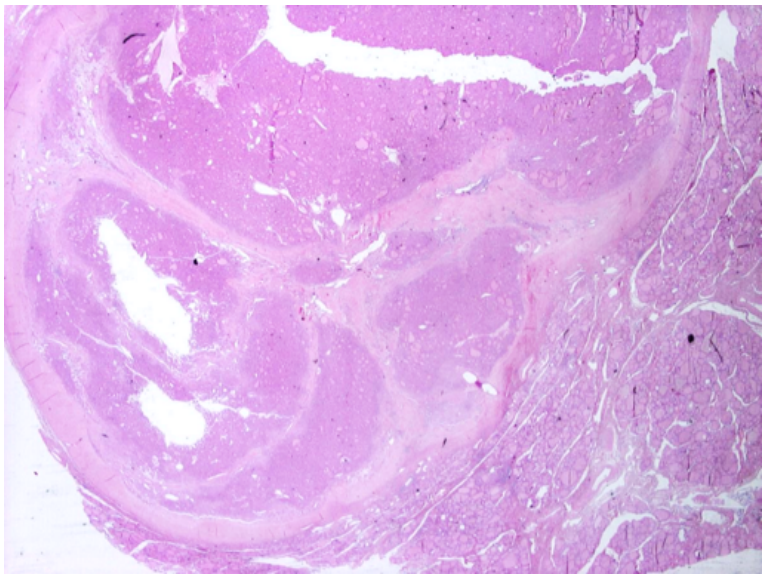

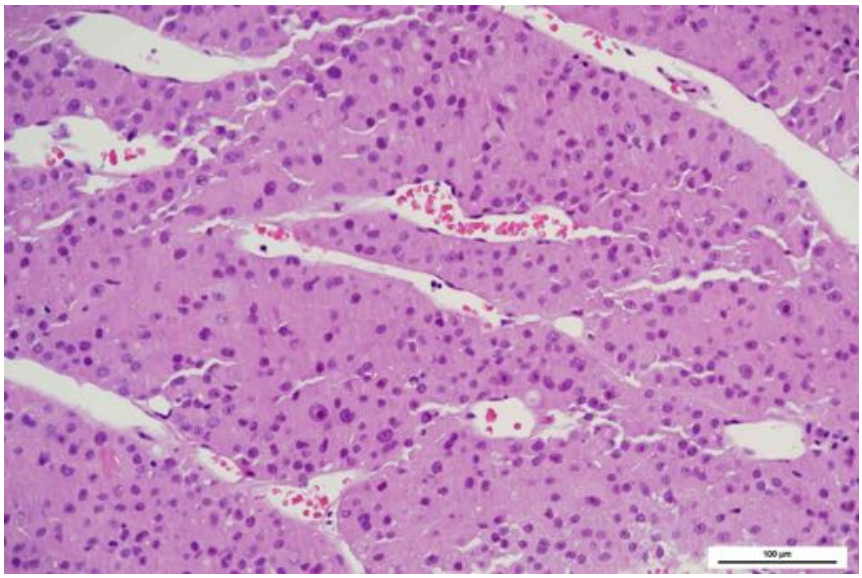
100 µm

„Hürthle Zell“ Karzinom

- 50 Fälle
- Alle enkapsuliert
- Gefäßeinbrüche signifikant für rezidivfreies Überleben
- Daneben: solider Aufbau; Mitosen; >4cm

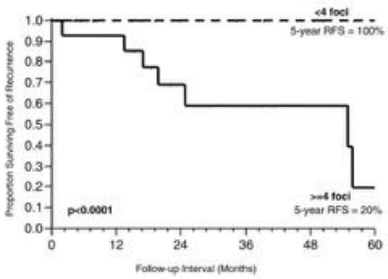

Ghossein et al., Cancer 2006

Niedrig differenziertes Karzinom

- Follikel-Bezug aber follikuläre Differenzierung eingeschränkt erkennbar
- Reste eines gut differenzierten z.T vorhanden
- Prognose zwischen papillärem/follikulärem und anaplastischem Karzinom
- Molekular: TERT, RAS, TP53, PIK3CA,BRAF Mut
- Prognostisch: mut RAS, mi-RNA150↓, IMP3, Nekrosen, Alter>45, Größe >5cm, Stadium

Überlebenskurven von Patienten mit Schilddrüsenkarzinomen mit Follikelzell-Differenzierung

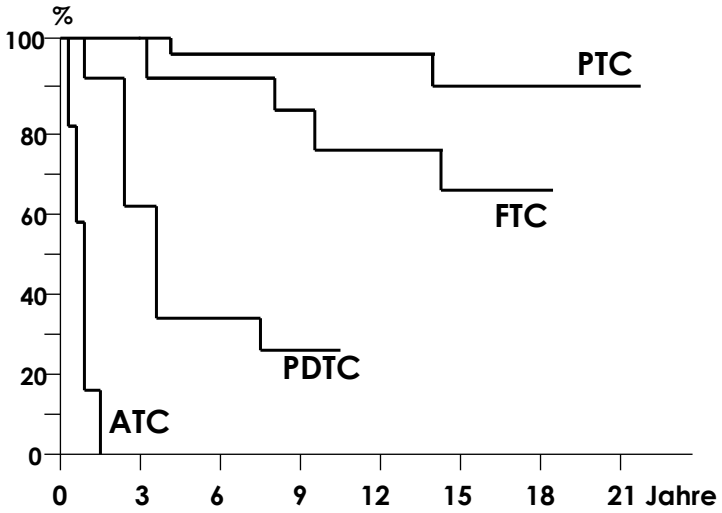

Courtesy: Prof. K.W. Schmid, Essen

Diagnose des PDTC

- Baumuster (solide, trabekulär, insulär)
- Zellkerne rosinenartig (convoluted)
- Nekrosen
- Mitosen

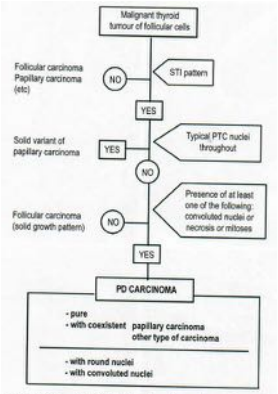

Fig. 2.63 Algorithm for the diagnosis of poorly differentiated (PD) thyroid carcinoma using the Turin consensus criteria. PTC, papillary thyroid carcinoma; STI, solid, trabecular, or insular. Reprinted from Volante M, Collini P, Nikiforov YE, et al. (2007) (2891).

Niedrig differenziertes Karzinom

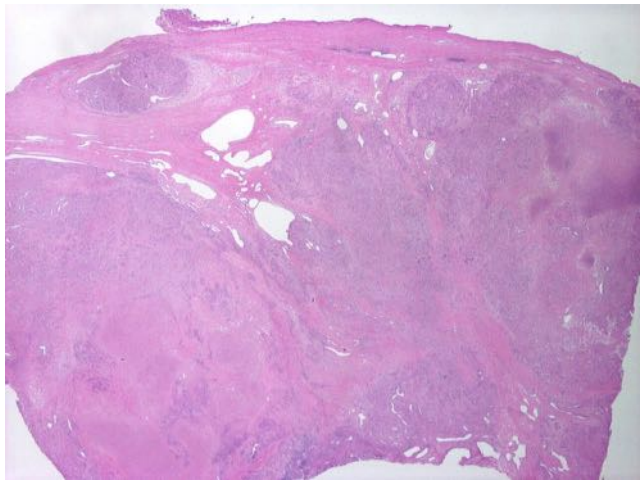

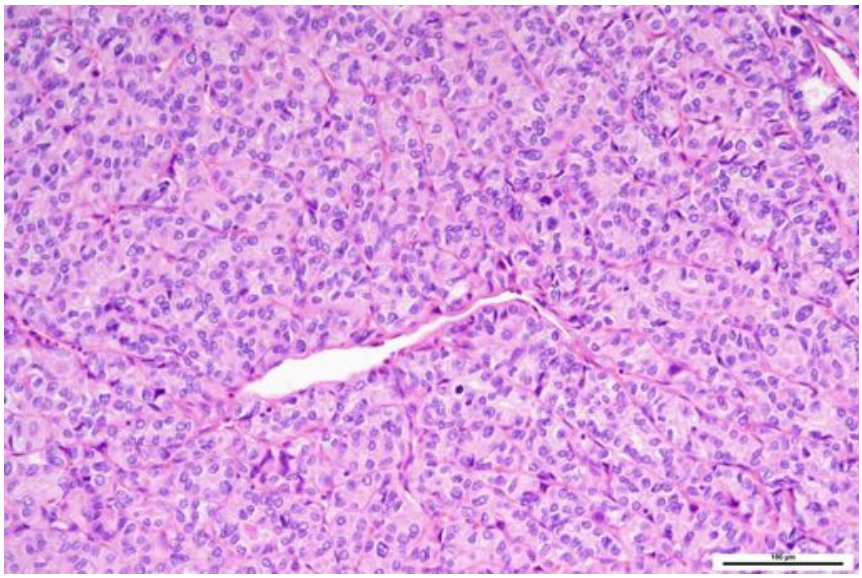

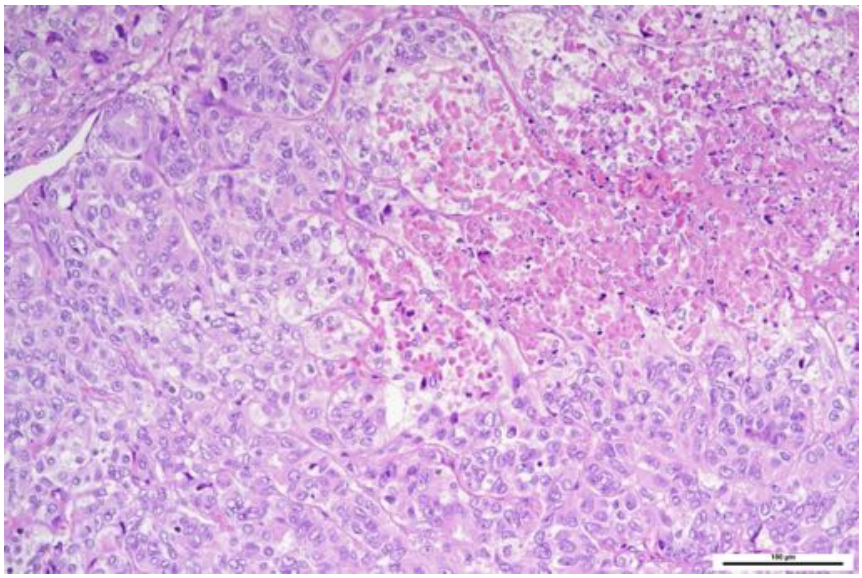

PDTC: Weitere Eigenschaften

- Positivität für P53 (fokal), Cyclin D1
- Erhöhter Ki-67 Färbeindex
- RAS, TERT Mutationen

PDTC: Prognostische Faktoren

Table 2.10 Prognostic factors independently associated with survival in poorly differentiated carcinomas by multivariate analysis.

Poor prognosis		
Clinicopathological factors – Patient age ≥ 45 years {106} – Tumour size ≥ 5 cm {997} – Macroscopically evident extrathyroidal extension (pT4a) at surgery {1205} – Distant metastases (M1) at presentation {1205}	**Histological and immunohistochemical factors** – Tumour necrosis {106} – IMP3 immunoreactivity {106} – Oncocytic features[a] {671}	**Molecular genetic factors** – RAS gene mutation {2895} – Downregulation of miR-150[b] {672}
Good prognosis		
Histological factor – Convoluted (papillary carcinoma–like) neoplastic cell nuclei {106}		

[a] This association is controversial; poorly differentiated oncocytic carcinomas were not statistically associated with poor survival in other series {106,1143}.
[b] Downregulation of miR-23b was independently associated with tumour recurrence in the same study {672}.

Diverse andere Tumoren

Anaplastic thyroid carcinoma	8020/3
Squamous cell carcinoma	8070/3
Medullary thyroid carcinoma	8345/3
Mixed medullary and follicular thyroid carcinoma	8346/3
Mucoepidermoid carcinoma	8430/3
Sclerosing mucoepidermoid carcinoma with eosinophilia	8430/3
Mucinous carcinoma	8480/3

Undifferenziertes (anaplastisches) Karzinom

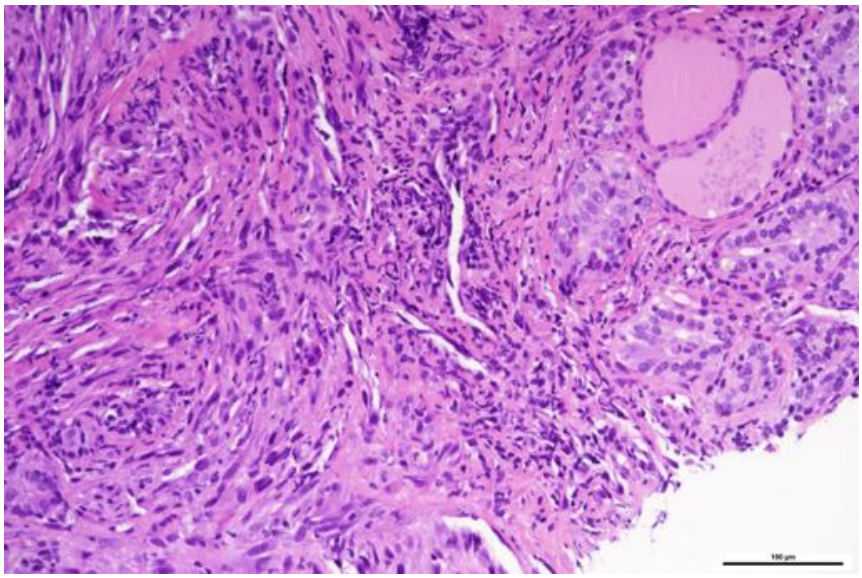

Undifferenziertes (anaplastisches) Karzinom

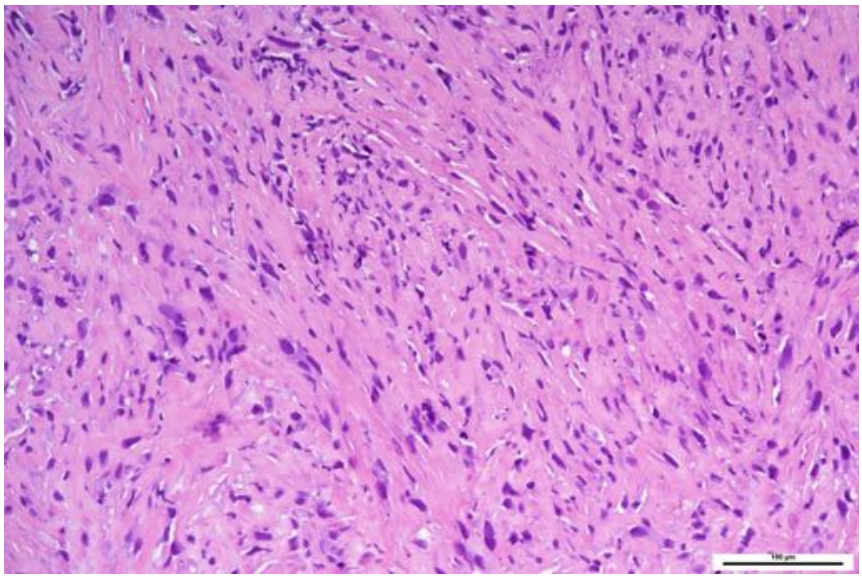

Medulläres Karzinom

- C-Zell Differenzierung: Calcitonin
- Variable Zytologie: spindelig, plasmazytoid
- Amyloid (enthält Katacalcin): „Desmoplasie“
- Ca. 70% sporadisch, 30% familiär (FMTC, MEN)
- Molekular: RET, RAS Mutationen; RET, ALK Fusionen; best. RET mut prognostisch
- Metastasen: Lymphknoten, Lunge, Knochen
- Schnellschnitt Herausforderung

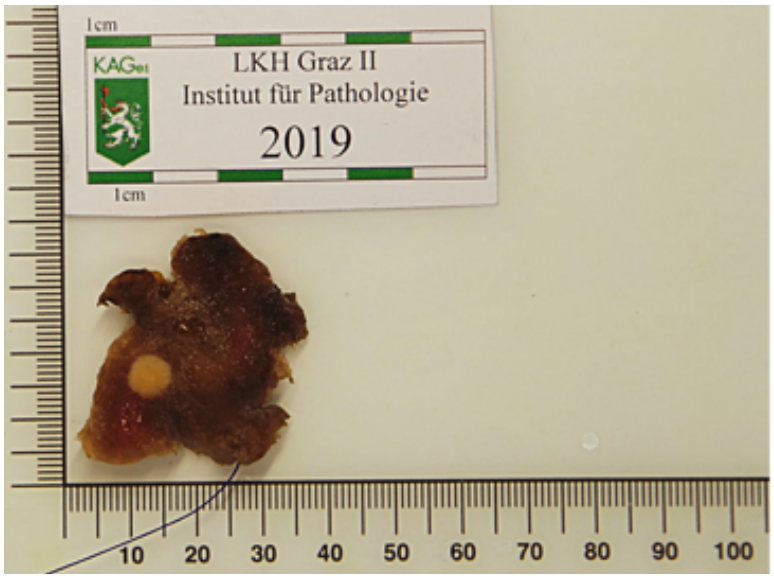

Medulläres Karzinom

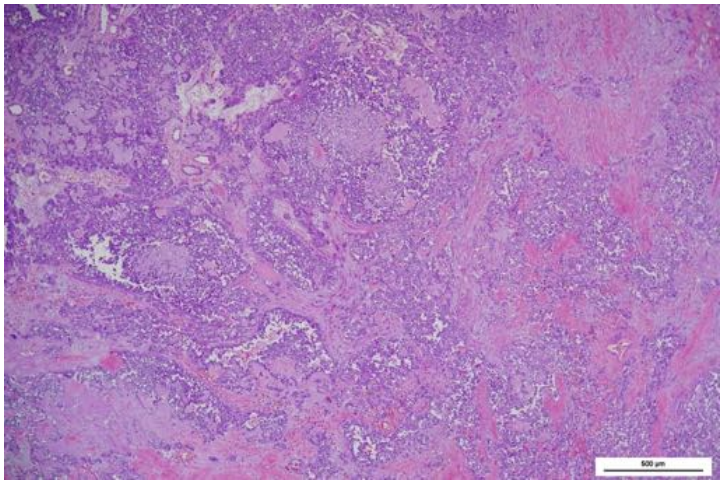

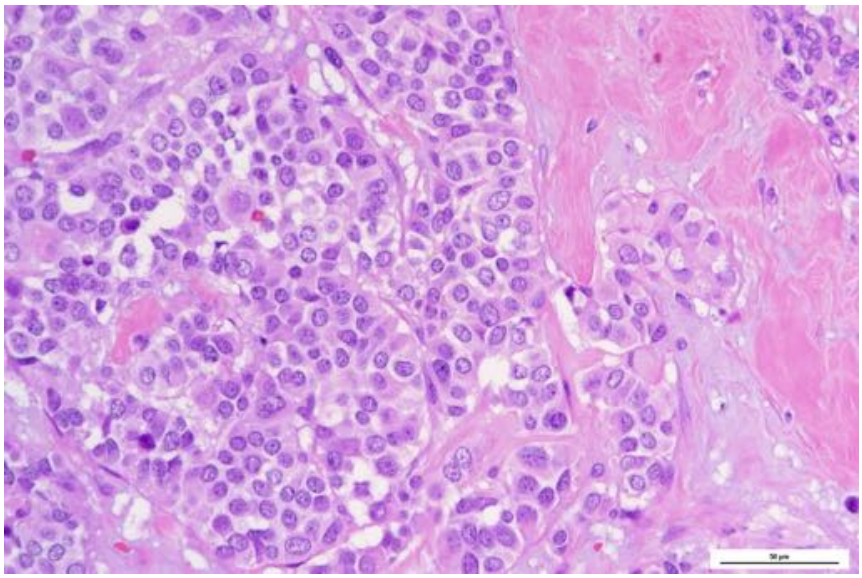

Immunhistochemie: Calcitonin

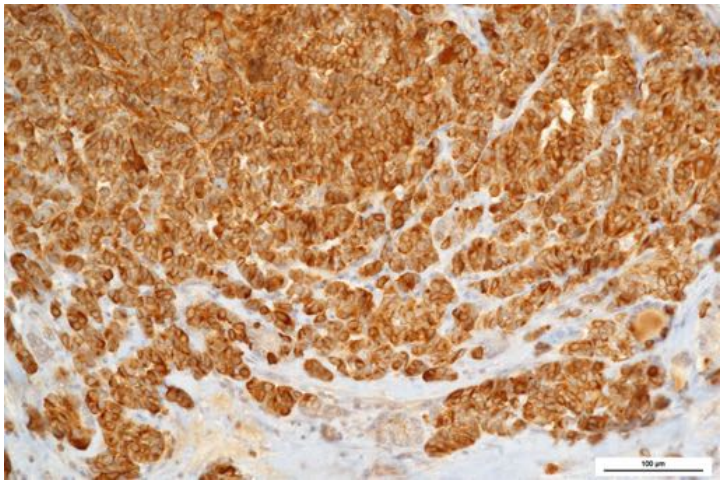

TNM

- Für Stadium Typ wesentlich: undifferenzierte Karzinome immer Stadium IV
- Papillär und follikulär: Alter </> 55

Papillary/ follicular thyroid cancer

		Stage < 55 years old	
Stage I	Any T	Any N	M0
Stage II	Any T	Any N	M1
		Stage ≥55 years old	
Stage I	T1a,T1b,T2	N0	M0
Stage II	T3	N0	M0
	T1, T2, T3	N1	M0
Stage III	T4a	Any N	M0
Stage IVA	T4b	Any N	M0
Stage IVB	Any T	Any N	M1

Thyroid Carcinoma Papillary and Follicular

The definition of T3 has been revised for papillary and follicular and medullary carcinomas

T3a Tumour more than 4 cm in greatest dimension, limited to the thyroid

T3b Tumour of any size with gross extrathyroidal extension invading only strap muscles (sternohyoid, sternothyroid, or omohyoid muscles)

T4a: Tumour beyond thyroid capsule invading, subcutis, larynx, trachea, esophagus, N. recurrens

T4b: Tumour invades prevertebral fascia, mediastinal vessels or encases carotid artery

Zytologie

- Verschiedene Systeme: Bethesda, ÖGPath/ÖGZ
- In erfahrenen Händen gute Methode zur Selektion vor der OP
- Im Rahmen einer 3-/4-DX
- Molekulare Diagnostik: hilft Malignitätsrisko einzugrenzen; bei uns noch kaum verbreitet; zentraler Test in USA

TABLE 1. THE 2017 BETHESDA SYSTEM FOR REPORTING THYROID CYTOPATHOLOGY: RECOMMENDED DIAGNOSTIC CATEGORIES

I. NONDIAGNOSTIC OR UNSATISFACTORY
- Cyst fluid only
- Virtually acellular specimen
- Other (obscuring blood, clotting artifact, etc.)

II. BENIGN
- Consistent with a benign follicular nodule (includes adenomatoid nodule, colloid nodule, etc.)
- Consistent with lymphocytic (Hashimoto) thyroiditis in the proper clinical context
- Consistent with granulomatous (subacute) thyroiditis
- Other

III. ATYPIA OF UNDETERMINED SIGNIFICANCE *or* FOLLICULAR LESION OF UNDETERMINED SIGNIFICANCE

IV. FOLLICULAR NEOPLASM *or* SUSPICIOUS FOR A FOLLICULAR NEOPLASM
- Specify if Hürthle cell (oncocytic) type

V. SUSPICIOUS FOR MALIGNANCY
- Suspicious for papillary carcinoma
- Suspicious for medullary carcinoma
- Suspicious for metastatic carcinoma
- Suspicious for lymphoma
- Other

VI. MALIGNANT
- Papillary thyroid carcinoma
- Poorly differentiated carcinoma
- Medullary thyroid carcinoma
- Undifferentiated (anaplastic) carcinoma
- Squamous-cell carcinoma
- Carcinoma with mixed features (specify)
- Metastatic carcinoma
- Non-Hodgkin lymphoma
- Other

Adapted with permision from Ali and Cibas (7).

Cytology: Terminology

ÖGZ Group		Terminology (Bethesda)	ÖGP Group	Risk of Malignancy (%)	Usual Management	Thyroid Surgery	Lymph node dissection
0	Non diagnostic	Non diagnostic or unsatisfactory	0	**	Repeat FNA with US	No	No
A	Benign	Benign	A	0-3	Clinical Follow-up	No	No
B	Indeterminate (e.g. follicular neoplasm)	AUS or FLUS	B0	5-15	Repeat FNA/ (Surgery)	No/(Hemi-thyroidectomy)	No
		Follicular neoplasm or suspicious for a follicular neoplasm (specify if Hürthle cell (oncocytic) type)	B1	15-30	Surgery	Hemi-thyroidectomy/ (Total thyroidectomy)	No
		Suspicious for malignancy	B2	60-75		Hemithyroidectomy/ (Total thyroidectomy)	Central neck dissection (unilateral)
C	Highly suspicious for malignancy/ malignant	Malignant	C	97-99		(Total thyroidectomy)	Central neck dissection (bilateral) Functional lateral neck dissection (Uni-/bilateral)

AUS/FLUS

- Seltene Diagnose
- Indikation zur Wiederholung bzw. Beobachtung
- Suspekt, aber Beurteilbarkeit für definitive Diagnose eingeschränkt

AUS/FLUS

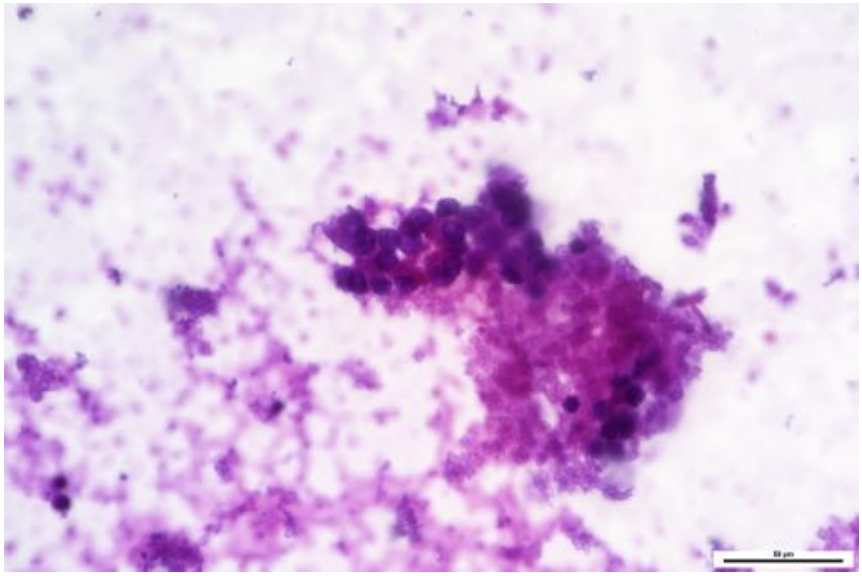

WHO 2016 und Zytologie

- Keine wesentlichen Veränderungen in Bethesda 2017
- Bethesda hat WHO 2016 zum Teil vorweggenommen
- NIFT-P hat unterschiedliche Zytologie: häufig follikuläre Neoplasie oder AUS, selten maligne
  (Singh et al., Thyroid 2017)

Zusammenfassung und Konklusion

- Neue Kategorien, Vieles bestätigt
- Neue intermediäre Kategorien und NIFT-P: therapeutische De-Eskalation
- Hürthlezell (onkozytäre) Tumoren separat ??!
- Unterteilung des follikulären Karzinoms
- Kein wesentlicher Einfluss auf Zytologie
- TNM Änderungen für foll und pap Karzinome